



## TFOS DEWS II pathophysiology report

Anthony J. Bron, FRCOph, FMedSci Co-Chair <sup>a, b, \*</sup>, Cintia S. de Paiva, MD, PhD Co-Chair <sup>c</sup>,  
 Sunil K. Chauhan, DVM, PhD Co-Chair <sup>d</sup>, Stefano Bonini, MD <sup>e</sup>, Eric E. Gabison, MD <sup>f</sup>,  
 Sandeep Jain, MD <sup>g</sup>, Erich Knop, MD, PhD <sup>h</sup>, Maria Markoulli, PhD, MOptom <sup>i</sup>,  
 Yoko Ogawa, MD <sup>j</sup>, Victor Perez, MD <sup>k</sup>, Yuichi Uchino, MD, PhD <sup>l</sup>,  
 Norihiko Yokoi, MD, PhD <sup>l</sup>, Driss Zoukhri, PhD <sup>m</sup>, David A. Sullivan, PhD <sup>d</sup>

<sup>a</sup> Nuffield Department of Clinical Neurosciences, University of Oxford, Oxford, UK

<sup>b</sup> Vision and Eye Research Unit, Anglia Ruskin University, Cambridge, UK

<sup>c</sup> Department of Ophthalmology, Baylor College of Medicine, Houston, TX, USA

<sup>d</sup> Schepens Eye Research Institute & Massachusetts Eye and Ear, Harvard Medical School, Boston, MA, USA

<sup>e</sup> Department of Ophthalmology, University Campus Biomedico, Rome, Italy

<sup>f</sup> Department of Ophthalmology, Fondation Ophtalmologique Rothschild & Hôpital Bichat Claude Bernard, Paris, France

<sup>g</sup> Department of Ophthalmology and Visual Sciences, University of Illinois at Chicago, Chicago, IL, USA

<sup>h</sup> Departments of Cell and Neurobiology and Ocular Surface Center Berlin, Charité – Universitätsmedizin Berlin, Berlin, Germany

<sup>i</sup> School of Optometry and Vision Science, University of New South Wales, Sydney, Australia

<sup>j</sup> Department of Ophthalmology, Keio University School of Medicine, Tokyo, Japan

<sup>k</sup> Department of Ophthalmology, Bascom Palmer Eye Institute, University of Miami, Miami, FL, USA

<sup>l</sup> Department of Ophthalmology, Kyoto Prefectural University of Medicine, Kyoto, Japan

<sup>m</sup> Tufts University School of Dental Medicine, Boston, MA, USA

### ARTICLE INFO

#### Article history:

Received 26 May 2017

Accepted 26 May 2017

#### Keywords:

TFOS  
 DEWS II  
 Dry eye workshop  
 Dry eye disease  
 Pathophysiology  
 Glyocalyx  
 Hyperosmolarity  
 Inflammation  
 Vicious circle

### ABSTRACT

The TFOS DEWS II Pathophysiology Subcommittee reviewed the mechanisms involved in the initiation and perpetuation of dry eye disease. Its central mechanism is evaporative water loss leading to hyperosmolar tissue damage. Research in human disease and in animal models has shown that this, either directly or by inducing inflammation, causes a loss of both epithelial and goblet cells. The consequent decrease in surface wettability leads to early tear film breakup and amplifies hyperosmolarity via the Vicious Circle. Pain in dry eye is caused by tear hyperosmolarity, loss of lubrication, inflammatory mediators and neurosensory factors, while visual symptoms arise from tear and ocular surface irregularity. Increased friction targets damage to the lids and ocular surface, resulting in characteristic punctate epithelial keratitis, superior limbic keratoconjunctivitis, filamentary keratitis, lid parallel conjunctival folds, and lid wiper epitheliopathy. Hybrid dry eye disease, with features of both aqueous deficiency and increased evaporation, is common and efforts should be made to determine the relative contribution of each form to the total picture. To this end, practical methods are needed to measure tear evaporation in the clinic, and similarly, methods are needed to measure osmolarity at the tissue level, to better determine the severity of dry eye. Areas for future research include the role of genetic mechanisms in non-Sjögren syndrome dry eye, the targeting of the terminal duct in meibomian gland disease and the influence of gaze dynamics and the closed eye state on tear stability and ocular surface inflammation.

© 2017 Elsevier Inc. All rights reserved.

## 1. Goals

To:

Summarize current understanding of tear physiology as it relates to dry eye disease (DED).

Provide an etiological classification of DED.

Identify the core mechanisms of DED, especially ocular surface hyperosmolarity, tear instability and the inflammatory response.

Consider the vicious circle of DED and chronic DED as a self-perpetuating disease.

\* Corresponding author. Nuffield Department of Clinical Neurosciences, University of Oxford, Oxford, UK.

E-mail address: [anthony.bron@eye.ox.ac.uk](mailto:anthony.bron@eye.ox.ac.uk) (A.J. Bron).

Discuss asymptomatic and symptomatic DED and the basis of DED symptoms.

Review the role of environment in precipitating DED in at-risk subjects and influencing DED severity.

## 2. Definition of dry eye disease

Dry eye is a multifactorial disease of the ocular surface characterized by a loss of homeostasis of the tear film, and accompanied by ocular symptoms, in which tear film instability and hyperosmolarity, ocular surface inflammation and damage, and neurosensory abnormalities play etiological roles (see Definition & Classification Subcommittee report).

## 3. Introduction

The purpose of this report is to review our understanding of the pathophysiology of DED, highlighting those advances that have occurred since the TFOS DEWS report [1]. Our general thesis is that DED is initiated by desiccating stress and perpetuated by a vicious circle of ocular surface inflammation.

The *raison d'être* of the eye is sight and the precorneal tear film and the cornea provide the first refractive element of the eye that focuses an image of the visual world upon the retina. To maintain optical quality, the tear film must be constantly replenished by blinking and tear secretion. Without this, the tear film would destabilise and the surface of the eye would be exposed to damaging desiccation. Various mechanisms are in place to achieve homeostasis.

## 4. Anatomy and physiology of the ocular surface and lacrimal system

### 4.1. Ocular surface

The ocular surface is covered by a continuous sheet of epithelium, lining the cornea, the anterior globe and tarsi and extending to the mucocutaneous junctions (MCJs) of the lid margins. Hydration of the ocular surface is maintained by the tears, which bathe it continuously and provide an unbroken film over its exposed surface. The tears are secreted chiefly by the lacrimal glands, with additional contributions from the conjunctiva, including the goblet cells and Meibomian glands.

The open eye is constantly subjected to desiccating stress through evaporation of the tears, but is protected from damage by homeostatic mechanisms that regulate tear secretion and distribution in response to signals from the ocular surface. In DED, a failure of these mechanisms leads to a quantitative or qualitative deficiency of tears that typically induces tear film instability, wetting defects and hyperosmolar stress, increased friction and chronic mechanical irritation at the ocular surface. This initiates a chain of inflammatory events and surface damage that characterise the disease.

### 4.2. Main and accessory lacrimal glands

The main lacrimal gland is a tubule-acinar, serous gland composed primarily of acinar, ductal, and myoepithelial cells, with the acinar cells comprising 80% of the total. It develops by a process of branching, involving reciprocal interactions between the epithelium and surrounding mesenchyme [2,3] to produce a three-dimensional tubular network [4]. In humans, the main gland consists of a larger orbital lobe, and a smaller palpebral lobe that abuts the conjunctival sac. The ducts from the orbital lobe pass through and join with, those of the palpebral gland, to open into the

superior fornix [5], via 6 to 12 orifices [6]. In addition, there are about 40 accessory glands of Krause located in the upper fornix and 6 to 8 in the lower fornix. The accessory lacrimal glands of Wolfring, located in the upper (2–5 glands) and lower (1–3 glands) lids, are slightly larger than those of Krause. The accessory lacrimal glands are tubular glands which do not contain acini in humans [7], but do in rabbits [8]. The accessory glands constitute about 10% of the total lacrimal tissue mass [9] and are innervated similarly to the main gland [10]. They are therefore assumed to respond in a similar way to reflex stimulation.

#### 4.2.1. Resident immune cells of the lacrimal gland

The lacrimal gland is richly supplied by immune cells that occupy the interstitial space. They include: plasma cells, B and T cells, dendritic cells, macrophages, bone marrow-derived monocytes, and mast cells [11], (Table 1).

*Plasma cells* predominate (53.9% of the total), mainly immunoglobulin (Ig) A+ and with a few IgG+, IgM+ or IgD+. The IgA+ cells synthesize and secrete IgA, which is transported into acinar and ductal cells, combined with J-piece and secretory component (SC) and secreted as dimeric, secretory IgA (sIgA) [12,13]. A similar event may occur in the conjunctiva and in other Eye-Associated Lymphoid Tissues (EALT) [14].

*T cells* are the next most common cell, (40.3% of total), dispersed with plasma cells in the interstitium, in follicles and aggregates and occasionally between acinar cells. T cell aggregates are typically related to intra-lobular ducts. Overall, T suppressor/cytotoxic cells (T8) are more numerous than T helper cells (T4), distributed almost equally between acini, ducts and interstitium. The T4/T8 ratio is 0.26 in the interstitium. However, T4 cells predominate in follicles and lymphocytic aggregates. Dendritic cells, macrophages, bone marrow-derived monocytes and mast cells are also present.

*B-cells* are found exclusively in the centre of primary follicles and aggregates and in solitary, secondary follicles, surrounded by T helper cells and a lesser number of suppressor/cytotoxic cells. They are not found in the interstitium. They make up 5.7% of the mononuclear population. B-cells and the dendritic cells of follicles and aggregates express HLA-DR as do duct lining cells and the vascular endothelium. Macrophages and dendritic cells are uncommon.

#### 4.2.2. Regulation of lacrimal secretion

The acinar cells are arranged in lobules around a central lumen, with tight junctions surrounding each cell on the apical (luminal) side [12,15]. This configuration permits the unidirectional, basal-to-apical, secretion of water, electrolytes, proteins and mucins [12,15]. The basal portion of the cell contains a large nucleus, rough endoplasmic reticulum, mitochondria, and Golgi apparatus while the apical portion is filled with secretory granules [12,15]. The acinar cells synthesize, store, and secrete proteins and mucins in response to neural and hormonal stimuli [13,15]. They also secrete electrolytes and water. Many of the proteins secreted have either growth factor or bactericidal properties, which are crucial to the health of the ocular surface. Several mucins, both secreted as well as membrane-bound have been detected in the lacrimal gland including MUC1, MUC4, MUC5B, MUC5Ac, MUC6, MUC7 and MUC16 [16–18]. Some of them perform local roles but otherwise their functions are not known.

Like the acinar cells, the duct cells are polarized by apically located tight junctions [12]. Importantly, the ductal cells modify the primary fluid secreted by the acinar cells by absorbing or secreting water and electrolytes [19,20]. The duct cells secrete a KCl-rich solution so that the finally secreted lacrimal gland fluid is rich in K<sup>+</sup> ions. It has been estimated that as much as 30% of the volume of the final lacrimal gland fluid is secreted by the duct cells [19,20].

**Table 1**  
Resident immune cells of the normal human lacrimal gland.

Tissue Layer	Plasma Cells	T Cells	T cell Phenotype	B-Cells	Macs	DCs	pDCs
Acinar	53.9%	40.3%	Generally, suppressor/cytotoxic	5.7%	0.01%	5.6%	+
Ductal			T cells dominate				+
Interstitial	++++						+
Follicles & Aggregates		Espec. peri-ductal	Generally, helper cells dominate	++			
Notes	Mainly IgA + Some IgG, M, D		Activated T cells 0.01%				

Macs = Macrophages; DCs = Dendritic Cells; pDCs = Plasmacytoid cells; Data from Ref. [11].

The *myoepithelial cells* lie scattered between the acinar and ductal cells and the basal lamina and are interconnected by gap junctions and desmosomes [21]. They synthesize basal lamina and their multiple processes form a functional network around the acinar and ductal cells, separating them from the basal lamina and the mesenchymal, stromal cells [22]. Myoepithelial cells contain contractile muscle proteins ( $\alpha$  smooth muscle actin, myosin, tropomyosin) [21], and are assumed to assist in expelling fluid from the acini and the ducts.

The lacrimal gland is innervated by the parasympathetic and sympathetic nervous system [23,24]. Nerve terminals are located in close proximity to acinar, ductal, and myoepithelial cells as well as blood vessels, and hence can control a wide variety of lacrimal gland functions [23,24]. Stimulation of lacrimal gland secretion occurs in part through a neural reflex arc originating from the ocular surface [13,15,23,25] with a further trigeminal input arising from the nasal mucosa [26]. Neurotransmitters and neuropeptides released by innervating nerves include acetylcholine, vasoactive intestinal peptide (VIP), norepinephrine, neuropeptide Y (NPY), substance P (SP), and calcitonin gene related peptide (CGRP). Each of these neuromediators interacts with specific receptors present on the surface of lacrimal gland cells to elicit a specific response [13,15,25]. Acetylcholine and norepinephrine are the most potent stimuli of lacrimal gland protein, mucin, water, and electrolyte secretion [13,15].

#### 4.2.3. Lacrimal gland stem cells

The lacrimal glands, like the salivary and mammary glands, retain their ability to regenerate through the whole life span. For epithelial cells of the salivary glands the reported cell turnover is 40–65 days for serous acini and 95 days for duct cells [27]. Since the lacrimal glands share many characteristics in common with the salivary glands, it is possible that lacrimal epithelial cells have a similar cell turnover rate.

Stem cells are present in the lacrimal glands of mice [28], rats [29] and humans [28] and their involvement in repair has been studied in mice [30]. In a lacrimal gland injury model, stem cells participated in lacrimal gland regeneration [31] and those isolated from murine glands by Ackermann et al. had the ability to differentiate into all three germ layers [28].

#### 4.2.4. Mechanisms of gland damage and repair

When the lacrimal gland is damaged acutely, (eg. following radiation exposure) or chronically (eg. in Sjögren syndrome and other autoimmune diseases) [32] the lacrimal gland is infiltrated by lymphocytes and other immune cells, with a predilection for the peri-ductal areas. This leads to a loss of acinar, ductal and myoepithelial cells, probably by both apoptosis and autophagy.

Remodeling following injury often recapitulates events that govern embryonic tissue development and it is therefore not surprising that programmed cell death and a number of growth factors and cytokines known to regulate tissue development play a role during lacrimal regeneration [30,32]. A key mechanism in the murine gland is *epithelial-mesenchymal transition* (EMT), which,

during embryogenesis, helps epithelial cells to acquire migratory and/or invasive properties [33]. During EMT, epithelial cells lose cell-cell and cell-matrix attachments, polarity and epithelial-specific markers, undergo cytoskeletal remodeling, and gain a mesenchymal phenotype [33]. Induction of EMT generates cells with mesenchymal stem-like properties, which can play a significant role in tissue repair [34,35].

#### 4.3. The meibomian glands

The meibomian glands are modified sebaceous, holocrine glands whose acini discharge their entire contents in the process of secretion. Their secretory product (meibomian lipid or meibum) is delivered into a shallow reservoir on the skin of the lid margin, just anterior to the mucocutaneous junction, and is spread onto the precorneal tear film with each blink. The embryology, anatomy, histology and physiology of the glands were reviewed fully in the report of the TFOS Meibomian Gland Workshop (2011) [36] and elsewhere [37] and only selected aspects are discussed here.

The development of the meibomian glands has features in common with that of the pilosebaceous unit [38]. The luminal cells of the meibomian ducts, corresponding to the keratinized lining of the lash shaft, express keratohyalin granules and have been regarded as a modified, keratinized epithelium [39]. The glands of Zeiss, which satisfy the sebaceous needs of the cilia, are analogous to the meibomian glands. It appears that the capacity of the meibomian duct cells to keratinize is amplified in certain conditions, such as meibomian gland dysfunction (MGD) where keratinization of the terminal duct is a key feature, in metaplastic trichiasis when dystopic cilia may arise from meibomian orifices, in distichiasis where a row of aberrant lashes replaces that of the meibomian glands, and in follicular ichthyosis where both the meibomian glands and pilosebaceous units of the skin are affected together.

The human meibomian gland is richly innervated with sensory, sympathetic, and parasympathetic nerves [40,41]. These nerve fibers express substance P (SP), vasoactive intestinal peptide (VIP), dopamine  $\beta$ -hydroxylase, acetylcholinesterase, nitric oxide synthase, tyrosine hydroxylase, somatostatin, neuropeptide Y (NPY), and calcitonin gene-related peptide (CGRP) [40,41]. Human meibomian gland epithelial cells also express functional muscarinic and VIP receptors, and respond to an acetylcholine analog, carbamyl choline, and/or VIP with alterations in cyclic AMP and intracellular  $[Ca^{2+}]$  levels and cellular proliferation [42]. During differentiation these cells also have increased expression of genes coding for proteins with neuron remodeling and axon guidance activities (e.g. netrin 4 and collagen, type V, alpha2) [43]. In addition to humans, the mouse meibomian gland contains mRNAs of receptors for cholinergic, adrenergic, NPY, serotonin, CGRP, dopamine,  $\gamma$ -aminobutyric acid, glutamate, neurotensin, and somatostatin [36,44].

Multiple factors are known to regulate the meibomian gland. The meibomian gland *in vivo* [36], (see Sex, Gender and Hormones Subcommittee report), and human meibomian gland epithelial cells *in vitro* [42,43,45–61], respond to numerous agents with

alterations in proliferation, differentiation, cAMP accumulation, signaling pathways, gene expression and/or lipogenesis. These compounds include androgens, estrogens, progesterone, glucocorticoids, insulin, pituitary hormones, mineralocorticoids, growth factors, bacterial toxins, antibiotics, cationic amphiphilic drugs, omega fatty acids, retinoic acid, high glucose, cyclosporine A, an IL-1 receptor antagonist, rebamipide, bimatoprost, pilocarpine and timolol [42,43,45–54,56–60,62,63].

Chemical analysis of expressed meibomian lipid shows it to consist of about 95% nonpolar lipids (mainly wax and cholesterol esters, with a small amount of triglycerides) and 5% of polar lipids, (the amphiphathic lipid, O-acyl- $\omega$ -hydroxy-fatty acid (OAHFA) [64] and phospholipids (PL) [65]. The concentration of OAHFA exceeds that of PL in meibum but the ratio is reversed in the tear film [66]. The lipid composition of meibum and tears is discussed fully in the Tear Film Subcommittee report.

The key building block for cholesterol and fatty acid synthesis is cytosolic acetyl-CoA, a product of carbohydrate, fatty acid or amino acid metabolism [67]. Cholesterol biosynthesis involves the successive conversion of acetyl-CoA to acetoacetyl-CoA, 3-hydroxy-3-methylglutaryl-CoA (HMG-CoA) and mevalonate, catalyzed respectively by acetoacetyl-CoA-synthase, HMG-CoA synthase 1 and HMGCoA reductase. Cholesterol itself is utilized in the synthesis of sex steroid hormones and the enzymes regulating this process are present in the human meibomian gland [68].

Fatty acid biosynthesis involves the initial conversion of cytosolic acetyl-CoA into malonyl-CoA, catalyzed by the rate-limiting enzyme, acetyl-CoA carboxylase. Malonyl-CoA is then converted into palmitoyl-CoA in the presence of the enzyme fatty acid synthase and ultimately, palmitoyl-CoA is elongated into longer chain, saturated fatty acids by the addition of 2-carbon units. Production of unsaturated fatty acids requires the action of fatty acid desaturases. The fatty acids are utilized to create neutral and polar lipids. Messenger RNAs for each of the above-mentioned enzymes and others involved in cholesterol and fatty acid synthesis, have been demonstrated in the murine meibomian gland in addition to mRNAs for the *sterol regulatory element binding proteins* (SREBPs) 1 and 2, which play a critical role in regulating their activity at a transcriptional level [69] SREBP 1 has also been identified in human meibomian gland epithelial cells [52].

The SREBPs, together with the *membrane binding transcription factor proteases*, (MBTPs), site-1 and 2, (otherwise known as site 1 and site 2 proteases - S1P and S2P) are key regulators of cholesterol and fatty acid synthesis and homeostasis [70].

SREBP-1 and SREBP-2 are membrane-bound transcription factors located in the endoplasmic reticulum (ER). When the cellular demand for lipid rises, SREBPs, complexed with the escort protein, Scap, are transported within coated vesicles to the Golgi apparatus, where they undergo activation within the Golgi membrane. This occurs in two stages. In the first step, the site-1 serine protease, S1P, cleaves the SREBP protein within the Golgi membrane. In the second step, the amino terminal fragment, containing the transcription factor, is rapidly released by the site 2 protease and migrates into the cell nucleus where it activates the transcription of genes needed for cholesterol uptake and synthesis as well as those involved with fatty acid metabolism [67,71,72].

There are additional membrane-bound transcription factors within the ER that act as so-called ER 'stress sensors'. A deficiency in either function, sterol biosynthesis or the ER stress response, may be the basis of the X-linked syndrome of *ichthyosis follicularis, atrichia, and photophobia* (IFAP syndrome), in which there is a failure of pilosebaceous development in the skin and lids resulting from mutations in the MBTPS2 gene [73].

Of relevance to the role of hormones on meibomian gland function and dysfunction, mRNAs for each of the above-mentioned

genes have been shown to be upregulated by testosterone in the castrated mouse model, including ATP-citrate lyase and acetyl-CoA synthase, enzymes which are critical for the initiation of lipogenesis [44,69]. Schirra et al. have suggested that the enhanced expression of genes for SREBPs 1 and 2 in response to androgen exposure may explain the hormonal induction of meibomian lipids [68]. SREBP 1 is known to be controlled by androgens at other sites [72].

#### 4.4. The conjunctiva

The conjunctiva is a mucous membrane with a *lamina propria* (stroma) of loose connective tissue, covered by an epithelium that is kept permanently moist. The conjunctiva acts as a barrier against the outer environment and secretes a variety of products into the tear film. It also takes up antigens selectively for immune protection. Several regions of the conjunctiva can be identified [74,75]. The 'marginal' zone extends from the subtarsal fold to the MCJ on the lid margin [76] and includes the mucosa of the lid wiper zone [36]. Proximal to this, the tarsal conjunctiva is tightly attached to the tarsal plate and then continues as a loose orbital zone towards the fornix.

##### 4.4.1. Conjunctival epithelium

The conjunctival epithelial cells are tightly connected by *adherens junctions* which provide strength against shear stress and the most superficial (i.e. layer 1) cells, are sealed by *tight junctions* which act as a barrier against the outside world. This barrier is less tight than that of the corneal epithelium [77]. Alterations of conjunctival and corneal integrity are associated with ocular surface disease [78]. Between the conjunctival epithelial cells are considerable intercellular spaces [79] that are assumed to be associated with a role in water transport across the epithelium. The conjunctival epithelium consists of two cell types - the epithelial cells and the goblet cells, both deriving from the same conjunctival stem cell [80].

The conjunctival epithelial cells produce, apart from water, electrolytes and mucins [81], functional proteins such as lubricin [82]. The layer 1 cells produce integral membrane mucins that constitute the superficial glycocalyx of the cell, necessary for wetting by the aqueous tears [83]. Conjunctival epithelial cells contain transmembrane water channels (aquaporins) concerned with water movement between the conjunctiva and the aqueous phase of the tear film [84]. A further epithelial function may be an SC-mediated transcytosis of IgA, from plasma cells in the lamina propria, but this has yet to be shown [85].

##### 4.4.2. Conjunctival epithelial stem cells

Stem cells may be defined as progenitor cells with a high capacity for cell division and the ability to generate a terminally differentiated progeny [86,87]. The stem cells of the corneal epithelium are located at the limbus and the subject has been reviewed extensively [88–91]. The location of the conjunctival stem cells in the human is more controversial. Wei et al., using tritiated thymidine in the rabbit concluded that the fornix was a major site of conjunctival stem cells [92,93]. Pellegrini et al., however, using clonal analysis of cells from various sites, reported that conjunctival stem cells are uniformly distributed in the human bulbar conjunctiva [80]. Pe'er and colleagues, in the mouse, using a tritiated thymidine label, identified conjunctival progenitor cells at both the limbus and the mucocutaneous junction (MCJ), with the MCJ giving rise to cells that streamed toward the fornix [94]. Wirtschafter et al., reported a similar finding in the rabbit, with a focus of label-retaining cells at the MCJ of the lid margin, whose transient amplifying progeny migrated over time towards the

fornix [95]. They inferred that conjunctival stem cells were located mainly at the MCJ. Most recently, in human cadaveric tissue, Stewart et al. have reported the expression of stem cell markers scattered throughout the conjunctiva, with highest levels in the medial canthal and inferior fornical areas [96].

#### 4.4.3. Conjunctival goblet cells

Human conjunctival goblet cells are present as single cells, scattered throughout the conjunctival epithelium save for a small temporal, perilimbal patch. Their numbers increase from the superior temporal region to the inferior nasal region of the conjunctival sac [97]. They package and secrete the gel-forming mucin, MUC5AC [83], which, when fully glycosylated has a mass of up to 40 MDa [98,99].

Gel mucins have an enormous water-binding capacity and thereby transform the aqueous tears into a mucoaqueous gel that makes up the main volume of the precocular tear film and maintains moisture at the ocular surface [100]. Mucins also have a lubricative function at the lid-globe interface that is important for movements of the eye-ball relative to the lids. This lubricative function is needed in particular at the elevated epithelial lip of the *lid-wiper*, where the posterior border of each lid comes into close contact with the globe. Here, goblet cells are supplied within mucus crypts [101], similar to those in the tarsal conjunctiva [102]. The mucin of the mucoaqueous layer has other protective properties, binding microorganisms and inhibiting their attachment to the epithelium and also binding sIgA and several antimicrobial proteins and peptides [103]. In this way it serves as an integral component of the ocular surface surveillance system [104]. The role of T helper cell (Th1 and Th2) cytokines in goblet cell homeostasis [105] is discussed in a later section.

Release of the secretory mucin, MUC5AC, can be induced by either parasympathetic or sympathetic nerve stimulation [106–108]. In the rat, the parasympathetic neurotransmitters acetylcholine and vasoactive intestinal peptide (VIP) stimulate conjunctival goblet cell secretion *in vivo*, in both cells and organ culture [108–110]. In addition, nucleotides that activate the P2Y<sub>2</sub> receptor, such as ATP and UTP, and also P2Y<sub>2</sub> receptor agonists, can stimulate goblet cell mucin secretion in rat and human conjunctiva [111,112]. Additionally, the epidermal growth factors (EGF) and brain-derived growth factor (BDNF) stimulate a slow release of MUC5AC from cultured rat conjunctival goblet cells [110,113].

#### 4.4.4. Resident immune cells of the conjunctiva

A study of the resident leukocytes of the human conjunctiva by Hingorani et al. showed a greater number in the bulbar than tarsal conjunctiva [114], although other distributions have been reported [115].

*T cells* (CD3<sup>+</sup>) were the dominant cell population, 75% of which were memory, or primed T cells (CD45Ro<sup>+</sup>) rising to 75–100% in the epithelium. CD8<sup>+</sup> T cells were more common than CD4<sup>+</sup> T cells in the epithelium whereas their numbers were roughly equal in the stroma. *Macrophages* (CD68<sup>+</sup>) were the second most frequent conjunctival leukocyte present in both epithelium and stroma, accounting, with Langerhans cells, for those cells expressing HLA DR. The exact numbers of leukocytes in general and lymphocytes in particular vary in different studies [114,116,117], but authors agree that T-lymphocytes dominate over B-lymphocytes, and that, of the plasma cells, those that produce IgA by far outnumber those that produce IgM. Neutrophils and occasionally, B cells, were present in the epithelium of both bulbar and tarsal conjunctiva while plasma cells, natural killer (NK) cells and mast cells, present in small numbers, were confined to the stroma. As Hingorani et al. conclude, T cells, macrophages and occasional B cells and neutrophils in the epithelium and T cells, B cells, macrophages, plasma cells, NK cells,

mast cells and neutrophils in the substantia propria may be considered normal. A fuller review of the cellular, ocular surface immune defence system will be found elsewhere [117–119].

Hingorani et al. found only a single example of a lymphoid aggregate compatible with the presence of CALT (conjunctiva-associated lymphoid tissue), part of the MALT system of mucosa-associated lymphoid tissue, but did not examine fornical tissue, where CALT aggregates are most likely to be found [120]. Wotherpoon et al. [121] who examined the entire human superior and inferior fornical conjunctiva in autopsy material found organised lymphoid tissue in only 31% of cases. The resident immune cells of the conjunctiva are summarised in Table 2 and those of the cornea in Table 3.

#### 4.5. The glycocalyx of the ocular surface epithelia

The apical membranes of the layer 1 cells of the ocular surface epithelia present microvilli and microplicae which project into the tears and increase the interactive surface area at the tear/cell interface. Contiguous layer 1 cells are connected by tight junctions which restrict the entry of water-soluble solutes into the epithelium, and a further barrier is provided by the dense, apical glycocalyx [122], rich in transmembrane mucins [83]. Heavy glycosylation of the mucin exodomains converts the plasma membranes from a hydrophobic to a hydrophilic surface, which confers *wettability* to the epithelium [123–125]. The glycocalyx also acts as a lubricant that reduces friction at the ocular surface [126,127] and as a disadhesive that combats microbial colonization [128,129].

##### 4.5.1. The transmembrane mucins

The *transmembrane mucins* of the human corneal and conjunctival epithelial glycocalyx [130], are MUC1 [131], MUC4 [132] and MUC16 [133], with galectin-3 playing additional roles [134]. The membrane-associated mucins possess short cytoplasmic tails, a single transmembrane domain and highly O-glycosylated extracellular, ectodomains with a variable number of tandem repeats (VNTR) [135,136] which extend at least 200–500 nm above the plasma membrane, far beyond other cell surface glycoproteins [137,138] thereby projecting into the tear film.

MUC1 is the smallest of the three glycocalyx mucins, with a molecular weight of approximately 120–300 kDa, roughly doubling in size after full glycosylation [139]. MUC1 exhibits anti-adhesive, cell-cell and cell-extracellular matrix properties [140,141]. The cytoplasmic tail of MUC1 (MUC1-CT) engages in signaling activities involving phosphorylated serine and tyrosine residues that act as binding sites for molecules such as NF-kB [142]. These can regulate the transcription of proinflammatory cytokines, abrogate the interaction of  $\beta$ -catenin with E-cadherin and upregulate the expression of the epithelial mesenchymal transducers (EMTs) [143].

MUC4 has a molecular mass of 900 kDa, several times greater than that of MUC1 [139]. It is expressed predominantly by conjunctival epithelium and to a lesser extent by the epithelium of the limbus and peripheral cornea. Very little is expressed in the central cornea [132,144].

MUC16 is the largest mucin yet identified in the human body, with a molecular mass of 2.5 MDa and a potential glycosylated mass of approximately 20 MDa [136,145,146]. The ectodomain of MUC16 is heavily O-glycosylated and longer than that of the other transmembrane mucins. Its cytoplasmic tail binds to the ezrin/radixin/moesin (ERM) family of proteins, which *anchor the mucin* to the actin cytoskeleton of the microvilli [128]. Knockdown of MUC16 expression in human corneal epithelial limbal cells, resulted in increased rose bengal dye penetration, increased *Staphylococcus aureus* binding to the epithelium [128] and disruption of tight

**Table 2**  
Resident immune cells of normal human conjunctiva.

Layer	T cells	Macs	LCs	PMNs	B-cells	Plasma cells	NK cells	Mast cells
Epithelium	++++ T cells CD8 <sup>+</sup> > CD4 <sup>+</sup> CD8 <sup>+</sup> /CD4 <sup>+</sup> = 3.3	+++	+	+	±			
Stroma	++++ T cells CD8 <sup>+</sup> ≅ CD4 <sup>+</sup> CD4 <sup>+</sup> /CD8 <sup>+</sup> = 1.3	+++			±	+	+	+

Macs = macrophages; LCs = Langerhans cells; PMNs = neutrophils; NK = natural killer cells; Data from Refs. [114,121,1104,1105].

**Table 3**  
Resident immune cells of normal human cornea.

Corneal Layer	Cell type (Phenotype) <sup>a</sup>	Peripheral Cornea <sup>b</sup>	Central Cornea
Epithelium	<b>Langerhans cells</b> (CD45 <sup>+</sup> CD11c <sup>+</sup> CD11b <sup>lo</sup> MHC II <sup>+</sup> Langerin <sup>+</sup> )	++++	++
Stroma	<b>Bone marrow-derived DCs</b> <sup>a</sup> (CD45 <sup>+</sup> CD11c <sup>+</sup> CD11b <sup>+</sup> CD8α <sup>-</sup> MHCII <sup>+/−</sup> CD80/86 <sup>+/−</sup> )	++++	++
	<b>Non-LC DCs</b> <sup>a</sup> (CD11c <sup>+</sup> Langerin <sup>+</sup> CD11b <sup>+</sup> CD103 <sup>lo</sup> )	+++	++
	<b>Macrophages</b> (CD45 <sup>+</sup> CD11b <sup>+</sup> CD11c <sup>-</sup> )	+++	++
	<b>Monocytic precursor cells</b> CD14 <sup>+</sup> MHCII <sup>-</sup> B7 <sup>-</sup> CD40 <sup>-</sup> GR1 <sup>-</sup> CD3 <sup>-</sup> )	+++	+++
	<b>Tissue PMNs</b> (CD45 <sup>+</sup> Ly6G <sup>+</sup> )	+	-

<sup>a</sup> DC, dendritic cells; LC, Langerhans cells; PMNs, polymorphonuclear cells.

<sup>b</sup> Including limbal region; Data from Refs. [474,1106–1111].

junctions [147]. This, and other evidence [148] confirms MUC16 as a key component of the human epithelial glycocalyx barrier, also contributing to the tight-junctional, paracellular barrier at the ocular surface. By contrast, knockdown of MUC1 does not lead to decreased barrier function and moreover, significantly increases the barrier to dye penetrance and bacterial invasion [149].

The soluble lectin galectin-3, the most highly expressed carbohydrate-binding protein of the human conjunctival epithelium [150] is a component of the epithelial glycocalyx. Its carbohydrate recognition domains (CRD) [151] bind to the β-galactoside-containing glycans [152,153], MUC1 and MUC16, to form a polymeric, *galectin-glycoprotein lattice* which serves various biological functions, such as the regulation of receptor turnover and modulation of cell-cell, cell-matrix and cell-pathogen interactions [153]. Additionally it contributes to the barrier function of the glycocalyx. Downregulation of O-glycan synthesis by human corneal epithelial cells in culture, reduces the barrier to rose bengal penetration, by decreasing galectin-3 binding within the glycocalyx [134] and a similar loss of barrier function occurs, in the absence of galectin-3 expression [134]. These findings indicate that mucin O-glycan interaction with galectin-3 creates a protective lattice barrier within the apical glycocalyx [134,154]. Galectin-3 concentration in the tears may be of future interest as a marker for DED severity since its affinity for glycans of the glycocalyx may be reduced by alterations in glycosylation, or it may be released from the ocular surface inflammatory cells [155].

#### 4.5.2. Other mucin species

The gel-forming mucin MUC5AC is the chief secretory mucin of the human ocular surface [132,156,157] although the soluble mucin MUC7 is detected in the lacrimal gland and in the conjunctival epithelium [17,158]. In human tears, MUC1, MUC4, MUC16 and MUC5AC are present, and MUC2<sup>159</sup> is also detected at very low levels in the conjunctiva [157]. MUC20, which is the most highly expressed mucin in human conjunctiva [150], is localized along the cell membranes of the intermediate cell layers of the corneal and conjunctival epithelia [160]. mRNA transcripts of the transmembrane mucins MUC13, MUC15 and MUC17 have been identified in human conjunctiva [150,158,160]. Their functions here, as well as that of MUC20, here have not yet been elucidated.

#### 4.6. The tear compartments

When the eyes are open the tears are distributed in 3 compartments. The *fornical compartment*, occupies the fornix and retroarsal space and the *tear menisci* and *tear film* form the *preocular tears*. The fornical compartment is assumed to be narrowest at the *lid wiper* region of the lid margin, which is directly apposed to the globe. The preocular tear film overlies the exposed conjunctiva and cornea [161]. The precorneal tear film follows the contours of the cornea, is roughly 3 μm in thickness and is highly stable [162]. The prebulbar film follows the varying contours of the bulbar conjunctiva but its thickness is unknown.

##### 4.6.1. The tear menisci

Tear menisci are strips of aqueous tear fluid lying in the angle between the globe and apposed lid margins, which are formed by surface tension forces as the lids separate, in a few hundred milliseconds, in the upstroke of the blink. A negative hydrostatic pressure within the nascent menisci draws water from the forming tear film, causing the two compartments to separate over a region of *meniscus-induced thinning*. [163,164] This is observable as a *black line* of reduced fluorescence in the fluorescein-stained tear film, where the aqueous layer is of minimum thickness while the lipid layer remains intact (Fig. 1) [165]. There is no evidence for a gel-like layer in the menisci. Instillation of an aqueous drop expands the volume of the meniscus and tear film and transiently obliterates the black line [166].

The negative hydrostatic pressure within the menisci is responsible for their concave external surface and opposes the outflow of aqueous into the puncta, so that drainage is limited to roughly the first 2s of the blink interval [167,168]. This effect is enhanced as meniscus volume falls and may play a conserving role in aqueous-deficient DED (ADDE).

**4.6.1.1. Tear volume and secretion.** The volume of the menisci is directly related to the total volume of the tear fluid [169] and to the lacrimal secretory rate [170]. Since the height and radius of curvature of the tear menisci are reduced in ADDE their measurement is of diagnostic value in DED diagnosis [168,171,172]. The volume of the tears has been estimated to be about 7 μl [173] and secretory rate 1.03 ± 0.39 μl/min, with a tear turnover (TTR) of 16.19 ± 5.10%/min [174]. The LG is responsible the bulk of the tear volume and flow [170] with a smaller portion secreted by the conjunctiva [81].

Lacrimal fluid is distributed to and mixed with the precorneal film during the blink and is then lost by drainage from the tear menisci via the nasolacrimal system. It is further lost by evaporation from the exposed precorneal tears [175–177].

#### 4.6.2. The precorneal tear film

The precorneal tear film has a superficial lipid layer and a mucoaqueous layer which occupies the bulk of the tear thickness and interacts directly with the glycocalyx of the epithelium (see Tear Film Subcommittee report). There is also a slender, superficial aqueous layer. The tear film is highly stable and its layers cohere during movements of the eye [178].

#### 4.6.3. Tear film lipid layer

The tear film lipid layer (TFLL) derives from the meibum reservoir at the lid margins and is spread onto the tear film with each blink, driven by surface tension forces. It has a mean thickness of 42 nm (15–157 nm) [179]. It plays a significant role in stabilizing the tear film and has been considered until recently to provide a barrier to tear evaporation [36,180,181]. However, some past and more recent studies have suggested that it reduces evaporation from the mucoaqueous subphase by no more than 10% [182]. This question is critical to the designation of some forms of DED as evaporative (EDE) – ie. dependent on an excessive evaporative loss from the ocular surface and is discussed further in the report of the Tear Film Subcommittee.

The meibomian glands secrete a lipid mixture (meibum) which is liquid at body temperature, with a melting range between 19.5 and 32.9 °C according to Tiffany [181], or 10–40 °C according to Butovich et al. [183]. The clear oil can be expressed from the meibomian orifices by pressing over the glands through the closed lids. Expressibility is greatest nasally and least temporally [184]. Delivery of oil to the lid margin occurs in part through secretion and in part by the expression of small aliquots with each blink. The lid reservoir contains at least 30 times the amount of lipid present on the surface of the tear film (approximately 300 µg vs 10 µg, respectively [185,186]).

It is likely that excretion of meibum occurs by flow of lipid from the reservoirs over the lid margin skin and lashes. This would serve to resist tear film contamination by sebaceous skin lipids (sebum).

In keeping with the earlier proposal of Holly [187] and further studies by McCulley [188], the TFLL is considered to organize itself into a deep layer, a few molecules thick, rich in polar lipids and

some long-chain fatty acids and a superficial layer of non-polar lipids. Some proteins and glycoproteins, such as lipocalins, lysozyme, and mucin, are thought to be intercalated with the lipid layer and enhance its stability [189–191].

**4.6.3.1. Spreading of the lipid layer.** The tear film lipid layer is formed in the upstroke of each blink, when lipid from the lower meibomian reservoir spreads upward over the aqueous subphase of the precorneal tear film [192,193]. It has been suggested that thinning of the lipid layer superiorly creates a local rise in surface tension, which is the driving force for spreading [193]. It has been proposed that spreading initially involves an interaction between the polar meibomian lipids and the aqueous phase of the tear film [190] and that the polar lipid layer then acts as a carrier for the nonpolar lipid fraction. In the normal eye, spreading of the tear film lipid layer can be observed clinically by interference video microscopy, when it is seen as an upwardly moving front of horizontally-disposed, colored fringes. The lipid film spreads rapidly at first (about 10 mm/s), lagging markedly behind the upper lid, whose excursion is completed over a few hundred milliseconds [194]. Spreading slows and stabilizes after 1 s or more, with the interference pattern showing remarkable stability over the remainder of the blink interval [194,195].

Spreading of the TFLL is slower in patients with a tear film lipid deficiency (Goto 2003) and also in aqueous tear deficiency [194], which is attributed to the thinness of the aqueous phase. Also, in the former condition the spreading TFLL pattern takes on a more vertical arrangement [195].

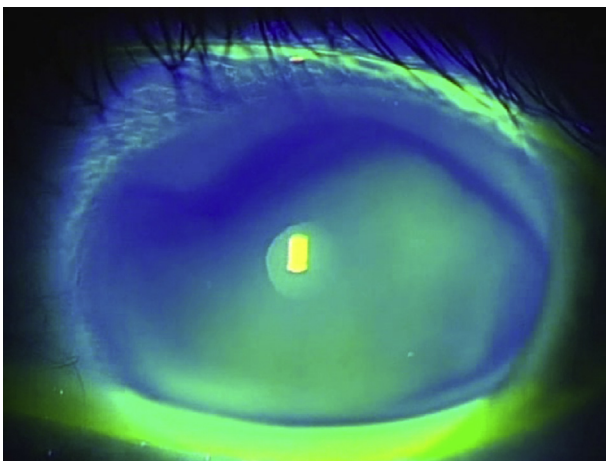
The pattern of colored fringes shown by interferometry is due to topographic variations in thickness of the lipid layer across the film and reflects its intermolecular organization. This can be shown to be remarkably stable during blinking and eye movements. Over a series of blinks the pattern can retain its gross features from blink to blink, only degrading by degrees in a stepwise fashion until it changes abruptly and the process begins again [197]. In this situation it appears that the TFLL is stripped from the mucoaqueous layer and compressed during the downstroke of the blink and restored in the upstroke, with only a moderate disturbance of its intermolecular organization between consecutive blinks. The period over which this can be observed may be greatly shortened in patients with a tear lipid layer deficiency suggesting that intermolecular stability is lost [198]. This is the basis of a clinical test [199].

Similarly, the interference pattern shows great stability during a series of horizontal saccades, again showing only a moderate stepwise degradation over a series of saccades. In this case the TFLL and mucoaqueous subphase behave as a fluid shell that moves with the cornea during each saccade [197]. The influence of a DED state on this behavior would merit study.

#### 4.6.4. The aqueous layer and mucoaqueous subphase

Deep to the TFLL is a mucin-rich layer that is conveniently referred to as the mucoaqueous subphase [200]. The presence of a superficial aqueous layer at its surface, as proposed by Wolff (Wolff 1946) has been debated [201], but it is reasonable to assume that in the process of tear film formation, as aqueous tears are drawn off into the menisci, some residual fluid is retained at the surface of the mucoaqueous layer. (See Tear Film Subcommittee report) This fluid layer can be expanded transiently by the instillation of a saline drop [166].

Observation of the fluorescein-stained tear film indicates that the mucoaqueous layer of the *precorneal film* is freshly deposited with each blink and has the physical properties of a gel, due to the presence of the goblet cell mucin [197]. Its mucin component is presumed to be a product chiefly of the tarsal goblet cells, whereas



**Fig. 1.** A fluorescein-stained lower tear meniscus, following drop instillation. The meniscus is broad and full and is segregated from the stained precorneal tear film by a black line of meniscus-induced thinning.

that of the *prebulbar film* is likely to be an admixture of mucins from both tarsal and bulbar glands. An additional coating is received by the peripheral cornea as it passes behind the lids during eye movements in any direction of gaze [197].

The mucoaqueous subphase performs a lubricating function between the lids and globe [99] and probably maintains wettability of the ocular surface where the glycocalyx is defective, for instance after an abrasion [201]. It also traps shed epithelial cells, inflammatory cells, debris and microorganisms, which are collected into a mucous thread in the lower conjunctival sac and ultimately lost via the punctum [202,203].

The mucoaqueous layer contains salts and numerous proteins derived from the LG and conjunctiva and meibomian gland. Proteins include growth factors such as epidermal growth factor and hepatocyte growth factor, that are essentials for the maintenance of the epithelium [204,205]. There are also defense proteins, such as lysozyme, lactoferrin, surfactant protein-D, and trefoil peptide, concerned with innate immunity, and sIgA [205,206]. Those proteins of lacrimal origin, such as lysozyme and lactoferrin, are decreased in ADDE, making the eye more vulnerable to infection. It has been predicted that the level of these proteins will be normal in EDE where lacrimal function is normal and it would be of the value to test this prediction [207].

Plasma proteins, such as albumin, may leak into the tears in DED as a result of inflammation, due to an increase in conjunctival vascular capillary permeability [205,208,209] and, probably, also conjunctival epithelial permeability. The LG cannot be excluded as an additional source.

#### 4.7. Closed eye tears

Overnight eye closure causes a number of physiological changes at the ocular surface. The  $pO_2$  falls and there is a shift towards anaerobic tissue metabolism [210,211]. The tear pH and tear osmolarity fall [212,213], the anterior cornea becomes relatively hypoxic, epithelial permeability increases and corneal edema occurs [214,215]. There is no change in tear glucose levels [216].

Jordan and Baum proposed that, in the waking state, tear secretion is driven in part, by sensory stimuli from the ocular surface, with the expectation that it will be at its lowest when ambient stress is at a minimum [217]. This was born out by the studies of Sack and colleagues, who demonstrated that lacrimal secretion was negligible after an extended period of sleep or eye closure, a change accompanied by a sharp rise in the level of tear sIgA, from around 2% in reflex tear samples, compared to 58% in closed eye tears [218]. Conversely, the levels of lysozyme, lactoferrin and lipocalin, proteins of lacrimal origin which account for about 85–88% of the total protein in basal and reflex tear samples, decrease in closed eye tears to less than 30% of the total [218]. The rise in sIgA concentration may reflect that, unlike the lacrimal-specific proteins, lysozyme, lactoferrin and lipocalin and peroxidase [219], the secretion of sIgA, of plasma cell origin, is not directly coupled to lacrimal secretion. Therefore the rise could be explained by the continued delivery of IgA at the same rate into a lacrimal fluid of greatly reduced volume. This fall in volume secretion also explains, in part, the rise in tear concentration of certain plasma proteins such as vitronectin, fibronectin,  $\alpha$ 1-antiprotease,  $\alpha$ 2-antiplasmin,  $\alpha$ 1-antichymotrypsin and IgG [220,221], which enter the tears by diffusion across conjunctival capillary and epithelial barriers. Such proteins are present in closed eye tears at 2–4% of the serum level, well above the level found in reflex tears. Sack also refers to an increase in vascular permeability in the closed eye state [209].

A striking feature of closed eye tears is a massive accumulation of activated PMNs within the tear fluid several hours after eye closure [218]. Their appearance is preceded by 1–2 h [222] by very

high levels of two potent leucotoxic mediators, IL-8 and LTB<sub>4</sub>. Up to 70% of this leukotoxic activity is removed by immunoprecipitation with antibodies to IL-8, indicating that it is not substantially of PMN origin. Degranulation of the PMNs releases several potent proteases, such as protease-3, elastase, cathepsin G, MMP-9 and urokinase, which, due to the simultaneous presence of a wide range of antiproteases, do not lead to autolytic digestion. Also, despite the presence of the potent angiogenic agent, 12 (R)- hydroxyeicosatrienoic acid [223], and of IL-8, which might stimulate corneal neovascularization, a build-up of  $\alpha$ 2-macroglobulin ( $\alpha$ 2-M) and the conversion of plasminogen to angiotatin appears to prevent this outcome.

Closed eye tears are also extremely rich in reactive complement products, normally absent [224] from open eye tears. Closed eye tears contain all of the complement components required for the classical and alternate pathways of complement activation, in a concentration of about 2–4% of that of serum. Factors B and C3, however, reach levels approaching one-third that in serum, suggesting a local source [224]. A significant proportion of the C3 in closed eye tears is converted to C3c and Sack et al. inferred that, since closed eye tears contain two inhibitors of complement conversion, (lactoferrin and sIgA) C3 conversion probably occurs through the alternative pathway or by plasmin cleavage [218]. It was also proposed that modulators of complement activation divert the complement system away from membrane-attack complex formation towards opsonization.

In summary, powerful defense and scavenging mechanisms come into play during prolonged eye closure, which serve to remove microbial threats to the ocular surface. These events are highly regulated so that no harm comes to the ocular surface itself. However, this is a potentially risky strategy that could be destabilized in the DED state and the Subcommittee recommends the investigation of closed eye tears and of conjunctival impression cytology specimens following prolonged eye closure, in DED patients. There will be added interest to study patients with Sjögren syndrome, since a genetically-determined, dysfunctional response to inflammatory triggers might create a dysfunctional closed eye tear response.

#### 4.8. Extracellular DNA and NETs in dry eye

A new mechanism leading to tissue damage in DED has been identified since the TFOS DEWS report [1], involving the release of DNA into the tears from desquamating ocular surface epithelial cells and invading neutrophils. This extracellular DNA (eDNA) can, on its own or combined with molecular components of neutrophil origin, cause direct damage to the ocular surface.

##### 4.8.1. Extracellular DNA of epithelial origin

A source of eDNA is from desquamated ocular surface epithelial cells, of conjunctival [114,225] and presumably, corneal origin. Extracellular DNA, facilitated by cathelicidin binding [226], is able to enter cells and stimulate an inflammatory signaling pathway [227], by binding to TLR9 within the cell and initiating a signaling cascade through MyD88. This has two consequences: i. the initiation of a type 1 IFN response [228], and ii the generation of a powerful neutrophil recruitment signal [229–231]. In support of this concept, topical application of a synthetic bacterial DNA mimic to injured corneal epithelium results in the recruitment of neutrophils to the corneas of wild-type, but not TLR9<sup>-/-</sup> mice [232]. Increased expression of mRNA for TLR9, MyD88, and IFN-type I pathway genes has been found in the exfoliated conjunctival cells from patients with severe ADDE [114,225] and patients with primary Sjögren syndrome [233], suggesting that epithelial cells contribute to the inflammatory response directly and also engage in



PMN recruitment. Type 1 IFNs (IFN- $\alpha/\beta$ ) augment dendritic cell maturation and activate the adaptive immune system. Increased expression of mRNA for IL-6 and TNF- $\alpha$  was also demonstrated in exfoliated conjunctival cells. The expression of these inflammatory cytokines increases in the corneal and conjunctival epithelium in some forms of experimental DED [234,235].

#### 4.8.2. Extracellular DNA of neutrophil origin

Neutrophils are key players in the host innate immune response and constitute a first line of defense. While they are present only in small numbers in the normal conjunctiva [114] they are recruited to the ocular surface in profusion in inflammation and are abundant on the ocular surface and in the tears of patients with severe ADDE [114,225].

One strategy adopted by neutrophils in their defense against microorganisms is to release cellular contents into the extracellular space to form Neutrophil Extracellular Traps or NETs [236]. These comprise extracellular webs or scaffolds containing decondensed chromatin, histones, neutrophil elastase and antimicrobial peptides such as cathelicidin, each of which individually may be toxic for epithelial cells [237]. Extracellular histones are major mediators of cell death in sepsis [238], cathelicidin fragments are considered to cause erythema, inflammation and telangiectasia in patients with rosacea [239], and neutrophil elastase induces epithelial cell apoptosis [240]. NETs, with all their molecular components, have been demonstrated in mucoid films at the ocular surface in DED [114,225] (Fig. 2). It has been suggested that their association with mucin relates to the action of neutrophil elastase in cleaving the extracellular domains of membrane-associated mucins [241]. In other studies, it has been shown that mucins may induce neutrophil activation [242].

In the healthy eye, NETs may play a physiological role in the defense against pathogens by means of an antimicrobial action and by confining pathogens to a local site of infection [243]. Additionally, immobilization of neutrophil granules within NETs may prevent the diffusion of potentially noxious proteins and proteases to the ocular surface. However, in patients with severe ADDE, eDNA and NETs are present at the ocular surface in excessive amounts [225] and evidence suggests that they participate in the pathogenesis of the disease [225]. There are two explanations for their high levels:

- i. Exposure of neutrophils to hyperosmolar stress is a stimulus for NET formation, and the quantitative release of NETs increases exponentially with increase in hyperosmolarity. This is relevant to the situation in severe DED, where, for reasons discussed elsewhere, high levels of osmolarity may be achieved in the tears [244]. Hyperosmolar stress also has an inhibitory effect on some critical neutrophil functions such as migration and degranulation. Thus, in a hyperosmolar milieu, the classical neutrophil-related innate defense mechanisms may be compromised.
- ii. In physiological conditions, the level of eDNA and NETs in the tears is regulated by tear nucleases of lacrimal origin, DNase I, and lipocalin, (an endonuclease with a lower level of activity). Nucleases hydrolyze eDNA and enable its clearance from the ocular surface. The concentration of DNase I in tear fluid is similar to that in serum and saliva. Importantly, tear fluid nuclease activity was shown to be low or absent in ADDE patients [114,225], providing an additional basis for the rise in eDNA and NETs in the tears in the DED state, including Sjögren syndrome DED (SSDE), non-Sjögren syndrome DED (NSDE) and GVHD [245].

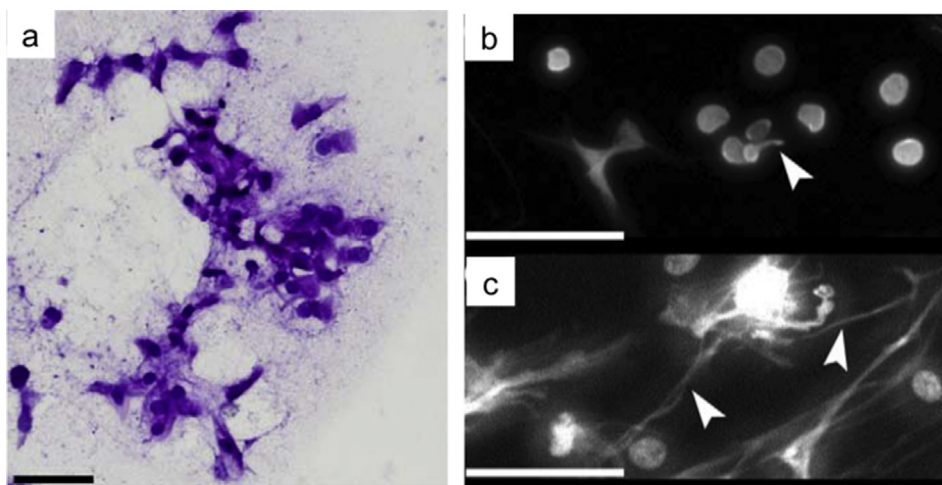
Thus it appears that in DED, NET production is stimulated by tear hyperosmolarity and clearance of both eDNA and NETs is impaired by the tear nuclease deficiency. Both may participate in further neutrophil recruitment [225,244]. The use of topical DNase I therapy for DED is being explored [245].

The Subcommittee recommends that this be considered as an important area for future research, exploring its involvement in lesser degrees of DED and also any interaction with the PMN response in closed eye tears.

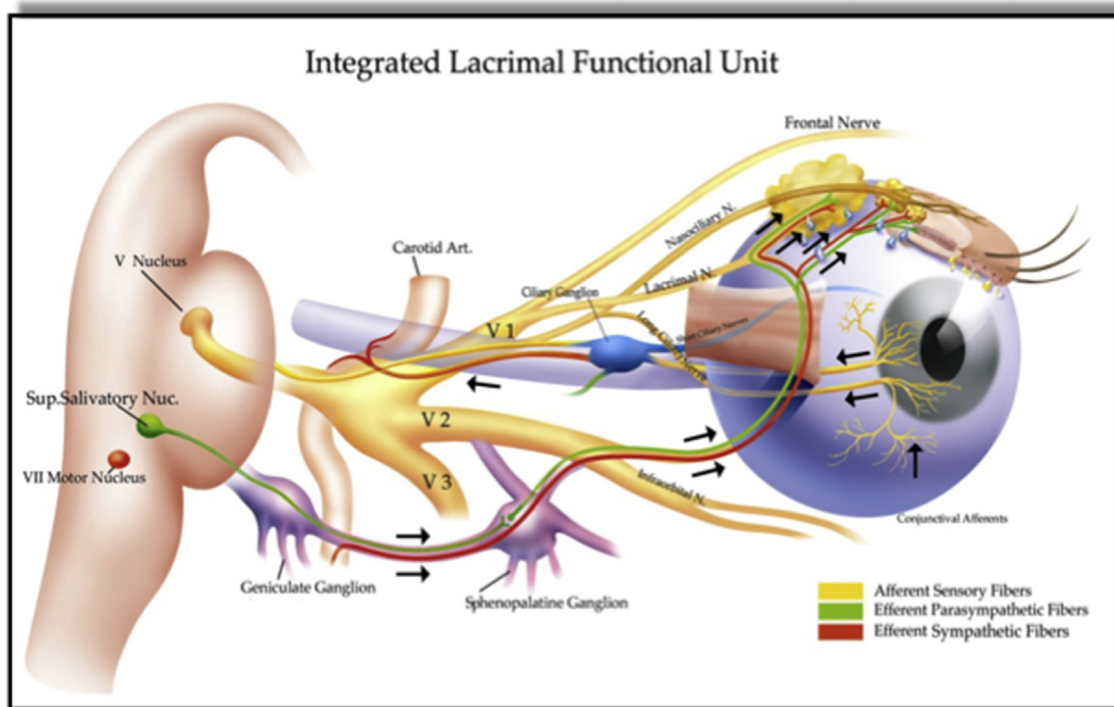
#### 4.9. Homeostasis of the tears at the ocular surface

##### 4.9.1. The lacrimal functional unit (LFU)

The production of aqueous tears is regulated to maintain tear osmolarity within narrow limits at all times [246]. Tear homeostasis is achieved reflexly by the *lacrimal functional unit* (LFU), which consists of the ocular surface, its secretory appendages and the connecting innervation, (Fig. 3) [247]. The trigeminal innervation of the ocular surface epithelia, including the cornea, conjunctiva and lid margins, provides the afferent limb of the feedback loop. The



**Fig. 2.** a. H&E staining of exfoliated surface cells. b. Wide-field fluorescent microscope image after DAPI staining of conjunctival impression material reveals short, sparse eDNA strands (arrowhead) in normal subjects and c. numerous long eDNA strands in a DED patients (arrowheads). (from Sonawane, S., et al. (2012). "Ocular surface extracellular DNA and nuclease activity imbalance: a new paradigm for inflammation in DED." *Invest Ophthalmol Vis Sci* 53(13): 8253–8263. – with permission) [225].



**Fig. 3.** Representation of the Lacrimal Functional Unit. In the waking state aqueous tear flow is modulated by reflex impulses from the ocular surface and nasal passages which travel in the trigeminal nerve to synapse in the superior salivatory nucleus. (from *Dry Eye and Ocular Surface Disorders*, Pflugfelder, Beuerman, Stern, 2004 – with permission) [1102].

parasympathetic, secretomotor innervation of the ocular appendages, including the lacrimal gland (main, palpebral and accessory), meibomian glands and the conjunctival goblet cells, provides the efferent limb of this loop. The nasolacrimal passage is also considered to contribute to this reflex system [248]. Another reflex arc that serves to protect the ocular surface is that subserving the blink.

#### 4.9.2. The secretory reflex arc

The afferent limb of the reflex arc arises in the trigeminal nerve, whose central endings synapse with neurons in the superior salivatory nucleus in the brain stem, probably located caudal to the nucleus of the seventh cranial nerve [77]. In the rabbit, the sensory innervation of the central cornea is about 10–20 times that of tooth pulp, while that of the conjunctiva generally is of a lower degree [249]. However, the sensitivity of the posterior lid margin is similar to that of the central cornea [250], which is of relevance to the symptoms of blepharitis.

The efferent limb of the reflex arc is a parasympathetic pathway whose secretomotor, preganglionic fibres arise in the superior salivatory nucleus. These fibres exit the pons by the *nervus intermedius* of the seventh cranial nerve and reach the *pterygopalatine ganglion* via the nerve of the pterygoid canal. Here, they relay and the postganglionic fibres reach the lacrimal gland via the lacrimal nerve. An alternative postganglionic pathway has been described, reaching the gland via the retro-orbital nerve plexus [251].

The nature of the relay between the afferent and efferent fibres, in the superior salivatory nucleus, the involvement of interneurons and the interaction with other inputs and supranuclear pathways, is not known, nor is the level of central cross-connectivity between ipsilateral inputs and contralateral outputs fully established. Current studies have not excluded their existence [252]. This contrasts with observations concerning the drive to lacrimal secretion from

the nasolacrimal mucosa where cross-connectivity has been demonstrated [26] – ipsilateral anesthesia of the nasal mucosa reduces lacrimal secretion on both sides.

#### 4.9.3. Afferent inputs from the ocular surface

**4.9.3.1. Lacrimal secretion and the blink.** The trigeminal afferents from the cornea serve a range of sensory modalities which include pain, mechanoreception and temperature and full details are given in the report of the Pain and Sensation Subcommittee. Here, it may be noted that sensory inputs from the ocular surface regulate tear production and the blink response and are the basis of sensations of discomfort in DED.

**4.9.3.2. Sensory drive to lacrimal secretion.** Evidence suggests that in everyday conditions lacrimal secretion is driven by sensory impulses from corneal, cold-modality, thermoreceptors. Additionally, it appears that, in DED, surface desiccation, stimulating this subset of receptors in response to hyperosmolarity and surface cooling, determines the compensatory increase in lacrimal secretion, increase in blink rate and sensation of awareness of the eye, rising to the level of discomfort. This compensatory response to drying, occurring in MGD-related DED, where the lacrimal gland is healthy, may explain why some patients with DED experience epiphora and appear to have a “wet dry eye” [253].

Bilateral topical anesthesia causes a reduction in reflex tear secretion of up to two thirds [217], providing a value which is sometimes referred to as ‘basal tear secretion’. This is a reasonable term as long as it is recognised that it refers to a measurement made in particular environmental conditions and does not exclude inputs to lacrimal secretion from non-ocular sources. Jordan and Baum [217] proposed that lacrimal secretory rate was adjusted in response to environmental conditions and as mentioned, tear production is at its lowest after an extended period of eye closure,

as in overnight sleep [218]. Also, as Cross and Krupin observed in subjects with normal eyes, basal lacrimal secretion measured after topical anesthesia, (average Schirmer: 12.8 mm) falls markedly after 1 h of general anesthesia (to 1.2 mm), suggesting suppression of an input from higher central nervous centres [254]. Heigle et al. concluded, 'Perhaps lacrimal gland stimulation results from the sum of sensory inputs from the ipsilateral adnexal skin, cornea, nasal mucosa, contralateral eye and even central stimulation' [255].

There are other sensory inputs to the outflow pathway, from the nasal mucosa, retina and skin, which arise from pain and other noxious stimuli, such as intense cold or bright light), whose quantitative nature is unknown. When unilateral stimulation of the nasal passage on one side results in an increase in Schirmer wetting of both anaesthetised eyes, (the nasolacrimal reflex) this cannot be taken as evidence for a reflex response or of cross connections between trigeminal inputs from the nasal cavity to the superior salivatory nucleus. They could reflect a response of higher centres to the painful stimulus. Tearing in response to painful injury or retinal stimulation with bright lights could have a similar basis. Emotional tearing is under the control of higher centres [256] and there is a hypothalamic influence on autonomic centres in the brain stem [257]. In steady state conditions, most of the tear volume is derived from the lacrimal gland and its osmolarity therefore reflects that of the lacrimal secretion, modified by exposure to the environment when the eyes are open. A longer blink interval is predicted to result in a greater rise in the osmolarity of the pre-ocular tear film and meniscus than a shorter blink interval.

**4.9.3.3. Sensory drive to blinking.** Spontaneous blinks are thought to arise through the activity of a brainstem 'blink generator', modified by reflex inputs from the ocular surface and inputs from higher centres. Details of the blink generator are not fully known but it may lie in the pontomedullary reticular formation and the medullary reticular nucleus which serve both the facial nucleus and third nerve nuclei. Blink rate falls after bilateral, topical, ocular anesthesia [258], and also following LASIK surgery [259].

**4.9.3.4. The blink cycle and tear dynamics.** The tear film is regularly refreshed by spontaneous blinking [258,260] whose rate is adapted to environmental conditions and varies with personal behavior. Blinking plays a key role in tear dynamics by spreading, mixing, and distributing the tears and clearing cellular and other debris. The blink cycle consists of the blink itself (around 200–300 ms) and the blink interval, during which evaporative water loss occurs [261]. The blink rate is expressed in blinks per minute.

**4.9.3.5. The blink rate.** Wide variations in blink rate have been reported in normal adults, probably reflecting individual variation and the influence of environmental and experimental conditions. It is strongly influenced by mental state, attention, physical activity, eye exposure, and environment. Factors in the environment that are important are relative humidity, temperature and airflow over the eye. Blink rate is increased by low humidity, cold and high wind speeds.

In standard room conditions (eg. 22 °C with humidity of 40.0%), blink rate in normal adults ranges between 15 and 20 per min [261–263]. Blink rate increases in DED, where it is thought to play a compensatory role in refreshing the tear film more frequently [264,265]. Blink rate falls during a number of common visual tasks requiring mental concentration, and it is considered that the increased evaporative loss may act as a trigger for DED [261].

#### 4.10. Optical performance of the tear film

Wavefront aberrometry studies show that, in healthy eyes,

optical quality of the tear film decreases steadily during the blink interval. The period over which this occurs is shorter in DED, with the aberration minimum just preceding the breakup of the tear film [266].

#### 4.11. Tear osmolarity

##### 4.11.1. Introduction

Tear film osmolarity is a central factor in the pathogenesis of both ADDE and EDE. Tear hyperosmolarity resulting from decreased lacrimal flow or tear film breakup contribute to ocular surface damage both directly, and indirectly, through a cascade of inflammatory events. This hyperosmolar inflammatory environment favors corneal and conjunctival epithelial, and goblet cells apoptosis which further contributes to tear film instability. Inflammation induced by tear film instability and hyperosmolarity also contributes to neurogenic chronic inflammation and increased disease severity [267,268].

In subjects with normal eyes, in standard conditions, tear osmolarity, measured in lower meniscus samples, lies within narrow limits and is remarkably stable in healthy eyes [269]. Evaporation during the blink interval causes a measurable thinning of the tear film, and a consequent rise in tear film osmolarity is predicted [177]. Tomlinson reported a value of  $302 \pm 9.7$  mOsm/L based on data from several studies [270] and importantly, variation between right and left eyes is small ( $6.9 \pm 5.9$  mOsm/L) [271]. The narrow range of values in individuals reflects the influence of homeostatic mechanisms, with the blink interval, as the chief modifier of evaporation, likely determining the set point of tear osmolarity between the two eyes [79].

Mathematical modeling suggests that there is a small osmolar differential between the tears and menisci so that in the steady state, the osmolarity of the tear film is higher than that of the menisci [176]. This may relate to the ratio of the tear film thickness to its surface area, compared with that of the menisci, and to tear mixing and flow in the menisci in the early phase of the interblink interval [272]. Modeling considerations also suggest that in DED, this differential is greater. Thus a tear sample taken from the meniscus may under-estimate that of the tears over the surface of the eye and hence of the underlying tissues [176].

While the highest values for tear meniscus osmolarity measured in DED are below 500 mOsm/l, it is likely that levels achieved at the ocular surface are much higher than this, particularly at the site of tear film breakup. Begley and colleagues studied the relationship between tear film breakup and DED and have suggested that local fluctuations in the tear film thickness will induce hyperosmolarity "hot-spots" with significantly higher concentrations than the average tear value [273–275]. Liu et al. [276], compared the character and intensity of symptoms associated with tear film breakup with those induced by instilled hyperosmolar solutions. These studies indicated a threshold of 450 mOsm/l for the induction of symptoms, with a value of 800–900 mOsm/l required to mimic symptoms induced by tear film breakup, that is, far higher than that detected in the meniscus in DED patients. Recent mathematical modeling also predicts major spikes in osmolarity within regions of tear breakup [277–279].

Tear film thickness was studied by using the self-quenching of fluorescein (FL), the reduction of fluorescent efficiency with increasing concentration shown at high concentrations [280]. Close match between FL imaging and a mathematical model incorporating evaporation and osmosis predicted the osmolarity of the uniformly thinning tear film to be as high as 3000 mOsm. The peak values of osmolarity varied depending on the evaporation rate applied in the model. The mathematical model simulated osmolarity within and around areas of tear breakup yielding a peak

osmolarity value of approximately 1900 mOsm, close to modeling results of Peng et al. [279] (Fig. 4). These local spikes of hyperosmolarity within areas of tear breakup are considered to be a major source of repeated stress to the ocular surface.

#### 4.11.2. Tear osmolarity in dry eye

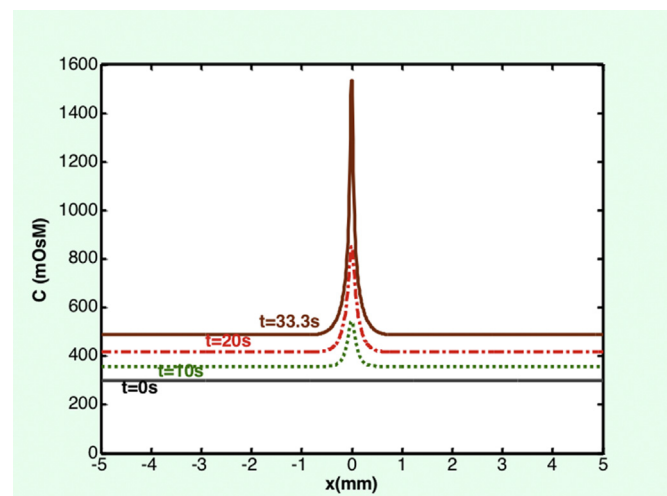
Tear osmolarity threshold values that discriminate a healthy eye from an eye with DED varies in the literature from 308 mOsm/L to 316 mOsm/L [269,270]. One reported reason for variability in tear osmolarity threshold values is tear film instability, a characteristic of the disease. Normal, mild/moderate, and severe dry eyes have average tear osmolarity values of approximately  $302 \pm 8$  mOsm/L,  $315 \pm 10$  mOsm/L and  $336 \pm 022$  mOsm/L, respectively [281]. Currently, 308 mOsm/L is proposed as a sensitive threshold for discriminating between normal eyes and those presenting with early stages of DED. Conversely, the 316 mOsm/L threshold would better discriminate between mild and moderate/severe DED. In addition to the absolute level of tear osmolarity, variability over time and, particularly, variability between the two eyes, can be a diagnostic indicator and appear to increase with the severity of DED [269,282].

#### 4.11.3. Factors influencing tear osmolarity

Tear osmolarity is influenced by the following intrinsic and extrinsic factors: i. Body hydration, ii. Tear film lipid layer (TFLL) characteristics, iii Palpebral aperture width, iv. Blink interval, v. Tear film stability and, vi. Environmental conditions.

#### 4.11.4. Body hydration

The tears on waking are slightly hypotonic, their tonicity rising over the course of the day, due to evaporation from the tear film. There is a positive relationship between whole body hydration, measured as plasma osmolarity and tear osmolarity and both are raised in patients with DED. Also, tear osmolarity follows plasma osmolarity in subjects with imposed systemic dehydration [283–285]. Consequently measurement of tear osmolarity has been proposed as a possible surrogate for plasma osmolarity, of potential use in the rapid detection of dehydration in the elderly or in sports medicine [283].



**Fig. 4.** Predicted evolution of a spike of hyperosmolarity during an extended blink interval based on modeling considerations. Surface osmolarity increases from 300 mOsm to 545 and 850 after 10 and 20 s, respectively, and skyrockets to 1534 mOsm after a 33-s interblink corresponding to tear-film breakup. (from Peng, C. C., et al. (2014). "Evaporation-driven instability of the precorneal tear film." *Advances in colloid and interface science* 206: 250–264. — with permission) [279].

#### 4.11.5. The tear film lipid layer

The rate of water loss from the eye is influenced by the quality and thickness of the TFLL. Expression of meibum in normal eyes leads to thickening of the tear film lipid layer [286] and to a reduction of evaporation in both healthy individuals and patients with DED [287]. When the quality or integrity of the TFLL is deficient, as judged by interferometry, evaporative loss may be increased and tear osmolarity increased [175]. A similar outcome may be predicted when TFLL spreading is retarded by a marked aqueous tear deficiency [194].

#### 4.11.6. Palpebral aperture width

As would be anticipated, evaporative loss from the eye is influenced by tear film area. Tsubota and Nakamori examined the effect of gaze position on evaporation rate (at 40% humidity and a blink rate of 30 per min) and showed that evaporative loss is 3.4 and 2.5 times greater when looking up and straight ahead than when looking down, not only per eye, but also per unit area of the ocular surface [288], perhaps suggesting that as the area to be covered increases, the TFLL is thinned.

#### 4.11.7. Blink interval

The tear film is refreshed by blinking [258] and the blink rate is adapted to environmental and social circumstance and to personal behavior. The blink interval, and hence the blink rate, is a determinant of tear osmolarity, with the expectation that prolongation of the interval (a slower blink rate) will raise it. Blink behavior may be constrained while performing selected visual tasks in ways that influence tear stability and evaporative loss. A fall in blink rate has been documented during everyday visual tasks, such as working at a video display terminal, reading in downgaze [289], operating monitor-based and handheld video games, and performing surgery [290,291]. In these situations, both gaze position and difficulty of the visual task are determinants of blink rate.

The effect of a fall in blink rate on evaporation stress while performing downgaze tasks are difficult to predict on basic principles. Both blink rate and palpebral aperture area are decreased, the former tending to increase and the latter to decrease tear evaporation. Also, when viewing computers with the eyes in the primary position, the head may tilt backwards, thus narrowing the palpebral aperture.

#### 4.11.8. Tear film breakup

The importance of a stable tear film for retinal imaging is well known [292], and many approaches are used to study its influence on visual function. Tear film breakup within the blink interval is a cause of visual degradation and its character and time course have been studied in detail in contact lens wearers [293]. The effect of precorneal tear film breakup on vision is due to variations in film thickness, rupture of the film and, in DED, exposed epithelial irregularities at the site of breakup and the presence of light-scattering, epithelial opacities.

Although visual acuity is the standard clinical measure of visual function it does not provide a full account of visual performance and broader measures of visual function are used, such as contrast sensitivity [292], glare disability [294], and scatter index [295], all of which have been shown to be disturbed in DED [296]. A functional measure of visual acuity has also been developed [297,298].

Tear film breakup time is the most frequently used measure of tear film stability and becomes of pathological importance when it falls below the blink interval. In most healthy individuals, the tear film is extremely stable and values reported for TBUT are well beyond the normal blink interval [299]. However, tear breakup in the blink interval does occur in some healthy individuals.

The relationship between the blink interval and breakup time

can be captured as the Ocular Protection Index (OPI), the breakup time divided by the blink interval [300]. An OPI of  $\geq 1$ , indicates that the breakup time exceeds the blink interval and therefore that the eye is protected from desiccation throughout the blink cycle. An OPI of  $< 1$  indicates that breakup is occurring within the blink interval and that the eye is exposed to damaging desiccation. In early DED, OPI is initially  $> 1$  and nears 1 as disease severity increases, independent of the cause of the DED. Later, as the disease progresses and the OPI falls below 1, hyperosmolarity is amplified locally in the epithelium subjacent to the breakup by the local increase in evaporation. For a given blink interval, the lower the OPI, the greater the imposition of evaporative hyperosmolarity at the ocular surface. In the regions outside the breakup, osmolarity is also increased, by diffusion and tear mixing, but to a more modest level.

It is evident that the measurement of tear osmolarity in tear meniscus samples underestimates the level of hyperosmolar stress delivered to the ocular surface in an individual dry eye, and the Subcommittee identified a need to develop techniques for the measurement of osmolarity at the tissue level. Some success has been reported in the mouse, measuring surface cation levels by fluorescence ratio imaging [301] and attempts have been made in the clinical situation, measuring tear [302] and tissue conductivity [303], but currently no clinical instrument is available.

Local tear instability, initiated by a loss of ocular surface wettability, such as occurs in xerophthalmia and chronic topical preservative use, can be an independent starting point for tear hyperosmolarity and DED, acting through the mechanism described above. The resulting DED was earlier referred to as an “extrinsic” form of EDE, but a better term is ocular surface-related EDE.

#### 4.11.9. Effect of ambient environment

Certain environmental conditions increase evaporative loss and are risk factors for DED. Evaporation is increased in conditions of low humidity and increased airflow over the surface of the eye [261,304,305]. Such conditions may be combined and may also occur in natural, outdoor conditions. The effect of the environment on evaporation is the basis for providing goggles or water-conserving spectacles for the prevention or treatment of DED states. Exposure to low humidity environment for as little as 90 min has been shown to increase blink rate, ocular discomfort and presence of cytokines and matrix metalloproteinases (MMPs) in tears [264,306].

#### 4.12. Corneal epithelial barrier disruption

##### 4.12.1. Matrix metalloproteinases and EMMPRIN

Disruption of the epithelial barrier at the ocular surface is a characteristic feature of DED. Exposure of the corneal epithelium to increased osmolarity promotes inflammation, abnormal differentiation, programmed cell death (e.g. apoptosis) and accelerated desquamation [307], with early activation of mitogen activated protein kinase (MAPK) and nuclear factor  $\kappa$ B (NF $\kappa$ B) stress signaling pathways [308,309]. These pathways initiate a cascade of events, including transcriptional activation of genes encoding inflammatory matrix metalloproteinases (particularly MMP-9) and proapoptotic factors [310–312].

Matrix metalloproteinases (MMPs) are proteolytic enzymes involved in wound healing and inflammation, which play a key role in DED pathogenesis by disrupting intercellular epithelial tight junctions, leading to a breakdown of the epithelial barrier. Expression and production of MMPs –1, –3, –9, and –13 by human corneal epithelial cells correlates positively with increasing osmolarity [310–312], acting, at least in part, through the c-Jun N-terminal kinase (JNK) pathway [308]. This activity is inhibited by

doxycycline [313]. Among these proteases, MMP-9 is considered to be of central importance in the response to hyperosmolar stress [311,314]. Occludin, a component of the tight junction is a known substrate of this protease and, in a murine model of DED, increased tear levels of MMP-9 were associated with a loss of epithelial barrier function and of surface epithelial regularity [314,315]. Increased MMP-9 levels were also observed in the tear fluid of patients with DED, the concentration of MMP-9 in tears correlating with DED severity. Therefore its quantification has been proposed as a biological marker of disease activity [316–318]. It is relevant that MMP-9 knockout mice exposed to desiccating stress are more resistant to alterations of the corneal epithelial barrier than wild-type animals [315].

The membrane-spanning molecule EMMPRIN (Extracellular matrix metalloproteinase inducer; also termed CD<sup>+</sup>147) is an inducer of MMP expression that participates in the pathogenesis of DED through MMP-mediated cleavage of occludin [314]. The molecule is also involved in the pathogenesis of corneal ulceration, stromal melting and stromal remodeling [314,319]. EMMPRIN expression is increased at the ocular surface in DED patients and correlates with MMP-9 levels in tears and in corneal epithelial cell cultures [314]. Increased osmolarity or addition of recombinant EMMPRIN in corneal epithelial cell conditioned medium was responsible for increased production of both EMMPRIN and MMP-9 and resulted in the disruption of epithelial junctions through the cleavage of occludin. Conversely, selective inhibition of EMMPRIN by siRNA in this system, leads to the inhibition of both MMP-9 induction and epithelial barrier disruption. Moreover, an inverse relationship between the distribution of occludin and EMMPRIN as a function of differentiation and stratification of epithelial cells, both in culture and in the stratified corneal epithelium *in vivo*, suggests a physiological function for this molecule in epithelial cell barrier homeostasis. Interestingly, unpreserved artificial tears have been shown to decrease EMMPRIN cell surface expression in patients with DED, and addition of cyclosporine to corneal epithelial cell conditioned medium, inhibited cell surface expression of EMMPRIN selectively, in an *in vitro* model of ocular surface preservative toxicity [314,320].

Galectin-3 is required to maintain the barrier function of the epithelial glycocalyx [321]. Its levels are increased in the tears of DED patients, associated with increased levels of MMP-9 [155]. In an *in vitro* corneal epithelial cell system, the cell–cell detachment and redistribution of occludin induced by exogenous galectin-3 is considered to involve the induction of MMP-9, a process dependent on the clustering and interaction of galectin-3 with EMMPRIN on the cell surface [321].

#### 4.13. Frictional events at the surface of the eye

Friction between the lids and globe as they move in relation to each other during blinking and eye movements is considered to be a cause of symptoms in DED and its sources have been reviewed by Pult [322]. Frictional symptoms will only occur at times of such relative movement between the lids and globe.

When two apposed surfaces are in relative motion the degree of friction between them depends on the nature of the surfaces, the speed of movement, the load applied and the presence of lubrication. Where the surfaces are separated by a fluid layer, lubrication is referred to as hydrodynamic, whereas where they are in direct contact, this is termed *boundary lubrication* [101,323–325]. An intermediate, mixed state also exists [326]. Suitable lubrication can diminish the degree of damage or wear engendered by frictional forces.

#### 4.13.1. Boundary lubrication

Boundary lubrication usually applies when the relative motion between apposed surfaces is slow, which, for the ocular surface, is during the blink interval when the eyes are stationary, or directed at slow-moving objects. It probably also occurs at the beginning, end and return points of the blink cycle [325]. At this time the epithelial glycocalyxes of the apposed tarsus and globe are in contact, with a variable amount of the mucoaqueous phase intervening. In these circumstances, the cross-linked mucin exodomains of the healthy glycocalyx act as hydrophilic polymer brushes, which greatly lower the coefficient of friction between the apposed surfaces of lid and globe and minimise frictional damage [327,328].

##### 4.13.1.1. Lubricin

Lubricin, or proteoglycan 4, is an amphiphilic glycoprotein expressed by synovial and cartilage cells of the joints, as well as in the major viscera and in muscle, tendon and bone and the eye and brain [82]. In the joints, cooperating with hyaluronic acid, it acts as an efficient boundary lubricant, reducing friction between the apposed joint surfaces [82,329–331]. In other tissues it may serve other physiological functions involving cell proliferation and attachment and matrix binding.

In the eye, lubricin is expressed by trabecular meshwork cells and by the corneal and conjunctival epithelium. Lubricin messenger RNA is also present in lacrimal and meibomian glands [82,330]. Laboratory studies suggest that lubricin may function as a boundary lubricant between the apposed surface of the cornea and lid wiper region [82]. Absence of lubricin in PRG4 knockout mice is associated with a significant increase in corneal fluorescein staining. Recombinant lubricin has been synthesized successfully [332] and has recently been tested in a clinical trial for the treatment of DED [333].

#### 4.13.2. Hydrodynamic lubrication

Hydrodynamic lubrication applies in conditions of high relative velocity where a fluid layer separates the apposed surfaces. For the tarsus and globe, this occurs during the blink and during saccades. During the downphase of the blink, the upper lid moves chiefly in a vertical direction but also slightly nasally, across the exposed globe with an average velocity of 17–28 cm s<sup>-1</sup> and a maximum velocity of around 40 cm s<sup>-1</sup> [322,334]. The lower lid moves nasally, about 4.5 ± 0.9 mm and slightly upwards. The width of the palpebral aperture is also reduced [322]. During saccades, movement is between the tarsus and the unexposed surfaces of the globe. In vertical gaze there is more limited relative movement between the upper lid and globe.

The relationship between friction and velocity, load and viscosity, is described by the Stribeck curve [200,335,336]. This empirical relationship was originally characterized for steel journal bearings using oil lubrication, with the friction coefficient on the y axis and the Hersey number (viscosity\*sliding velocity/normal pressure) on the x axis. Many biological surfaces are soft, complex, heterogeneous hydrated materials (such as the cornea and lid tissue) and therefore may not follow classic Stribeck behavior [337], yet the curve can still provide a framework for discussion and interpretation.

According to the Stribeck curve, where tear volume is sufficient, then friction during blinking depends on the rate of relative movement of the apposed surfaces and the tear viscosity. Given that  $S = (v \cdot \eta)/t$  where  $S$  = shear friction,  $v$  is the velocity of the upper lid during the blink,  $\eta$  is the viscosity of the tears and  $t$  is the thickness of the tear layer between the apposed surfaces.

The above equation suggests that for a given tear viscosity, the thicker the tear film, the lower friction will be. For a Newtonian fluid whose viscosity is independent of shear rate, hydrodynamic

friction increases with increasing viscosity and this may be relevant to events in DED (see below), but normal tears behave as a non-Newtonian fluid [338–340] whose viscosity falls with increasing shear rate (i.e. it shear-thins), so that this consideration does not apply. Therefore, according to this relationship, acknowledging that the Stribeck curve classically applies to non-porous stiff materials, with friction during blinking/saccades depending on rate of relative movement and tear viscosity, when tear volume is sufficient the coefficient of friction between lid and globe may be assumed to be low. It is suggested that there is a rapid transition from brush-to-brush or boundary lubrication, to hydrodynamic lubrication with increasing velocity during the blink [322]. The lid margin profile may also be important in the transition from boundary to hydrodynamic lubrication [322].

Friction is greatly increased in DED states due to a failure of lubrication [341], with the loss of mucin gel and glycocalyx or, in ADDE, of fluid volume. This may cause damage to specific site as in lid wiper epitheliopathy (LWE) [342], parallel conjunctival folds, (LIPCOF) [343], and superior limbic keratoconjunctivitis (SLK).

#### 4.13.3. Frictional forces at the lid-wiper region of the lid

The lid-wiper region of the lid was originally described as that portion of the upper eyelid that comes into intimate contact with the globe and wipes over it during blinking [342,344]. This role had earlier been conceived by Parsons [345] and by Ehlers [323], based on the recognition of a 'stratified squamous' epithelium at this site. It is now recognised to be a feature of both the upper and lower lid [346].

The upper lid wiper consists of an elevated strip of marginal conjunctival epithelium, 100 µm in initial thickness, varying in width from 0.3 to 1.5 mm and extending the full length of the lid margin at the level of Riolan's muscle. According to Knop it is composed of a stratified cuboidal epithelium [40], which is closely applied to the globe during the blink [326,347] and is probably the closest region of contact between the upper, and presumably, the lower, lid and globe. In the upper lid, the tarsal mucosa lying proximal to this zone, separated from the globe by a mucoaqueous layer of unknown thickness, (within 'Kessing's space') [36,97] is thought to be less closely applied. The presence of both goblet cells and goblet cell crypts in the lid wiper epithelium [40,101] is presumed to provide a local, mucinous lubrication system at this point of primary contact, of importance during blinking and to a lesser extent during eye movements where the forces applied are lower.

#### 4.13.4. The consequences of shearing forces at the ocular surface

At a conservative estimate, considering a blink rate of 12 times a minute over a 16 h day, an individual would blink 11 thousand times in the course of a day and, assuming a palpebral aperture of 10 mm in height, the lid wiper would have travelled a distance of at least 100 m over the surface of the cornea [101]. Notwithstanding the presence of a lubricating system of high quality, this is a source of shear stress at the ocular surface. It is presumed to play a role in epithelial desquamation, in the punctate epithelial staining found at the ocular surface in the normal eye and in the enhanced punctate epithelial staining of DED. Additionally, as noted, it contributes to other clinical features of DED such lid wiper epitheliopathy, LIPCOF and SLK, any of which may occur, in lesser degree, in the absence of DED.

#### 4.14. Epithelial desquamation

The following scenario, referring to the cornea, may be proposed for the shedding of epithelial cells. A similar process is assumed for the conjunctiva [348]. Epithelial cells arise by the division of stem cells at the corneal limbus and are increased in number by division

of *transient amplifying cells*, in the periphery [349]. Newly formed cells undergo terminal differentiation as they migrate centripetally and to the surface and after a period of residence, undergo a process that leads to shedding, which may be preceded by apoptosis [350]. Epithelial desquamation involves uncoupling of layer 1 cells from neighbouring cells, with a loss of junctions, including tight junctions and adherens junctions, and dissolution of the apical glycocalyx. At some point, having lost adherence to surrounding cells, the cell destined for shedding is easily displaced by frictional forces. Its place is taken by a younger cell, already equipped with a maturing glycocalyx, which is rapidly integrated with neighbouring cells by means of tight junction formation, thereby restoring the functional integrity of the surface. It is this process that most likely explains the infrequent occurrence of punctate epithelial staining in the normal eye.

#### 4.14.1. *Physiological punctate epithelial staining*

The subject of punctate epithelial staining has been recently reviewed [348]. A low degree of punctate epithelial staining is a regular finding on the normal cornea and conjunctiva after the instillation of dyes such as fluorescein, lissamine green and rose bengal and may be regarded as a physiological phenomenon. Based on reports in the literature it occurs with a frequency of 4–78% [351], varying with methods of assessment, particularly with volume and concentration of dye instilled and the period of observation. The number of staining points increases with time. Punctate epithelial staining on the cornea and conjunctiva, with a characteristic horizontal, interpalpebral pattern, is a diagnostic feature of DED.

In normal subjects, a proportion of corneas show a low level of punctate staining immediately after fluorescein instillation [351–356]. A 'clinically significant' grade of fluorescein staining has been reported to occur in about 12% of non-contact lens wearers [357–359] but the figure rises if 'clinical significance' is ignored – eg. from 37% to 58%, in the study of Korb [353]. Similarly, in a study of normal subjects (median 22 years; range 18–50 years) after the instillation of fluorescein from a Fluoret<sup>®</sup>, 79% of subjects showed some degree of corneal staining. Less information is available about the conjunctiva.

Norn reported the frequency of punctate epithelial staining in normal corneas, read at 1–2 min following the instillation of a 10 µl of 0.125% fluorescein. Punctate staining was present in 4% of subjects under 40 years of age, increasing to 20% above the age of 50 years, after which the frequency became stable. The mean frequency for the group overall (n = 411 corneas) was 17% [360]. Similarly, the number of dots per cornea rose with age, although in most subjects the number of dots per cornea was small - only 1% of subjects showing over 100 dots per cornea, compared to 35% with over 1000 staining dots in patients with DED (Table 4).

In general, the prevalence of staining and dot frequency, increases with dye concentration [360], with time after drop instillation (Korb and Korb 1970) and with age of subject [360,361]. Caffery and Josephson showed that the regional pattern of corneal staining was individual to the subject, similar in fellow eyes, and, importantly, varied from day to day [356], which was confirmed by Schwallie et al. [362] They concluded that variation might relate to the natural turnover of the epithelium.

The physiological occurrence of corneal and conjunctival staining suggests that in clinical trials, for instance of DED therapies, zero corneal staining is not a reasonable criterion to define recovery to full corneal health. Also, the time-dependent staining of the normal corneal epithelium and dependence on instilled concentrations, emphasizes the need for standardization of staining routines to assess ocular surface damage.

#### 4.14.2. *Mechanism of punctate epithelial staining in normal and in dry eyes*

The mechanism that determines punctate epithelial staining has been in debate for over half a century and has been addressed by several recent reviews [79]. There appears to be no direct evidence that punctate dots of stain represent pools of dye lying within spaces left by shed cells, hence the term punctate epithelial erosion is not appropriate [363–365]. Rather, it seems that each dot of stain represents the uptake of dye into a surface epithelial cell.

#### 4.14.3. *Staining in the normal eye*

Epithelial cells are shed daily from the ocular surface and about 75% of collected cells are corneal [366]. Cells are shed in a diurnal pattern, with more cells shed in the morning and the latter part of the day [367]. About 23% are ghost cells, lacking nuclei, considered to be at a late stage of cell differentiation [368,369]. This fits in with an earlier study showing the presence of both viable (calcein-positive only) and nonviable (ethidium-positive only) epithelial cells, as well as an intermediate cell type that stained with both calcein and ethidium [367].

The vast majority of layer 1 epithelial cells do not take up dye, whereas shed epithelial cells, trapped in the fornical mucus thread, stain with rose Bengal [203], as do immature human limbal corneal epithelial cells grown in culture [370,371]. Similarly, cultured rabbit corneal epithelial cells stain avidly with fluorescein [372,373]. Argueso et al. resolved this issue by demonstrating that exclusion of rose bengal from entry into surface epithelial cells in the intact eye, depends on the presence of a mature glycocalyx expressing MUC1 and MUC 16 mucins, crosslinked by galectin-3 [128,134,148]. The mature glycocalyx forms a barrier to transmembrane dye entry into the layer 1 epithelial cells, while entry into the paracellular space is restricted by intercellular, tight junctions. Bandamwar et al. [350,374] have presented evidence that staining cells are those undergoing apoptosis while preparing for shedding. Such cells possess a defective glycocalyx layer, which is permeable to dyes in clinical use. Once shed, all epithelial cells are incompletely clad with glycocalyx and hence stain readily.

It is hypothesized that the permeability of a cell that is preparing for shedding, increases over time, due to chemical and structural changes in its glycocalyx, so that those cells that are just about to be shed take up stain almost immediately whereas those that are at an earlier stage of preparation, take up stain more slowly. This is presumed to be the basis of the effect of dye concentration or of period of observation, on the frequency of physiological staining dots.

## 5. The pathology of dry eye disease

These introductory remarks are intended to arm the reader to understand the events responsible for the many forms of DED.

### 5.1. *Introduction*

The TFOS DEWS [1] report confirmed tear hyperosmolarity, along with tear instability, as the core drivers of DED. This allowed two major subtypes to be defined, EDE, where tear hyperosmolarity is the result of an excessive evaporation from the tear film in the presence of normal lacrimal function and ADDE, where hyperosmolarity results from a reduced lacrimal secretion in the presence of a normal rate of tear evaporation (Table 5). The tear film lipid deficiency that accompanies MGD is cited as a typical cause of EDE and the reduced tear secretion due to lacrimal gland damage in age-related DED provides a typical example of ADDE. It was recognised that these subtypes of DED may coexist and this is the case in Sjögren syndrome where a lacrimal deficiency frequently

**Table 4**  
Micropunctate staining dots per cornea after instillation of fluorescein.

Dots per cornea	Percent with 0.125% fluorescein	Percent with 1.0% fluorescein
Zero	83	27
1–4	9	16
5–9	4	2
10–25	3	4
25–99	1/2	0
100–999	1	16
≥1000	0	35

Percentage of normal corneas showing a given number of micropunctate staining dots per cornea, after instillation of 10 ml of either 0.125% or 1% fluorescein (in combination with 1% rose bengal) (n = 411, including fellow eyes). Staining was read more than 1–2 min following dye instillation (From references 348, 360).

coexists with MGD [375,376,1201]. Also, in any form of cicatricial conjunctivitis, DED may be secondary to a lacrimal tear deficiency, a tear lipid deficiency and loss of ocular surface wettability.

Other forms of hybrid DED may also be conceived, in which organic disease of one type may be combined with a functional form of DED of another type [207]. For example in severe EDE, loss of corneal sensitivity could remove the compensatory drive to lacrimal secretion and lead to a secondary, functional aqueous deficiency. Or in ADDE, a severe reduction in tear film thickness could impair TFL spreading and give rise to a secondary, functional EDE. Additionally and importantly, it may be observed that in any form of DED, once tear breakup occurs within the blink interval, an additional evaporative component is added to the dry eye, regardless of the initiating cause. A consequence of this is that a dry eye that is initiated by a lacrimal tear deficiency becomes an ADDE + EDE as it evolves. It follows that, where comparisons of tear evaporation rate are made between forms of DED classically defined as ADDE and EDE, the OPI should be taken into account. This also has implications for therapy and for subgroup selection and analysis in clinical trials. This Subcommittee recommends that the terms EDE and ADDE be retained to describe the *initiating* basis of a dry eye but that it should be recognised that with progression any form of DED may take on additional evaporative features.

It should be kept in mind that, in a sense, all forms of DED are evaporative, since without evaporation, tear hyperosmolarity cannot occur. Consequently, environment and personal behavior are contributors to ocular surface hypermolarity, including external factors such as ambient humidity, temperature and wind speed and personal factors such as blink rate and lid aperture size, gaze position and the influence of systemic medication on tear secretion. The Subcommittee discussed the term, 'hyperevaporative dry eye' as a better way of indicating the role of increased evaporation in DED.

A major contribution of the TFOS DEWS report [1] was the proposition that every kind of dry eye, however initiated, enters a final common pathway in which tear hyperosmolarity and a chain of inflammatory events create a Vicious Circle that perpetuates the DED state [377]. According to this approach, *any etiology of DED will have one or more entry points* into the vicious circle. The concept of the vicious circle is illustrated in (Fig. 5) and is elaborated in the text that follows.

### 5.2. The vicious circle of dry eye

In the simplest model of DED, with tear hyperosmolarity as its starting point, the pathological process is propagated by a chain of events that lead to ocular surface damage (Fig. 5). Initially this gives rise to symptoms and compensatory responses, but it also generates inflammatory responses that ultimately lead to chronic

ocular surface damage and self-perpetuated disease [377].

This may be summarised as follows:

As noted earlier, tear hyperosmolarity stimulates a cascade of events in the epithelial cells of the ocular surface, involving MAP kinases and NFκB signaling pathways [311] and the generation of inflammatory cytokines (interleukin-1 [IL-1α; IL-1β]; tumor necrosis factor-α [TNF-α]) and proteases, such as MMP9 [378]. These activate and recruit inflammatory cells to the ocular surface which become an additional source of inflammatory mediators [379]. Such mediators, acting with tear hyperosmolarity itself, lead to a reduced expression of glycocalyx mucins, to apoptotic death of surface epithelial cells [380] and to loss of goblet cells. Hyperosmolarity also induces corneal epithelial cell death through non-apoptotic processes [62]. Goblet cell loss is a feature of every form of DED [381,382], reflected by reduced tear levels of MUC5AC [383,384]. Altered expression of glycocalyx mucins is a likely basis for ocular surface staining in DED and by compromising ocular surface wetting, leads to early tear film breakup. This amplifies or initiates ocular surface hyperosmolarity, which completes the vicious circle and establishes the mechanism that perpetuates the disease.

It has been emphasized by Baudouin et al. that the vicious circle offers *entry points* for any cause of DED [385]; tear hyperosmolarity need not be the starting point. Thus the chain of events leading to tear film instability may be initiated by several different disorders, such as ocular surface inflammation due to allergic eye disease, topical preservative toxicity and loss of conjunctival goblet cells or altered mucin expression, due to xerophthalmia.

### 5.3. Compensatory events in dry eye

It is inherent to our current understanding of DED that exposure of the ocular surface to desiccating stress sets up a compensatory, secretory tear response, via the Lacrimal Functional Unit that tends to offset a rise in tear osmolarity and slow disease progression. As summarised in the Pain and Sensation S/C report both tear hyperosmolarity and surface cooling may put this in train. The cold modality fibres of the cornea are stimulated by hyperosmolarity and could both increase the secretory drive to the lacrimal gland and lead to an increased blink rate. Evaporative cooling in EDE or in relation to early tear film breakup [279,386]. could add to this sensory drive. The finding of a reduced threshold to sensory stimulation in some DED patients [387], could amplify these responses. Other authors have reported a decreased corneal sensitivity in DED [388,389], which may imply that, as DED progresses in severity, corneal sensation becomes impaired. In keeping with this, a number of studies have reported a reduction in subepithelial nerve bundle density in DED [390]. Such a sequence could impact unfavourably on compensatory responses and could contribute to discrepancies between symptom intensity and objective signs of DED. However, this possibility, which would be important to our understanding of DED progression, has not been addressed in long-term studies.

### 5.4. Symptoms

Any symptomatic disease goes through a subclinical phase in which the features of the disease are not obvious and the patient is symptom free. DED is no exception. (see Diagnostic Methodology Subcommittee report) But the burden of DED for the patient relates to symptoms and there is now a greater understanding of their causes. DED affects both vision and comfort of the eye. Potential sources of symptoms in DED are listed in Table 6.

There is evidence to support a direct role for hyperosmolarity as one basis for ocular discomfort in DED. As noted, instillation of



**Table 5**  
Causes of dry eye disease.**AQUEOUS-DEFICIENT DRY EYE (ADDE)**

Sjögren Syndrome Dry Eye (SSDE)
- associated systemic diseases
Rheumatoid arthritis
Polyarteritis nodosa
Systemic lupus erythematosus
Wegener granulomatosis
Systemic sclerosis
Primary biliary cirrhosis
Mixed connective tissue disease
Non- Sjögren Syndrome Dry Eye (NSDE)
Intrinsic Lacrimal Gland Deficiency
Lacrimal gland ablation
Congenital alacrima
Triple A syndrome
Age-related ADDE dry eye
Inflammatory and Other Lacrimal Gland infiltration
Sarcoidosis
Lymphoma
Viral Infection
Radiation Injury
Lacrimal Gland Obstruction
Cicatricial conjunctivitis
GVHD
Stevens-Johnson Syndrome/TEN
Mucous Membrane Pemphigoid
Cicatricial pemphigoid
Pemphigus
Trachoma
Chemical Injury
Hyposecretory States – Failure of the Lacrimal Functional Unit
Reflex Afferent Block
Topical anesthesia
Trigeminal Nerve Injury
Refractive Surgery
Neurotrophic Keratitis
Secretomotor Block
Parasympathetic damage
Pharmacological Inhibition
Combined Afferent and Efferent Block
Familial Dysautonomia
Other Disorders
Meige Syndrome
Diabetes Mellitus
Pseudoexfoliation
<b>EVAPORATIVE DRY EYE</b>
Meibomian Gland Diseases
Lid-Related
Meibomian Gland Dysfunction (MGD)
Primary
Meibomian Seborrhea
Obstructive MGD
Cicatricial/non-Cicatricial
Secondary to local disease
Anterior blepharitis
Ocular surface inflammation
Contact Lens Wear
Secondary to systemic dermatoses
Rosacea
Seborrheic dermatitis;
Atopic dermatitis
Ichthyosis;
Psoriasis
Secondary to Chemical Exposure
13-cis retinoic acid
Polychlorinated biphenols
Antiandrogens
Genetically Determined Meibomian Gland Diseases
Meibomian Agenesis and Dystichiasis
Anhydrotic ectodermal dysplasia
Ectrodactyly syndrome
Epidermolysis Bullosa
Ichthyosis follicularis
Turner syndrome;
Disorders of Lid Aperture, Congruity, Dynamics
Blink-related

**Table 5 (continued)**

Parkinson's Disease
Ocular Surface-Related Evaporative Dry Eye
Allergic Eye Disease
Vitamin A Deficiency
Short Breakup Time Dry Eye
Iatrogenic Disease

hyperosmolar drops causes pain of an intensity related to the level of hyperosmolarity, but at levels far higher than that detected in tear meniscus samples in DED patients [276]. Modeling considerations have suggested that the levels of hyperosmolarity generated at the site of tear breakup are far higher than in the tear meniscus [279]. There is evidence too, that tear hyperosmolarity is initiated as the tear film thins, and is amplified at the time of tear breakup [391]. Additionally, several of those inflammatory mediators, which have been demonstrated in the tears and ocular surface in DED, are known to be algasic compounds, including various prostanoids, cytokines and neurokinins (see the Pain and Sensation Subcommittee report for further details). The loss of lubrication between the globe and lids in DED has been suggested as a source of friction-related symptoms, including a reduction in tear volume in ADDE, loss of goblet cell gel mucin, degradation of glycocalyx mucin [218] and loss of the boundary lubricant, lubricin [82]. Filamentary keratitis is a particular source of pain, attributed to the drag of filaments on nociceptor endings at the base of the filament during blinking. A similar process may be responsible for symptoms of discomfort associated with LIPCOF [343]. The basis for pain associated with lid wiper epitheliopathy is assumed to be due to hypersensitivity over the affected region of the lid wiper and the region of the keratopathy. In the healthy eye, this region of the lid margin has a mechanical sensitivity similar to that of the central cornea [250].

Thus tear hyperosmolarity is but one of the potential sources of discomfort in DED, another reason why the levels of tear osmolarity measured in DED patients with chronic pain may not always be significantly different from the osmolarity of asymptomatic patients [392].

Hypersensitivity (reduced threshold to stimulation) of corneal nerves in DED patients may also explain the occurrence of ocular discomfort at lower levels of tear osmolarity, due to exposure of corneal nerve endings with loss of the epithelial barrier [267,387,393].

Instillation of hyperosmolar drops within the ranges of osmolarity found in DED patients was shown to increase the sensitivity of the cold nociceptive neurons and to induce DED signs in a rat model. In this rat model, these nociceptors, which normally require more than 2 °C cooling, were activated by less than 1 °C cooling of the corneal surface when pretreated with hyperosmolar fluids [394]. This phenomenon may explain the cooling-induced discomfort and pain reported by DED patients. Upregulation of TRPM8 channels or control of the voltage-gated potassium channels (Kv1.1) may be involved in this process [395]. Both channels are well-established cooling sensors that can be regulated by a hyperosmolar stimulus [396].

### 5.5. The ocular targets of dry eye disease

Regardless of how DED is initiated, its clinical consequences at the ocular surface are independent of etiology. These may include punctate epitheliopathy, filamentary keratitis, superior limbic keratitis, goblet cell loss, modification of the epithelial glycocalyx, LIPCOF, changes to Marx's line and MGD itself (Table 7). These are discussed below:

### 5.5.1. The cornea

#### 5.5.1.1. Punctate epitheliopathy and staining in dry eye disease.

Evidence suggests that noxious influences at the ocular surface in DED lead to increased epithelial cell death (e.g. apoptosis) and increased epithelial shedding and turnover. It is likely that increased friction contributes to the increased shedding. No formal measurements of increased shedding or turnover have been made in DED and this would be of value.

Tabery has shown that punctate corneal epithelial staining in DED can be explained by the uptake of dye directly into individual epithelial cells and that fluorescein is taken up into the same cells that take up rose Bengal [397,398]. Several studies suggest that staining cells on the cornea and conjunctiva have a defective glycocalyx, including a deficiency of MUC 16, [399–401] and in bullous keratopathy, too, superficial exfoliation and staining is associated with breaches in MUC16 [402]. Komuro et al. found, in patients with superior limbic keratoconjunctivitis, that areas of conjunctiva showing positive staining with rose bengal, had no galectin-3 expression, whereas in healthy regions showing rose bengal exclusion, galectin-3 was expressed normally [403].

The staining of individual, layer 1, corneal epithelial cells in DED states is thus attributed to the diffusion of dye across the defective glycocalyx of apoptotic cells, prior to shedding. The staining of small clusters of surface cells may have a similar explanation, but an additional possibility is that the dye enters the paracellular space around a cell that is about to be shed, across a defective tight junction and spreads into neighbouring cells across their plasma membranes, ie. by transmembrane spread [79]. Intercellular spread of dye between neighbouring cells via gap-junctions is less likely in the superficial epithelium since these are absent from layer 1 in the human cornea and connectivity is limited in the second layer [404]. An alternative view has been expressed [363].

#### 5.5.1.2. The pattern of staining in dry eye.

Epithelial staining of the exposed cornea and conjunctiva in DED has a characteristic horizontal, inter-palpebral distribution, which is of diagnostic value (Fig. 6). There has been a longstanding interest in its basis, particularly in relation to hyperosmolar hot-spots generated in the blink interval. McMonnies [405], and others [406] have emphasized the role of partial blinking in extending the period of lower globe exposure to desiccating stress, emphasizing that the period of exposure will be a multiple of the number of partial blinks that occur in sequence. Partial blinking is common, both in normal subjects and dry eyes. A figure of up 22% was reported in one study of normal eyes [407] and may comprise from 20% to over 50% of all blinks [408–410]. Jansen et al. noted that in subjects engaged in tasks requiring a high degree of visual concentration, both the number of incomplete blinks and the interblink interval increased [290].

The region of meniscus induced thinning (MIT), corresponding to the position of the 'black line' in the fluorescein-stained tear film, is also predicted to be a site of tear hyperosmolarity in the blink interval [163,411]. However, the risk of hyperosmolar damage to the underlying corneal and conjunctival epithelium, due to MIT, is minimized by eye movements, especially in the vertical plane, which can distribute the effect over a wider area and reduce its damaging potential. Nonetheless, as McMonnies has observed, 'this may not be the case during reading, watching television, or similar activity, when up and down eye movements are limited and the zone of MIT maintains a more stable location on the ocular surface. Stability of its location is likely to be associated with an increased risk of hyperosmolarity-related epitheliopathy' [405]. This effect will be amplified in conditions where there is a severe restriction of eye movements, such as in progressive supranuclear palsy [412], progressive external ophthalmoplegia [413] and endocrine

exophthalmos [414].

Additionally, it has been reported in normal subjects that, after short periods of up or downgaze, bands of MIT are imprinted onto the cornea which persist in the blink interval. These may be accompanied by a secondary disruption of the tear film below [197]. These zones of thinning represent regions of potential hyperosmolar damage and hence a source of increased staining.

The above considerations summarize factors which might direct desiccating stress to the lower part of the exposed globe in any eye. These influences will be amplified in environmental conditions that increase desiccating stress and will be further so in DED states where early tear film breakup will determine the location of regional hotspots of hyperosmolarity. They appear to offer a reasonable explanation for the pattern and distribution of punctate epitheliopathy in DED.

#### 5.5.1.3. Filamentary keratitis.

Filamentary keratitis describes a condition of solitary or grouped filaments, usually no greater than 2 mm in length, which extend from the corneal epithelium into the tear film. They seldom occur on the conjunctiva. It is associated with ocular surface disorders such as DED, SLK, viral conjunctivitis, recurrent corneal erosion, neuroparalytic keratitis, post corneal transplantation, cataract surgery, ocular trauma and ptosis. In ptosis and SLK, filaments are commonly located under the upper lid; otherwise, for instance with severe aqueous deficiency, they have an interpalpebral location.

Corneal filaments stain particularly well with rose Bengal and lissamine green. Using immunohistochemistry, Tanioka et al. showed that they have a twisted epithelial core, surrounded by secretory (MUC5AC) and membrane-associated (MUC16) mucins, inflammatory cells, and conjunctival epithelial cells, from which they concluded that filaments are spun out by an increased frictional action during blinking [415]. Frictional drag on the filaments during blinking results in severe, intractable, ocular pain and foreign body sensation [416]. Although filaments can be removed manually after instillation of a topical anesthetic, recurrence is not uncommon.

#### 5.5.1.4. Superior limbic keratoconjunctivitis.

SLK [417] is a bilateral, chronic inflammatory disease, affecting the upper bulbar conjunctiva, superior limbus and adjacent cornea. It can be a source of disabling discomfort. Typically, a patch of severe, perilimbal conjunctival hyperemia or inflammation, is accompanied by limbal thickening, punctate keratopathy, filamentary keratitis and a papillary reaction in the overlying superior tarsal conjunctiva. There may be a discrepancy between the level of pain experienced and the severity of clinical signs and the diagnosis of may be missed if lissamine green staining is not carried out in the clinical workup of unexplained ocular discomfort. Staining with fluorescein is less apparent unless used with a suitable filter combination [74].

Histologically, squamous metaplasia, epithelial thickening with a decrease in the nuclear-cytoplasmic ratio, and a disappearance of goblet cells is reported in SLK [417]. Twenty five percent of SLK cases are associated with DED [418] and about 30% with thyroid disease [419], so that it is important to examine hormone and autoantibody status. There is also an association with conjunctivochalasis affecting the upper bulbar conjunctiva [420,421].

In SLK, it is reported that the chronic inflammation may be related to the blink and to eye motion [418] and the association of SLK with upper bulbar conjunctivochalasis strongly supports recurrent frictional trauma as a trigger, particularly since surgery directed towards tightening the conjunctiva at this location is highly successful [421,422]. Similarly, in endocrine exophthalmos, an increase in the pressure of the upper lid against the globe may be invoked as the mechanism that precipitates SLK in thyroid disease

with exophthalmos.

### 5.5.2. Conjunctiva

Although conjunctival goblet cell loss and a decrease in MUC5AC concentration in the tears are generally accepted as features of all forms of DED, reports of changes in the transmembrane mucins are less consistent [423]. This is in part due to differences in methodology, for instance in using immunohistochemistry to detect core mucin proteins on the one hand or the pattern of mucin glycosylation on the other. It is difficult to determine what level of glycan alteration is sufficient to disrupt the glycocalyx permeability barrier [154]. A loss of a mucin-like glycoprotein (probably MUC 16) from keratinized, surface conjunctival epithelial cells was reported in SLK [424].

**5.5.2.1. Modification of the epithelial glycocalyx mucins.** There is evidence of an altered expression or glycosylation of transmembrane mucins in DED. In an immunohistochemical study, conjunctival mucosal epithelial membrane mucin expression was decreased in patients with Sjögren syndrome [401]. More recently, Shimazaki-De et al. reported a reduced MUC16 mRNA expression in DED patient conjunctiva [425]. Similarly, surface immunoreactivity to MUC-1 appears to be reduced in Sjögren syndrome epithelium, suggesting disruption of normal epithelial differentiation [426], and Corrales et al. found significantly decreased mRNA expression of MUC1, MUC2, MUC4 and MUC5AC in ADDE patients [427].

In contrast, it was shown that the density of cells positive to KL6, a monoclonal antibody against a sialylated epitope of MUC1 was significantly increased in DED patients compared to normal [428]. Additionally, in Sjögren syndrome DED, mRNA and proteins of both MUC16 and MUC1 were increased compared to normal subjects [429]. The basis for these conflicting findings needs to be resolved.

Gipson et al. [430] demonstrated an increase MUC1 and MUC16 mRNA and cell protein expression in impression cytology samples from postmenopausal women compared to normal subjects. In contrast, Srinivasan et al. [431], found that MUC16 mRNA expression was significantly reduced in postmenopausal women with moderate to severe OSDI symptoms, MUC1 mRNA expression remained unchanged compared to non-symptomatic subjects.

In DED, some alterations of mucin glycosylation have been investigated. Garcher et al. showed a decrease of sialylated chains of mucins expressed in impression cytology samples from DED patients and CL users and in glaucoma patients treated with  $\beta$  blockers [432]. In general, glycosyltransferases are the enzymes responsible for the initiation and elongation of glycan chains attached to the protein backbone. In mucins, the enzymatic addition of *N*-acetyl galactosamine (GalNAc) to serine and threonine residues by GalNAc-transferases (GalNAc-T) is the initial step in O-glycosylation. In ocular cicatricial pemphigoid (OCP), the conjunctival expression of GalNAc-transferases was increased in patients with early disease, which could play a role in maintaining epithelial wettability. Conversely, as might be predicted, expression was markedly reduced at the stage of conjunctival keratinization [433].

**5.5.2.2. Goblet cell loss.** Ralph [434] emphasized that conjunctival goblet cell loss is a feature of all forms of DED, and this has been confirmed in later reports, in Sjögren syndrome (SS), OCP, alkali burn, radiation keratitis, SLK, trachoma and after LASIK treatment [401,428,435–439]. In keeping with this, a decrease in MUC5AC staining has been shown by immuno-fluorescence in conjunctival impression samples from DED patients [440] and the expression of conjunctival, MUC5AC mRNA was also significantly decreased in SSDE [383,441], NSDE [427], and patients with tear film instability [425]. MUC5AC mucin protein levels have also been reported to be decreased in human tear samples from patients with unspecified

DED [384] and in patients with severe SSDE [383], and also in the mild DED of visual display terminal (VDT) users [442]. Versura et al., using an immunogold technique, demonstrated a decreased expression of sialic acid, *N*-acetyl-glucosamine and *N*-acetyl-galactosamine in the goblet cells of DED patients [443].

**5.5.2.3. Lid Parallel Conjunctival Folds (LIPCOF).** Lid Parallel Conjunctival Folds (LIPCOF) are due to a redundancy of the bulbar conjunctiva and loss of adherence to the episclera that draws the conjunctiva into a series of folds, above the lower lid margin. It is likely that they result from the same general mechanism that leads to age-related bulbar conjunctival folds elsewhere on the ocular surface (conjunctivochalasis), which have a frictional relationship to blinking [343]. LIPCOF can be identified using slit-lamp biomicroscopy and white light, with the patient in primary gaze and measured at the lower lid margin at points directly below each nasal and temporal limbus [343]. Most recently, optical coherence tomography has also been used to quantify the degree of LIPCOF [444]. Using routine slit-lamp biomicroscopy, the number of conjunctival folds present above the inferior lid, are assessed relative to the height of the tear meniscus [445]. Of note, LIPCOF disappear when the lower eyelid is retracted and then reappear after a few blinks when lid position is restored. LIPCOF are thought to result from inflammatory elastic fibre degradation, possibly involving MMPs [446], or from mechanical friction influencing lymphatic flow [447]. Their presence has good positive predictive value for DED [446,448,449].

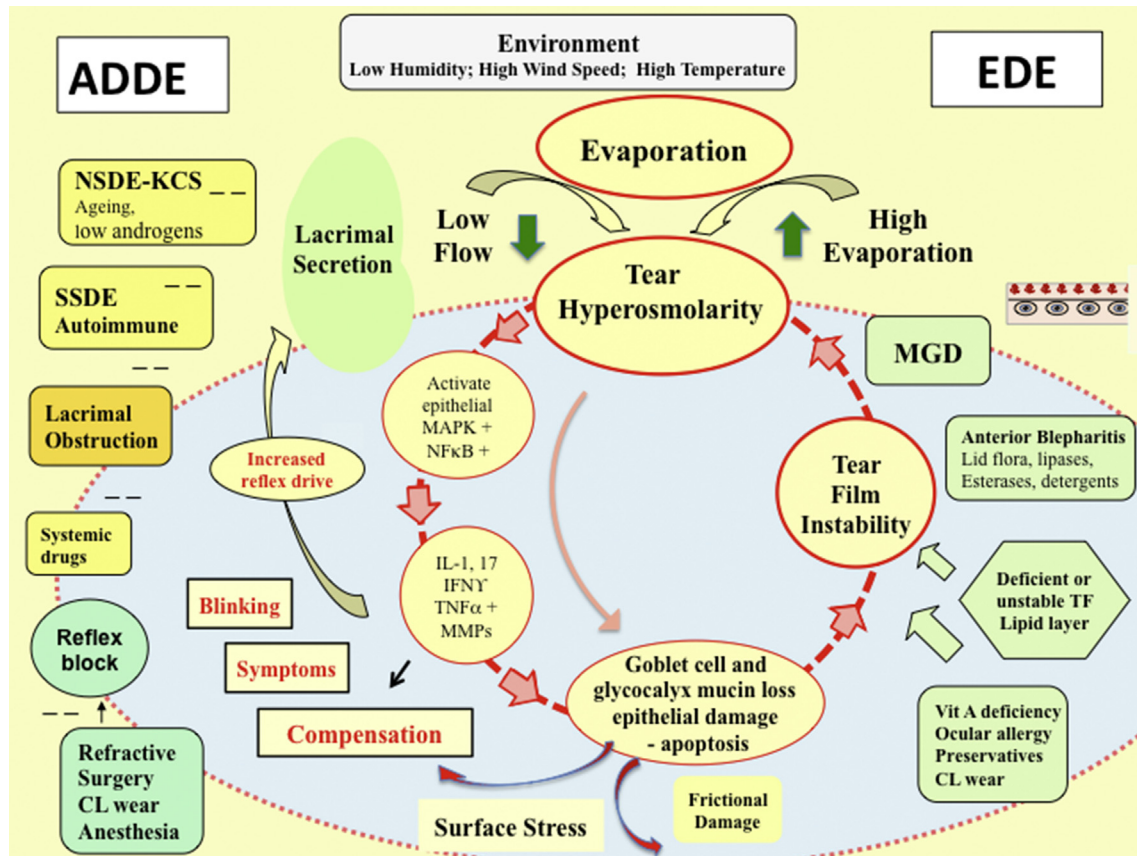
### 5.5.3. The lids

**5.5.3.1. Marx's line and the mucocutaneous junction.** Marx's line is a vital dye staining pattern of the epithelium, located directly behind the mucocutaneous junction (MCJ) of the lid margin [36,76,104,341,450]. (Figs. 7 and 8) It can be demonstrated throughout life on the upper and lower lid margins, extending from the outer canthi to the punctal regions. In youth it is only a few cells wide, but it broadens with age [341] and, together with the MCJ takes an increasingly irregular course.

At the mucocutaneous junction, the epithelium changes from a *hydrophilic*, water-wettable, *parakeratinized* conjunctival epithelium [40] to the *keratinized*, *hydrophobic* epithelium of the lid margin skin. The tear meniscus overlies this hydrophilic epithelium and is pinned to the MCJ at this apex, marking its location. Knop prefers to regard the whole of this parakeratinised zone as the MCJ, stretching from the point at which skin keratinization ends, to the posterior border of the lid margin, or 'crest' (Fig. 9) [40].

It has been postulated that during the blink interval differential effects of evaporation lead to a gradient of tear molarity with a hyperosmolar peak at the tip of the apex. This is suggested to excite increased epithelial turnover immediately behind the MCJ, incomplete differentiation of the surface epithelial cells and an immature glycocalyx, which accounts for the uptake of stain referred to as Marx's line [163,451]. An argument against this *solute gradient hypothesis* is that hyperosmolarity should be cleared when the tears are refreshed at each blink. However, a number of recent reports suggest that there is not full apposition of the lid margins with every blink [322,343,452] and application of Navier-Stokes equations to tear dynamics at the meniscus, instead of lubrication theory, predicts a distinct absence of fluid flow and hence of convective mixing, at the meniscus apex, adjacent to the contact line [411]. This would tend to preserve evaporation-dependent hyperosmolarity at this site. Increased permeability at the site of Marx's line could permit the diffusion of proteins of at least 20Kd and provide a route for pro-inflammatory cytokines such as IL-1 $\beta$ , IFN- $\gamma$ , TNF- $\alpha$  and MMPs to reach the terminal meibomian ducts.

Since IL-1 $\beta$  and IFN $\gamma$  are able to induce the expression of



**Fig. 5.** The Vicious Circle of Dry Eye Disease. The core mechanism of DED is tear hyperosmolarity, which is the hallmark of the disease. It damages the ocular surface both directly and by initiating inflammation. The cycle of events is shown at the centre of the figure. Two forms of DED are recognised, ADDE and EDE. In ADDE, tear hyperosmolarity results when lacrimal secretion is reduced, in conditions of normal evaporation from the eye. In EDE, tear hyperosmolarity osmolarity is caused by excessive evaporation from the exposed tear film in the presence of a normally functioning lacrimal gland. Since tear osmolarity can only arise as a result of tear evaporation in both ADDE and EDE, tear hyperosmolarity is due to evaporation from the ocular surface and in that sense, all forms of DED are evaporative. EDE is a hyper-evaporative state. In DED, tear hyperosmolarity is considered to set up a cascade of signaling events within surface epithelial cells, that leads to the release of inflammatory mediators and proteases. Such mediators, together with the tear hyperosmolarity itself, are conceived to cause goblet cell and epithelial cell loss and damage to the epithelial glycocalyx. Damage is reinforced by inflammatory mediators from activated T-cells, recruited to the ocular surface. The net result is the characteristic punctate epitheliopathy of DED and a tear film instability which leads at some point to early tear film break-up. This break-up exacerbates and amplifies tear hyperosmolarity and completes the vicious circle events that lead to ocular surface damage. Ultimately this is thought to lead to self-perpetuation of the disease. Tear film instability can be initiated without the prior occurrence of tear hyperosmolarity, by conditions that affect the ocular surface, including xerophthalmia, ocular allergy, topical preservative use and contact lens wear. In this case, early tear film break-up (an Ocular Protection Index <1) is the primary basis for tear film hyperosmolarity at first experienced locally at the site of break-up and increasing in severity, at some point being detectable in tear meniscus samples. This represents an ocular surface-related form of EDE. In MGD-related EDE tear hyperosmolarity results from a tear film lipid layer deficiency. In ADDE the onset of early break-up during the evolution of the disease, may add an evaporative element to the dry eye. There are various causes of ADDE. It may result from blocking the sensory drive to the lacrimal gland that is essential to maintain osmolar homeostasis. Bilateral topical anesthesia can cause both a reduction in tear secretion and blink rate. Dry eye due to such a reflex block can be caused by chronic abuse of topical anaesthetics, trigeminal nerve damage and refractive surgery including LASIK surgery. The delivery of aqueous tears to the tear sac can also be reduced by obstruction to the lacrimal ducts, which occurs in any form of cicatricial conjunctival disease, such as trachoma, erythema multiforme, graft-versus-host-disease and chemical burns. A number of drugs in systemic use, such as antihistamines, beta-blockers, antispasmodics, diuretics and some psychotropic drugs, cause a reduction in lacrimal secretion and are risk factors for DED. Tear secretion falls in later life. The anti-glaucoma drugs pilocarpine and timolol also have direct effects on human meibomian gland epithelial cells that may influence their morphology, survival and/or proliferative capacity, and possibly promote MGD [61,1103]. In the western world the most common cause of ADDE is inflammatory infiltration of the lacrimal gland, encountered most severely in autoimmune disorders such as SSDE and, with lesser severity, in NSDE. Inflammation causes both acinar and ductal epithelial cell dysfunction and/or destruction and a potentially reversible neurosecretory block. A receptor block may also be caused by circulating antibodies to the muscarinic, M3 receptor. Inflammation is favoured by low tissue androgen levels. Epithelial injury and a defective glycocalyx, loss of tear volume and of goblet cell mucin, lead to increased frictional damage and friction-related symptoms. The tear hyperosmolarity and epithelial injury caused by DED, stimulates corneal nerve endings, leading to symptoms of discomfort, increased blink rate and potentially, a compensatory, reflex increase in lacrimal tear secretion. This compensatory secretion is more likely in EDE, since lacrimal function is potentially normal. Adapted from Bron, Definition of dry eye disease' in Chan 2015 - Springer [79].

cornified envelope precursor proteins in epithelial cells [453], their delivery over many years, could contribute to hyperkeratinization here, a key feature of MGD. This is supported by the findings of Yamaguchi et al. who reported an age-related, forward movement of the line which was positively correlated with both the meibography scores and the quality of expressed meibum, implying an association with MGD [454].

In the presence of MGD, the line of stain may broaden and advance to involve the region of the meibomian orifices [454], or in the upper lid, with DED and contact lens wear, may broaden

posteriorly to merge with lid-wiper epitheliopathy [344]. The lower lid may be similarly affected [346].

Of those agents known to be increased in concentration in dry eye tears,  $TNF\alpha$  and neutrophil elastase, can cause shedding of glycocalyx mucins such as MUC 16,<sup>241</sup> and could increase the population of cells accessible to dyes, thereby broadening Marx's line. MMP9 causes proteolysis of tight junctional proteins such as zona occludens-1 and occludin [309,314,315] and could increase access to the paracellular compartment of the epithelium and the terminal Meibomian ducts.

**Table 6**  
Sources of dry eye symptoms.

i. Visual Symptoms – (occurring in the blink interval)
Tear film instability and breakup
Epithelial roughness in regions of tear breakup
ii. Symptoms of Discomfort
Tear Hyperosmolarity
General – affecting all tear compartments
Local – tear break-up related, local hotspots of hyperosmolarity
iii. Friction - Reduced lubrication - (Related to blinking and eye movements)
Low tear volume in ADDE
Loss of goblet cells; mucin;
Loss of mature glycocalyx, loss of lubricin
Rough epithelium; punctate epithelial keratitis;
Filamentary keratitis
SLK
LIPCOF - conjunctivochalasis
Lid-Wiper Epitheliopathy
iv. Inflammatory mediators
Algaesic mediators increasing sensory excitability.
Prostanoids,
Cytokines,
Neurokinins
v. Neurosensory and central factors
Trigeminal hypersensitivity;
Neuropathic firing
Cognitive aspects of dry eye symptoms

5.5.3.2. *Lid-wiper epitheliopathy.* LWE is the name given to a region of staining on the lid wiper epithelium, considered to result from friction-related damage [324,342,344]. It has been demonstrated to affect both the upper and lower lid [346]. Although, for the upper lid it has usually been attributed to blinking, gaze movements also generate a relative movement between lids and globe and may be hypothesized to contribute frictional wear and tear to the LW region. Additionally, the initiation of a horizontal saccade is frequently accompanied by a blink, so that they are often combined in everyday viewing conditions [455].

The epitheliopathy can be demonstrated with rose bengal, lissamine green or fluorescein when it is seen as a narrow, irregular patch of staining of the lid-wiper region affecting either the upper and/or lower lid margin in its central part. It is relevant that, during the blink, although the angular velocity of the upper lid margin is the same along the length of the lid, its linear velocity is highest at its centre, which traverses the full width of the lid aperture, and least at its medial and temporal ends, where the distance travelled is least. Therefore the opportunity for frictional damage to the lid or globe is always greatest in the mid-zone of the palpebral aperture, relating more to the cornea than the bulbar conjunctiva. Because the lid-wiper zone makes a narrow band of contact as it traverses the palpebral aperture, the impact of shear stress will be concentrated more on the LW epithelium than the corneal epithelium or globe [324].

Korb et al. [324] compared the frequency of upper LWE in asymptomatic subjects without dry eyes, with that in a group of symptomatic DED patients, using sequential staining with a fluorescein/lissamine green combination. The epitheliopathy was graded on a scale of 0–3 using the horizontal lengths and average sagittal widths of the stained wiper. They found a LWE frequency of 16% in asymptomatic subjects, with 14% of Grade 1, 2%, Grade 2, and 0%, Grade 3. In symptomatic patients, 88% had LWE, with 22% of Grade 1, 46% Grade 2, and 20% Grade 3. The overall prevalence of LWE was six times more in the DED group and the prevalence of LWE Grade 2 or greater was 16 times greater in DED patients than controls ( $P < 0.0001$ ).

In a study by Shiraishi et al. [346] the prevalence of lower-LWE was found to be significantly higher (39.5%) than upper-LWE in non-CL wearers (12.0%;  $P < 0.001$ ) and the prevalence of both

upper- and lower-LWE were significantly correlated with age ( $P < 0.001$ ) but not sex or BUT.

At first sight this is a surprising finding, since, while both lids are exposed to the frictional action of the globe during horizontal saccades, only the upper LW is exposed to extended friction during the blink, since the excursion of the lower lid during blinking is small. This puzzle was addressed in a further study, in which lid movement and globe displacement were followed during spontaneous blinking and lid pressure against the globe measured with a blepharo-tensiometer. The authors found no relationship between eyelid pressure and any grade of upper-LWE, but eyelid pressure in eyes with grade 3 lower-LWE ( $27.9 \pm 2.8$  mmHg) was significantly higher than with grade 0 lower-LWE ( $19.7 \pm 1.3$  mmHg;  $p < 0.05$ ). Also, lower eyelid pressure was significantly correlated with the length of horizontal movement of the lower eyelids during blinking ( $p < 0.05$ ) and the degree of posterior movement of the eye globe ( $p < 0.05$ ). The authors concluded that one cause for the development of lower-LWE was the application of a higher pressure from the lower eyelid.

It is possible, too, that another factor operates. The upper lid and globe move together in vertical gaze, but not synchronously – there is a small relative movement between them. In contrast, the lower lid moves only a small amount in vertical gaze, so that there is a rapid movement of the globe in relation to the lower lid wiper, a potential source of significant friction during reading and working at a computer.

## 6. Inflammatory responses in dry eye – innate and adaptive immunity

In general, immune processes are classified as innate or adaptive. Innate immune responses are considered to be fast and non-specific, whereas adaptive responses evolve over time, are specific and generate memory. These processes occur at the same time and cross talk between each system is critical for the development of an effective response.

The immune responses of the ocular surface are not different from those at other mucosal surfaces [234,456,457]. The microenvironment of the ocular surface is constantly exposed to environmental challenges and maintains surveillance over desiccation, microorganisms, pollution and allergens and other noxious agents. Insults may be either acute or chronic and the immune system deals with them accordingly.

### 6.1. Innate immune responses in dry eye disease

#### 6.1.1. Barriers and inflammatory signals

A critical component of the innate immune system is to provide a physical barrier between the eye and the external environment, for instance preventing the adherence of microorganisms and passage of toxins across the surface epithelia. Elements that accomplish this include the gel mucin of the tears, the glycocalyx, the epithelium itself and a stream of antimicrobial defence proteins including lactoferrin, lysozyme, lipocalin and trefoil peptides and surface molecules such as the defensins ( $\alpha$  and  $\beta$ ) [159,458–461]. However, the corneal and conjunctival epithelia are considered to be the “gate keepers” of the ocular surface [462].

This defence system can be hijacked by the hyperosmolar stress of DED, through the activation of MAPK kinases that in turn activate the master regulator, NF $\kappa$ B, production of IL-1 (chiefly) and of TNF- $\alpha$ . These have major downstream effects by inducing a cascade of other mediators and cellular signals that amplify the inflammatory immune response. IL-1 and TNF- $\alpha$  then up-regulate MMP-9 production by corneal epithelial cells, which is associated with disruption of the epithelial corneal barrier [316].

**Table 7**  
Ocular targets of dry eye disease.

i.	The lacrimal gland.
	Inflammatory cell infiltration of ducts and acini
ii.	The meibomian glands
	Terminal duct obstruction; duct dilatation and gland loss
iii.	The Cornea
	Punctate epithelial keratopathy.
	Filamentary keratitis
	Superior Limbic Keratoconjunctivitis (SLK)
iv.	The Conjunctiva.
a.	General changes
	Punctate epitheliopathy
	Glycocalyx changes
	Goblet cell loss
b.	Bulbar changes
	Lid parallel conjunctival folds (LIPCOF)
	SLK
c.	Tarsal changes
	The lid margins changes
	Marx's line migration
	Lid wiper epitheliopathy.
v.	Both cornea and conjunctiva.
	Increased epithelial shedding
vi.	Tear Film Instability
	Early signs
	Tear film breakup. Spot, dimple, line, area

An aspect of the innate defence system involves activation of pattern recognition receptors (PRRs) such as the Toll-like receptors (TLRs) and the NOD-like receptor (NLR) that mediate cytosolic, inflammasome inflammation. They both participate in the inflammatory response of DED [463]. Stimulation of these receptors is associated with the up-regulation of IL-1, TNF- $\alpha$  and also of IL-6.

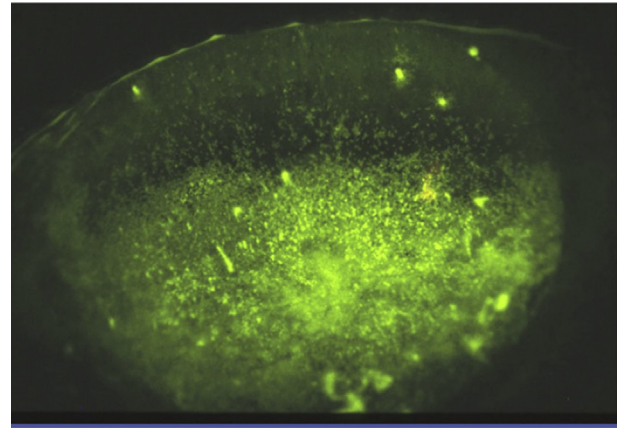
#### 6.1.2. Recruitment signals and inflammatory cells

Experimentally, the expression of IL-1, TNF- $\alpha$  and IL-6 by ocular surface epithelia is critical to the inflammatory response of DED. A step in the amplification process is the generation of signals that recruit both innate and adaptive inflammatory cells to the site of inflammation. These signals may be soluble or membrane-bound and include chemokines and adhesion molecules [464]. In an experimental model of DED, induced by desiccating stress (DES) and scopolamine, the increased expression of inflammatory cytokines by the cornea and conjunctiva was greatly reduced in IL-1 receptor KO mice [465].

Chemokines produced at the ocular surface during an inflammatory response (eg. CCL3, CCL4, CCL5, CXCL9, CXCL10, and CX3CL1, [306, 466–469] can bind macrophages, dendritic cells, neutrophils and activated T cells in which the respective chemokine receptors are up-regulated [470].

The other critical step in the homing of these inflammatory cells to the ocular surface is the expression of endothelial adhesion molecules [464] such as the intracellular adhesion molecule-1 (ICAM-1) which is expressed by conjunctival and corneal epithelium and by blood vessel endothelium in DED [471]. ICAM-1 is an adhesion molecule that binds to inflammatory cells expressing the ligand, *integrin leukocyte functional antigen 1* (LFA-1), causing rolling, transmigration and activation at the site of inflammation and in lymphoid organs [464,472]. Such molecules, located at the surface of the eye represent potentially accessible therapeutic targets. Lifitegrast, an ICAM inhibitor, has recently been approved by the United States Food and Drug Administration for the treatment of DED [473].

Three distinct cell types are involved in the innate inflammatory response, neutrophils, NK cells and monocyte/macrophages. The role of neutrophils in DED is an area of current investigation and the importance of NETs was alluded to earlier (see Section 4.8).



**Fig. 6.** Severe filamentary keratitis, with extensive corneal staining with fluorescein.

However, in a DES model of DED, depletion of neutrophils led to increased CD4<sup>+</sup>T cell activation and increased corneal staining, demonstrating that at some stage, neutrophils may play a protective role [474].

Recent studies of DED models suggest that NK cells may make a significant contribution in the pathogenesis of DED [105,475–477]. The recruitment or activation of resident ocular NK cells has been associated with the increased production of inflammatory cytokines that include IFN- $\gamma$ , IL-6, IL-17 and IL-23, which stimulate macrophages, antigen-presenting cells (APCs) and auto-reactive T cells. NK cells may be an early source of IFN- $\gamma$  that is responsible for the activation and differentiation of Th1 T cells, induction of costimulatory signals by APCs and IFN- $\gamma$  itself is a key inflammatory cytokine causing conjunctival epithelial damage and goblet cell loss [475,478].

The infiltration of the conjunctiva by monocytes, that differentiate into tissue-associated macrophages, is a notable feature of murine DED. Indeed, infiltration by CD11b<sup>+</sup> (monocyte/macrophages) and CD14<sup>+</sup> macrophages correlates with disease progression in a mouse model of autoimmune lacrimal keratoconjunctivitis [479]. Monocytes can differentiate into two types of tissue macrophage; M1 cells are associated with pro-inflammatory responses whereas M2 cells are regulatory. DED has been shown to induce an M1 phenotype in a desiccating stress model [480].

#### 6.1.3. The features of innate immunity

Other elements that are considered to be part of the innate immune system are the gamma/delta ( $\gamma/\delta$ ) T cells and the complement system. Gamma/delta T cells are frequently found in close proximity to epithelial cells, including the conjunctival epithelium [476].  $\gamma/\delta$  T cells can produce IL-17 [481] in the ocular surface but their specific role during DED remains unknown. Studies investigating the role of complement in the ocular surface inflammation of DED, are limited to observations in animal models where nude mice receiving serum from mice with dry-eye, develop DED associated with the recruitment of inflammatory cells and cytokines by the activation of C3a/C5a and C3b/C5b and the formation of the membrane attack complex (MAC) [482]. These observations were also supported by the demonstration of C3b expression in the conjunctiva of diseased mice and the dampening of disease by neutralizing the complement pathway with the systemic administration of cobra venom [482].

## 6.2. Adaptive immune responses of the ocular surface

### 6.2.1. Initiation of adaptive immunity by antigen presentation

The presence of CD4<sup>+</sup> T cells at the ocular surface in DED and the successful treatment of ocular surface inflammation with topical cyclosporine suggested a potential role for adaptive immunity in DED [483]. Initiation of an adaptive immune response requires that antigens at the site of inflammation are processed and presented by professional APCs that migrate to regional lymphoid tissue to activate and expand antigen-specific effector T cells. Although the antigen or antigens that initiate this response in DED are not known, the expression of auto-antigens is hypothesized to be a key trigger to the inflammatory epitheliopathy in Sjögren syndrome. This is regarded as the basis for the production of autoantibodies to type 3 muscarinic acetylcholine receptor (anti-M3R Ab) and the Kallikrein family of proteins including Klk1 and Klk13 [482, 484–486] and the generation of autoreactive T cells [487].

Evidence for ocular surface antigen presentation as the initiating step in the adaptive immune response has come from the correlation between the accumulation of mature CD11c APCs and the activation of antigen-specific CD4<sup>+</sup> T cells in draining lymph nodes during desiccating stress and the reduction of CD4<sup>+</sup> T cell infiltration in animals depleted of ocular surface macrophages and APCs [479]. As ocular surface tissue from inflammatory conditions is characterized by the up-regulation of MHC II and other stimulatory signals, the activation of circulating, primed T cells that are recruited to the cornea and conjunctiva of patients with DED is another plausible pathway of antigen presentation in the generation of local adaptive immune responses [471,482,488].

### 6.2.2. Lymphoid tissues and the ocular surface

Although the spleen is considered to be the main lymphoid tissue responsible for the immune-regulation of intraocular antigens, its role in the immunity of ocular surface inflammation is not considered to be dominant [457]. Also, the role of the thymus in the regulation of the ocular surface immune response is poorly understood. However, evidence from DED in animal models and patients with ocular Graft vs. Host disease in which thymic damage is caused by conditioning before hematopoietic stem cell transplantation, suggests that central tolerance, regulated by the thymic environment may be important in ocular surface immunity [489].

**6.2.2.1. Conjunctiva-associated lymphoid tissue, or CALT.** As in other mucosae, such as the gut, the conjunctiva is equipped with local, stromal collections of lymphoid tissue that are involved in the induction of mucosal tolerance and the regulation of inflammation and immune defence at the ocular surface [490]. These foci constitute the conjunctiva-associated lymphoid tissue, or CALT, the local equivalent of the MALT collections in mucosae throughout the body [118]. They form part of the immune lymphoid circuit.

CALT foci have access to the epithelial surface, and germinal centre/follicle formation has been identified in response to local antigen exposure. Evidence for both homeostatic and pathological responses to protein, microbes and microbial products has been demonstrated in animal models and postulated to occur in humans [491–493].

## 6.3. Inflammation, the meibomian gland and dry eye

A striking feature of the human meibomian gland is its apparent resistance to inflammation and infection. For example, there is no peer-reviewed evidence of inflammation or infection in this tissue in obstructive MGD [36,494,495,976]. Further, exposure of human meibomian gland epithelial cells to a bacterial toxin (i.e. lipopolysaccharide [LPS]) does not induce the expression of pro-

inflammatory gene ontologies, other than that associated with Toll-like receptor signaling [496]. In contrast, LPS stimulates a marked upregulation of genes linked to defense, cytokine and chemokine production, chemotaxis, Toll-like receptor signaling pathways and inflammatory and immune responses in immortalized human corneal and conjunctival epithelial cells [496]. It is possible that this apparent resistance to inflammation and infection within the human meibomian gland is due to the presence of innate anti-inflammatory and anti-infective factors.

In support of this hypothesis, the most highly expressed gene in the human meibomian gland encodes for leukocyte-associated immunoglobulin-like receptor-1 (LAIR-1) [505]. LAIR-1 is an inhibitory receptor that suppresses immune cell activation and reduces pro-inflammatory cytokine production [497,498]. Expression of the LAIR-1 gene is upregulated during human meibomian gland epithelial cell differentiation [43], as are those for uteroglobin (suppresses inflammation [1202]), phospholipase A2 (kills gram-positive bacteria and is a key bactericide in human tears [499]) and CCL28 (has antimicrobial activity against gram-positive and gram-negative bacteria [500]). Recently, investigators had also found that human meibomian gland epithelial cell lysates inhibit the growth rate of the Gram-negative bacteria, *Pseudomonas aeruginosa*, *in vitro* [501]. In addition, human MGD is associated with a significant increase in intraglandular transcripts for [a] S100 calcium binding proteins A8 and A9 (S100A8/9, also called calprotectin; in high concentrations this heterodimer has anti-inflammatory and anti-microbial functions and makes epithelial cells more resistant to bacterial invasion [502–504,1217]; [b] peptidase inhibitor 3, skin-derived (also called elafin [1203], inhibits bacterial infection [1202]); and [c] S100A7 (also called psoriasin, an antimicrobial peptide [1202]) [505].

These findings do not mean that human meibomian glands cannot become inflamed or infected. A single meibomian gland, for instance, may develop a chalazion (i.e. inflammation of a blocked gland), that may become secondarily infected. Further, LPS can induce leukotriene B4 secretion from human meibomian gland epithelial cells [60], and isotretinoin can induce the expression of some inflammatory mediators in these cells [45]. However, neither inflammation nor infection is a characteristic of obstructive MGD, which affects multiple glands [36,506].

## 7. Research in animal models and cellular models *in vitro*

The use of animal models to study DED is a source of hypothesis generation, which enables pathological mechanisms to be examined in relation to clinical disease. The influence of risk factors such as age, sex and environment can also be explored and, in the case of Sjögren Syndrome, the effect of immune dysregulation on immune tolerance. A general review animal models of DED is provided by Schrader et al. [507].

### 7.1. Animal models of Non-Sjögren dry eye

#### 7.1.1. Overview

The Subcommittee has focused on the following two models: The desiccating environmental stress model (DES) involves exposure to a combination of low humidity and increased airflow with or without muscarinic blockade. The muscarinic receptor blockade model (SCP) involves systemic injection of scopolamine to suppress parasympathetic nervous system function and thereby inhibit lacrimal gland secretion.

There are acute and chronic DES models and there is great interest in recovery from damage after removal of the initiating cause because of its relevance to self-perpetuating disease.

### 7.1.2. The desiccating stress model

The desiccating stress or desiccating environmental stress (DES) model, first described by Dursun et al. [508] and later modified by several investigators [509,510] combines a high air flow, a low relative humidity and cholinergic blockade, to impair lacrimal gland secretion. It has become a standard DED model and has been used to study pathogenesis of DED, and potential therapies [511–515]. The DES model recapitulates several features of DED, including corneal staining, conjunctival goblet cell loss, conjunctival infiltration with CD4<sup>+</sup> T cells, increased cytokines in tears, and apoptosis of ocular surface epithelium [378,427,516–518]. Interestingly, DES induces profound epithelial changes, with increased production of cytokines, chemokines and matrix-metalloproteinases that precede the initiation of the immune response [309,378,519], but a significant modulation of the immune system occurs (described below).

Another feature of DED is activation of MAPK that include extracellular signal regulated kinases, JNK and p38 MAPK. Increased levels of active, phosphorylated JNK1 and JNK2 in ocular surface epithelia treated with hypertonic saline *in vivo* and in cultured human corneal epithelial cells exposed to hyperosmolar media has been reported [309–311]. Furthermore, JNK2 but not JNK1, appears to mediate desiccation-induced corneal epithelial disease (by stimulating production of MMP-1, MMP-9, and cornified envelope precursors) since JNK2KO mice were resistant to DED-induced changes [520].

**7.1.2.1. Initiation of dry eye by desiccating stress.** Disruption of afferent and efferent immunoregulation of the ocular surface is recognised as a major process underlying DED inflammation [234,521]. Pro-inflammatory cytokines (IL-1, TNF- $\alpha$  and IL-6) and chemokines, released from stressed ocular surface epithelia cause

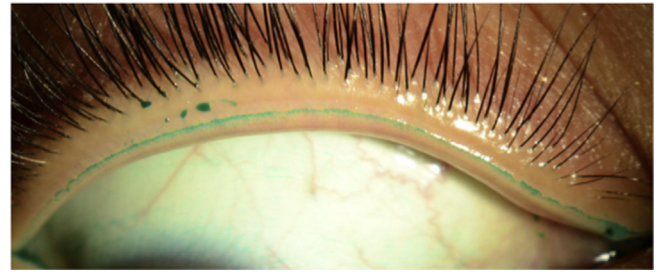


Fig. 8. Marx's line of the upper lid of a young adult, stained with lissamine green. (courtesy of N Yokoi).

epithelial damage and activate antigen-presenting cells (APCs) and NK cells [234,475]. In addition, activation of an innate, NK cell response not only damages target tissues but promotes APC maturation through IFN- $\gamma$  [475,476,522]. These activated APCs on the ocular surface migrate to draining lymph nodes (DLNs) via newly-formed lymphatic vessels (facilitated by VEGF-C and VEGF-D) [512,523,524] and help to prime naïve T cells in the draining lymph nodes (DLNs), leading to the activation and expansion of IFN- $\gamma$ -secreting CD4<sup>+</sup> T (Th1) and IL-17-secreting CD4<sup>+</sup> T (Th17) cells [476,479,525,526]. These unrestrained effector T cells home to the ocular surface via blood vessels under the influence of increased levels of local, ocular surface chemokines [516,527,528]. Increased levels of IL-17 and IFN- $\gamma$  from activated T cells on the ocular surface lead, in addition, to disruption of the epithelial corneal barrier and to decreased conjunctival goblet cell density [516,523,529].

Although both CD4<sup>+</sup> and CD8<sup>+</sup> T cells take part in the adaptive immune response to antigens, CD4<sup>+</sup> T cells predominate at the

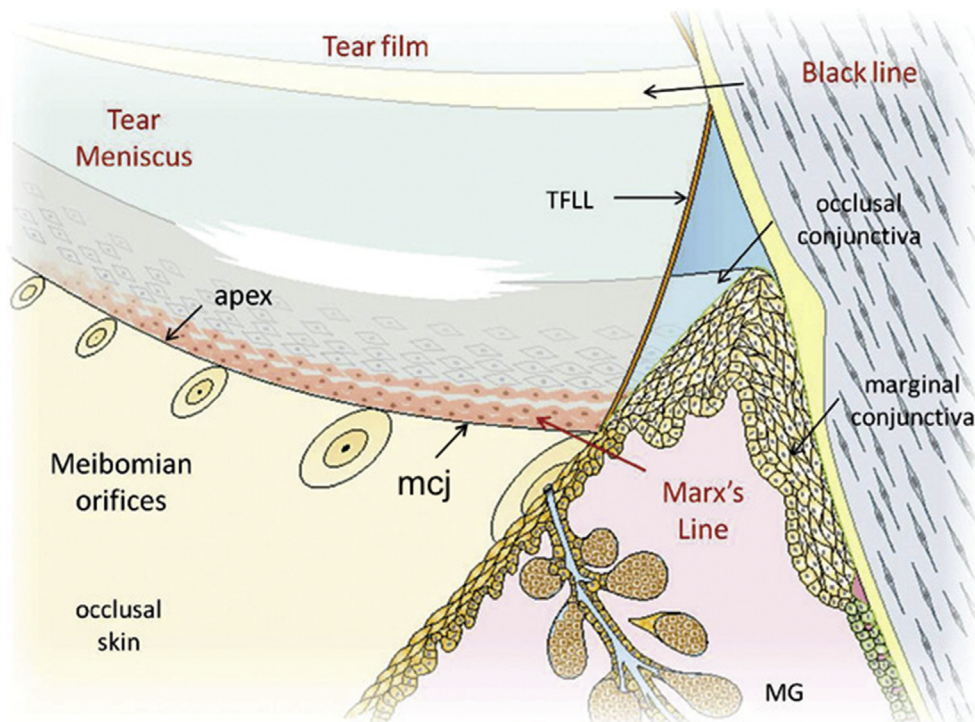


Fig. 7. Schematic view of the lower tear meniscus and lid margin. The meniscus overlies and wets both the occlusal part of the marginal mucosa and the adjoining surface, in contact with the globe. The peripheral apex of the meniscus is pinned at the mucocutaneous junction (mcj) which forms the boundary between the stratified squamous keratinized epidermis of the lid margin skin and the stratified squamous, parakeratinized occlusal conjunctiva. It is located directly behind the meibomian gland orifices. The row of stainable epithelial cells that make up Marx's line lie under the apex of the tear meniscus, immediately behind the mcj. (from Bron, A. J., et al. (2011). "A solute gradient in the tear meniscus. I. A hypothesis to explain Marx's line." *Ocul Surf* 9(2): 70–91 - with permission) [163].

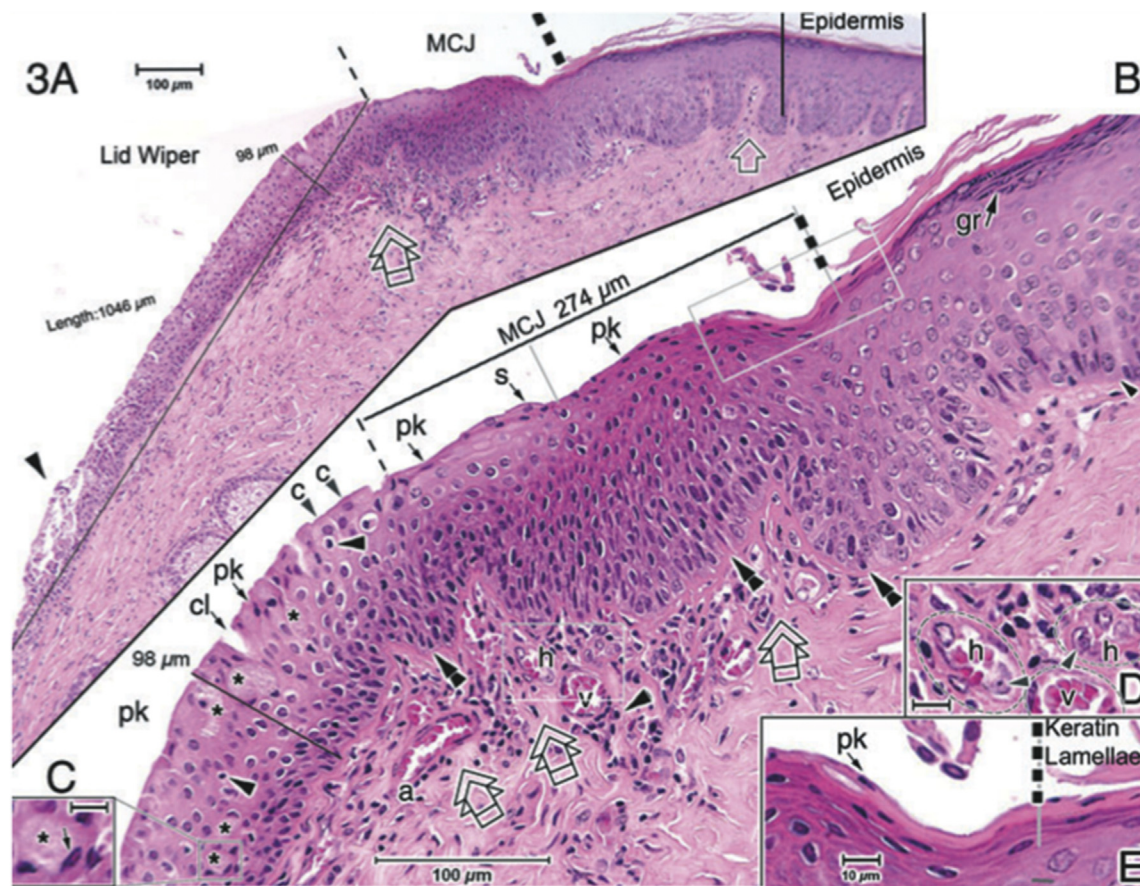


ocular surface in chronic DED [487]. Naïve CD4<sup>+</sup> T cells in the lymphoid tissue differentiate into four functional phenotypes designated according to their major cytokine products. These are classified as Th1, Th2, Th17 and T regulatory (Treg) lymphocytes. Upon antigen presentation, the cytokine milieu present at the time of T cell activation is a major determinant of the final outcome of differentiation. The resolution of the adaptive immune response is mediated by the elimination of these effector CD4<sup>+</sup> T cells by activation-induced apoptosis at the site of inflammation, which results in the generation of memory, antigen-specific T cells characterized by the differential expression of surface markers including CD45RB<sup>+</sup>, CD44<sup>+</sup> and CD69<sup>+</sup>.

Th2 CD4<sup>+</sup> T cells have been associated with the development of allergic responses in the ocular surface and also have a role in maintaining homeostatic levels of conjunctival goblet cells [105]. Niederkorn and colleagues elegantly showed that adoptive transfer of CD4<sup>+</sup>T cells into immunodeficient mice, primed *in vivo* during DES, recapitulates the DED phenotype observed in donor mice [487]. Mice developed DED, with lacrimal gland infiltration, corneal staining, goblet cell loss, CD4<sup>+</sup>T cell infiltration in the conjunctiva

and production of cytokines and matrix metalloproteinases.(Niederkorn, Stern et al., 2006) (Fig. 10) [487].

Th1 CD4<sup>+</sup> T cells are the classic pathogenic T cell subset associated with the generation and progression of immune-related dry eye disease [478]. These populations of effector T cells are differentiated by the presence of IL-12 and are characterized by their production of IL-2 and IFN- $\gamma$  at the site of inflammation. The production of IFN- $\gamma$  by Th1 CD4<sup>+</sup> T cells is a major determinant of the pathological changes observed in the ocular surface of dry eye patients including epithelial cell death, loss of goblet cells and epithelial cells, and squamous cell metaplasia [516,530–532]. The recruitment of Th1 CD4<sup>+</sup> T cells to the ocular surface is regulated by their expression of LFA-1 and its interaction with ICAM expressed in the ocular tissues of patients with DED [472]. Moreover, their increased expression of CCR5 and CXCR3 makes them responsive to the chemoattractants CCL5 and CXCL10, which are also produced in the inflamed ocular surface in response to DES [467,527]. IFN- $\gamma$  has been shown to antagonize IL-13 in the lung and the gut and this is also true on the ocular surface. As noted, IL-13 promotes goblet cell homeostasis in physiological conditions [105], while IFN- $\gamma$



**Fig. 9.** According to Wolff (1946) [76] the marginal conjunctiva is a transitional zone between the skin and the conjunctiva proper, extending posteriorly for about 2 mm, from the mucocutaneous junction (MCJ) anteriorly, past the posterior lid margin and onto the tarsal plate, ending at the subtarsal fold. This H and E section passes through the posterior border of the upper lid margin in the mid-temporal region (A–E). In this figure, the MCJ is described by Knop et al. [36], as a zone, here, 274  $\mu$ m wide, extending from the sharp edge of the cornified epidermis, to the ‘crest’ of the of mucosal epithelium, corresponding to the posterior lid margin. The Pathophysiology Subcommittee prefers to describe the MCJ as a line of junction between the epidermis and mucosal epithelium, marked clinically by the apex of the tear meniscus (See text and Fig. 7), in which case this stretch of transitional, mucosal epithelium is referred to as the occlusal zone of the marginal mucosa (Bron et al., 2011) [163]. In this section, Knop et al. [36] describe a continuous anterior zone (150  $\mu$ m wide – B, grey line) of parakeratinised (pk) cells, followed by a zone of discontinuous pk cells interspersed with ordinary squamous (s) cells. On the tarsal plate, posterior to the crest (narrow dashed line in A, B), is the lid wiper region, which forms a thickened, cushion-like structure, is composed mainly of cuboidal cells, some columnar cells, and also goblet cells (asterisks in B), some of which reside in crypts. Here it reaches a maximal thickness of 98  $\mu$ m and extends for a distance of about 1000  $\mu$ m (A) to reach the sub-tarsal fold. Additional features include: a few intraepithelial lymphocytes (arrowheads in B), occasional small clefts (cl in B), vessels, including high endothelial venules (h), ordinary venules (v), and arterioles (a) underneath the MCJ, better seen in higher magnification (D, Scale bar: 100  $\mu$ m (A,B); 10  $\mu$ m (C–E)). (gr in B = Granular layer). (from Knop, E., et al. (2011). “The lid wiper and muco-cutaneous junction anatomy of the human eyelid margins: an *in vivo* confocal and histological study.” *J Anat* 218(4): 449–461. – with permission) [40].

promotes goblet cell apoptosis [478,530]. IFN- $\gamma$  knock-out mice are resistant to desiccating stress; however, when reconstituted with IFN- $\gamma$ , they develop goblet cell loss similarly to wild-type mice [478]. Adoptive transfer of CD4<sup>+</sup> T cells from donor mice exposed to DES that received anti-IFN- $\gamma$  were less pathogenic to immunodeficient mice recipients, yielding less corneal apoptosis and greater number of PAS<sup>+</sup> filled goblet cells [530]. Mice that received sub-conjunctival injections of anti-IFN- $\gamma$  antibody showed decreased corneal and conjunctival apoptosis [530].

Th17 CD4<sup>+</sup> T cells are the prototype of auto-reactive T cells associated with chronic inflammatory diseases. The presence of IL-17 in the tear fluid of patients with DED and their localization to the ocular surface in animal models of DED induced by DES or auto-immune mechanisms, support the role of these cells in the progression of disease [458,516,526]. It has also been demonstrated *in vitro* that differentiation of naïve CD4<sup>+</sup> T cells into Th17 cells is possible, by co-culturing T cells with corneal epithelial cells that most likely are a source of IL-17 during ocular surface inflammation. Just as the recruitment of Th1 CD4<sup>+</sup> T cells is enhanced at the ocular surface in DED, CCL20 is expressed in the ocular surface of animals exposed to desiccating stress and Th17 T cells expressing CCR6 are potentially responsive to this signal and can be recruited to the ocular surface [516,527]. IL17 causes damage to the corneal epithelium directly and through the up-regulation of MMP9 and MMP3 and the inhibition of protection by Treg cells [516,529]. Both IL-17 and IFN- $\gamma$  have been found elevated in tears and in conjunctival impression cytology of DED patients [235,441,458].

Tregs cells are characterized by the expression of CD4<sup>+</sup>CD25<sup>+</sup>hiFoxp3<sup>+</sup> markers and their role in the maintenance of peripheral tolerance has been found to be critical in immune responses to allo- and auto-antigens in non-ocular diseases. Studies of mice undergoing desiccating stress suggests a significant role of Tregs in regulating and dampening the inflammatory response. If adoptive transfer of Tregs is performed, a significant amelioration of DED inflammation is observed and this correlates with the regulation of “ocular specific CD4<sup>+</sup>T cells” [533]. CD8<sup>+</sup> T cells can also function as regulatory cells, as depletion of CD8<sup>+</sup> T cells during the initiation phases of DES generated more pathogenic T cells. A functional (but not numeric) defect in Tregs has also been shown in DES experiments [529].

The role of B cells in the adaptive responses of the ocular surface in DED remains unclear. B cells and autoantibody production appear to be implicated in the systemic and ocular manifestations of Sjögren syndrome in patients and in animal models [482]. In contrast, their role in chronic DED in non-autoimmune patients is not obvious. However, in addition to the production of pathogenic autoantibodies, the role of professional APCs and activation of auto-reactive T cells cannot be underestimated [534].

**7.1.2.1.1. Distinction between models based on desiccating stress alone and those induced by scopolamine or by a combination of the two.** A majority of experimental evidence supporting the DED inflammation described above has been derived from a murine model of DED that combines DES with systemic muscarinic acetylcholine receptor inhibition using scopolamine [509,535]. DED increases tear evaporation through low humidity and high airflow, and SCP induces tear deficiency by antagonizing muscarinic activity in the lacrimal glands. Low humidity alone is capable of inducing DED, but the kinetics are delayed compared to DES [536]. A recent advance in our understanding of murine DED inflammation is that DES without muscarinic blockade and SCP induce DED through different primary mechanisms [537]. DES without muscarinic blockade induced greater conjunctival CD3 (+) T-cell infiltration, and higher Th17-cell activity and Treg dysfunction than SCP, while SCP reduced tear volume to a greater extent than DES. SCP decreased Th17 activity and increased Th2 and Treg responses

without influencing Th1 activity.

It should be noted that by inhibiting cholinergic activity, scopolamine also has a marked impact on the nature of inflammatory and ocular surface responses in DED. Scopolamine would interfere with the ability of the parasympathetic nervous system to respond to cytokines released during activation of the innate immune system, and to provide a negative feedback control of innate immune responses to restore homeostasis [1220]. Scopolamine would also prevent the ability of the cholinergic anti-inflammatory pathway to counteract abnormal chronic and hyper-activated inflammatory responses [538]. As additional considerations, cholinergic neurotransmitters are known to regulate meibomian gland epithelial cells [42] and goblet cells [539], but this modulatory activity would be suppressed by using scopolamine. Further, goblet cells appear to be dependent on constant neural input from the ocular surface [540], but this communication may be hampered by scopolamine. Overall, given that the immune system and ocular surface are physiologically important in the development and recovery from DED, scopolamine's removal of a major regulatory system (i.e. cholinergic pathway) limits the physiological relevance of this SCP model for understanding immunological and ocular surface processes in human DED.

**7.1.2.2. Acute versus chronic evaporative dry eye models.** The existing DED models are created in the acute setting [509,535], which raises questions as to how findings in these models relate to those in the clinical setting, where DED is generally encountered as a chronic disorder. A chronic, murine DED model has recently been developed, which seeks to address this question [541]. In brief, acute DED was first induced using the same DES method for 14 days, and affected mice were then transferred to a normal humidity environment and maintained for an additional 4 months without any DES or SCP challenge. DED severity peaked at the end of the DES, and after removal from the DES, the corneal epitheliopathy gradually regressed to lower levels, but never normalized. Further, the chronic phase was accompanied by Th17 responses at the ocular surface. These findings suggest that, following the induction of acute DED, corneal epitheliopathy and inflammation may persist into a long-term chronic phase, even without continued exposure to DES.

The mice selected for use in this chronic study had almost no corneal fluorescein staining at experimental inception [542]. In contrast, untreated mice typically seem to have higher and more variable staining [82,1213,1214], as do humans (see Section 4.14.1). It will be of interest to learn whether this chronic model is reproduced in mice with higher initial degrees of corneal fluorescein staining.

**7.1.2.3. An age-related dry eye model.** Another chronic model of DED is the aged C57BL/6 mouse, which also develops spontaneous DED and MGD [545]. Interestingly, female and male mice showed comparable goblet cell loss but greater corneal staining was observed in female mice. Adoptive transfer of aged CD4<sup>+</sup> T cells transferred the DED phenotype to RAG1KO mice, indicating that aging leads to generation of spontaneous autoreactive T cells [545]. The findings of spontaneously activated cells in aged mice of both Th1 and Th17 phenotype warrants further investigation.

**7.1.2.4. Relevance of mouse models for human inflammatory diseases.** Mouse models can be invaluable to help clarify the underlying physiological and pathological processes in many human conditions. Ideally, such understanding may be translated into therapies for various human diseases. However, potential treatments that have been discovered and validated in mouse models do not always translate successfully to human therapies. This is especially true for

treatments targeting inflammatory pathways. Genomic responses to inflammatory challenges have demonstrated poor correlations between different mouse models in comparison with human responses [546]. Although some studies indicate that experimental findings with mice can be predictive of therapeutic success in humans [547,548], the fact remains that almost 150 clinical trials involving investigational anti-inflammatory therapies based on mouse data have failed [546], including several potential treatments for DED [549]. Some of these clinical trials were based on data from DES [514,550,1218] and botulinum toxin [551] mouse models. These results underscore the need to show whether a given mouse model mimics, or fails to mimic, a relevant human disease [546,552,1204].

## 7.2. Animal models of Sjögren Syndrome dry eye

### 7.2.1. Introduction

Sjögren syndrome is a chronic autoimmune disorder that affects exocrine glands, notably the lacrimal and salivary glands, causing DED and dry mouth in addition to affecting other organ systems. The clinical features of human disease are elaborated in a later section of this report.

Several animal models have been used to study the pathogenesis of Sjögren syndrome and have provided insights into the disorder, including its heterogeneity (Table 8). While animal models recapitulate one or more aspects of Sjögren syndrome, no perfect model exists. This section focuses on ocular events in autoimmune murine models.

### 7.2.2. Animal models of Sjögren Syndrome

A review of the animal model literature shows a dichotomy in reports, with rheumatological research focused on the salivary gland as the target organ and ophthalmological research favoring the lacrimal gland. With the exception of reports in MRL/lpr, NZB/NZW and NOD mice [553–556], there is relatively little comparative information about salivary and lacrimal pathology in the same animals. Ocular manifestations are also less widely studied in the rodent model. There is a need for more studies, embracing pathological changes in both organs which could identify common pathways of glandular destruction and delineate gland-specific differences. The temporal sequence of pathological events may be a guide to cellular and molecular mechanisms. It is still unclear as to what extent ocular surface manifestations in Sjögren syndrome are secondary to lacrimal or meibomian gland involvement or to the targeting of corneal and conjunctival autoantigens.

The influence of age, disease duration and sex is important in human Sjögren syndrome and age is one of the strongest risk factors for the DED [557–561]. Similarly, in animal models, the full Sjögren syndrome-phenotype often takes time to evolve [536,562,563]. Two models illustrate this well. First, as noted, non-immune C57BL/6 mice spontaneously develop a lacrimal-dependent DED, starting at post-menopausal age (6–9 months), up to an elderly age of 24 months [545]. Second, the non-obese diabetic (NOD) mouse, variant strain (NOD.B10.H2<sup>b</sup>) has a mild Sjögren syndrome phenotype at 10 weeks of age, but develops severe dacryoadenitis and DED at one year of age [564]. This suggests that a defined level of immune dysregulation is required to establish the histological Sjögren syndrome phenotype, dependent on such factors as the tissue accumulation of lymphocytes, loss of T regulatory cells and/or the generation of autoantibodies. Similar to human Sjögren syndrome, the presence of histologic lesions is considered one of the most important criteria for diagnosing Sjögren syndrome in the animal model [565].

The strong predilection of Sjögren syndrome for women has been linked in large part to the sex-related differences in, and sex

steroid actions on, the immune system. It is discussed in depth in the report of the Sex, Gender & Hormones Subcommittee. Non-Sjögren DED (NSDE) is also more prevalent in women than in men [559,566,567]. Some intriguing observations have been made in animal models. In the NOD mouse, a model of Sjögren syndrome, the susceptibility of the lacrimal gland and salivary gland to inflammatory infiltration shows a strong sex bias with sialoadenitis developing in female mice and dacryoadenitis in male mice [568]. In contrast, as in humans, inflammation is significantly greater in lacrimal and salivary glands of female MRL/lpr mice, as compared to age-matched males [569]. Unfortunately, only limited information is available concerning the sex-related differences in lacrimal and salivary glands in animal models of Sjögren syndrome [555,556,569,570].

### 7.2.3. A consideration of specific models

Hallmarks of Sjögren syndrome include lymphocytic infiltration, production of autoantibodies and glandular loss secondary to epithelial apoptosis. It is still unclear whether lymphocytic infiltration precedes or is necessary for glandular apoptosis, and the relevant antigen(s) have not been identified. The following section groups different Sjögren syndrome models according to their potential relevance to the pathogenesis of human Sjögren syndrome. The grouping is somewhat arbitrary as many models could be included in more than one category.

**7.2.3.1. Infiltrating autoreactive T cells.** The presence of activated, autoreactive T cells within the lacrimal or salivary glands is a pathognomonic feature of human Sjögren syndrome and the *focus score* (the number of mononuclear cell infiltrates containing at least 50 inflammatory cells in a 4 mm<sup>2</sup> glandular section), in a minor salivary gland biopsy is an integral part of the current, international classification criteria for Sjögren syndrome [565,571]. Other components are the presence of serum antibodies, and subjective and objective evidence of DED and dry mouth. Several Sjögren syndrome models which exhibit glandular T cell infiltration can be included here, including the NOD, CD25KO, Scurfy, MRL/lpr, AIRE-KO, IL-12 transgenic (Tg), C57BL/6.NOD-Aec1Aec2 (Aec), NOD.B10.H2<sup>b</sup>, and Osteopontin (OPN) Tg mice.

In MRL/lpr mice, a genetically-determined disruption of the Fas-Fas ligand system leads to tissue infiltration by lymphocytes, many of which are T cells [572,573,1205]. Interestingly, the genetic background in which the Fas mutation occurs, influences the phenotype and severity of dacryoadenitis and goblet cell loss [574–576]. The two most commonly used inbred laboratory strains of mouse show a distinct bias in their ability to mount an immune response: BALB/c mice and C57BL/6 are Th2 and Th1-skewed, respectively [577]. This may explain why goblet cell density is influenced by genetic background in the MRL/lpr mutation, with goblet cell density higher in the MRL/lpr.BALB/c mouse and lower in the MRL/lpr.B6 compared to respective wild-type controls [578,579].

In both CD25KO and the autoimmune regulator gene (AIRE) KO mice, disrupted immune tolerance leads to accelerated lacrimal gland destruction, with a severe phenotype [580–582]. CD25 is the IL-2 receptor  $\alpha$  chain, the binding arm of the heterotrimeric IL-2 receptor [583–585]. It is expressed on T and B cells. In its absence, as in the CD25 knockout (CD25KO), cells are unable to respond to IL-2, no T regulatory cells are generated, spontaneous autoreactive T cells arise and these cells fail to undergo activation-induced cell death [586,587]. CD25KO mice develop age-dependent dacryoadenitis and systemic autoimmunity. This is also accompanied by ocular surface staining, goblet cell loss and the appearance of M3R antibodies [536,582].

Mice lacking the AIRE KO mice develop a CD4<sup>+</sup> T-cell-mediated

autoimmune disease that targets multiple organs, including the lacrimal gland and ocular surface [588]. The AIRE KO mouse in a NOD background, shows severe squamous metaplasia and ocular surface staining which parallels the level of lacrimal gland infiltration [588,589] while the same mutation in a C57BL/6 background leads to significant goblet cell loss and CD4<sup>+</sup> T cell infiltration of the cornea and meibomian periglandular region, compared to wild-type controls [590].

While there is evidence for a role for Th17<sup>+</sup> cells in corneal barrier disruption and sialoadenitis [516,526,591], its role in dacryoadenitis is still controversial. Some of the autoimmune models that have been used to investigate dacryoadenitis have both Th1<sup>+</sup> and Th17<sup>+</sup> T-cells infiltrating the lacrimal gland, making it difficult to determine the individual contributions of Th subsets (TSP-1 KO, MRL/lpr, CD25KO, and Aec). Dacryoadenitis in CD25-IL-17DKO appeared earlier and was more extensive than in the CD25KO parental strain and it was accompanied by greater IFN- $\gamma$ -receptor expression and caspase 3 levels [562], suggesting that IL-17A may have a minor role in counterbalancing IFN- $\gamma$ . Th-1<sup>+</sup> cells have been implicated in colitis, experimental autoimmune uveitis and Sjögren syndrome [475,478,532,562,582,592]. Both NOD. IFN- $\gamma$  KO and NOD. IFN- $\gamma$  receptor KO mice have ameliorated sialoadenitis [593] and the same pattern is observed in CD25-IFN- $\gamma$  DKO [536,562]. These findings indicate that a mixture of both Th1 and Th17 cells are involved in dacryoadenitis and that therapies targeting more than one subset may be beneficial in Sjögren syndrome.

**7.2.3.2. Disruptive TGF- $\beta$  signaling.** TGF- $\beta$  is a pleiotropic cytokine involved in epithelial differentiation, mitosis, cell motility, fibrosis and immune-regulation [308]. TGF- $\beta$  is critical for the induction of CD4<sup>+</sup>Foxp3<sup>+</sup> cells, the regulatory T cells involved in keeping other cells in check [594], but also of T helper (Th) 17 cells [595]. TGF- $\beta$  null mice succumb to massive systemic autoimmunity, affecting both exocrine glands, shortly after birth, making it difficult to investigate the specific role of TGF- $\beta$  in Sjögren syndrome [596–598]. Two other animal models with disruptive TGF- $\beta$  signaling develop moderate Sjögren syndrome with aging: the thrombospondin-1 knock-out (TSP-1) KO and the dominant negative TGF- $\beta$  receptor type II (DN TGFBR2). These mice develop dacryoadenitis and ocular surface manifestations that are accompanied by Th1 and Th17 responses [563,599]. TSP-1KO mice also have anti-SSA and anti-SSB serum antibodies [563]. The dual role of TGF- $\beta$  in promoting Tregs (anti-inflammatory) and generating Th17<sup>+</sup> cells can be appreciated further by subjecting the DN TGFBR2 and TSP1KO to DES, where Th17 cells are involved in corneal barrier disruption [529]. Interestingly, both models show a paradoxical improvement of corneal staining compared to their own baseline prior to exposure to DES [105,600]. This effect was shown to be DC-mediated in the TSP-1KO mice [600]. Polymorphism in the thrombospondin gene was found to be associated with post-refractive surgery-related, chronic ocular surface inflammation in active duty U.S. Army soldiers [601]. Future studies are needed to delineate the specific role of TGF- $\beta$  in Sjögren syndrome.

**7.2.3.3. Glandular apoptosis.** Glandular apoptosis is another hallmark of Sjögren syndrome and it is present ubiquitously in almost all Sjögren syndrome models. It is unclear whether it follows or precedes immune infiltration, since the initiating trigger for Sjögren syndrome is unknown. A recent manuscript reported that I $\kappa$ B- $\zeta$ -deficient, lacrimal epithelial cells exhibited enhanced apoptosis that preceded lymphocytic infiltration, demonstrating that epithelial cell death could be an initiating factor in Sjögren syndrome [602]. There is evidence suggesting that immune cells participate in the disorganisation and apoptosis in exocrine glands.

IFN- $\gamma$  has been implicated in epithelial cell loss, inducing apoptosis in salivary gland cell lines [603,604]. As noted above, NOD. IFN- $\gamma$  KO and NOD. IFN- $\gamma$  receptor KO mice have a lower salivary gland focus score and caspase 3 activity compared to the NOD strain [593] and CD25-IFN- $\gamma$  double KO mice have significantly lower caspase 3 levels and a lesser degree of dacryoadenitis compared to the parental CD25<sup>+</sup>KO strain [536,562]. Cultured rat and human conjunctival goblet cells are exquisitely sensitive to IFN- $\gamma$  and minute concentrations will induce apoptosis [605]. In another report, IFN- $\gamma$  blocked carbachol-induced high molecular weight glycoconjugate secretion and reduced goblet cell proliferation [606]. The authors concluded that this could explain the goblet cell loss and mucin deficiency in DED. These studies indicate that the glandular epithelium can function as both initiator and bystander target of infiltrating lymphocytes.

**7.2.3.4. B cells and immunization models.** SS is accompanied by polyclonal B cell activity and patients with Sjögren syndrome have an increased risk of lymphoma compared to the general population [607–609]. Increased serum autoantibodies (anti-SSA/Ro 52 kDa, anti-SSA/Ro 60 kDa, anti-SSB/La, rheumatoid factor, anti- $\alpha$ -fodrin, antimuscarinic receptor type 3 (M3R), have been used as diagnostic criteria [565,610] but some SS patients are serum autoantibody negative.

BAFF (B-cell activating factor) is a member of the TNF superfamily and regulates B cell survival. BAFF Tg mice, mostly used as an SLE model when younger, develop leukocytic infiltration of sub-mandibular glands with aging [611]. Act-1 is a negative regulator of BAFF and CD40<sup>+</sup>. Act-1tg and Act-1<sup>-/-</sup> mice develop both lacrimal gland and salivary gland infiltration by B and T cells (salivary gland > lacrimal gland) and have anti-SSA and anti-SSB antibodies [612]. NOD modified mice with impaired IgG1 secretion also have an ameliorated salivary phenotype (NOD.IL4 KO; NOD.B10.H2b.IL-4 KO; NOD. NOD.B10-H2b.C-Stat6 KO) [613,614]. Recent studies using M3R KO mice immunized with M3R peptides demonstrated that M3R autoreactive T cells can transfer sialadenitis to immunodeficient mice [615–617]. They also demonstrated that, similar to NOD and CD25<sup>+</sup>KO models, IFN- $\gamma$  is critical for inducing glandular apoptosis, since adoptive transfer recipients of M3R peptide immunized, M3R-IFN- $\gamma$  DKO cells had neither a significant inflammation score nor showed apoptosis [616].

**7.2.3.5. Effect of DES on autoimmune responses.** The autoimmune response of mice to DES has been investigated in a few instances. Yoon and colleagues demonstrated increased conjunctival infiltration and corneal staining when 16 week-old NOD.B10.H2<sup>b</sup> mice were subjected to DES [618]. Upon removal of DES, NOD.B10.H2<sup>b</sup> mice had persistently lower tear production, goblet cell loss and increased CD4<sup>+</sup> T cells than C57BL/6 mice, indicating that DES in a genetically susceptible strain had prolonged effects [619]. In some other strains, such as the DN TGFBR2 and TSP1KO, corneal staining and goblet cell numbers improved after DES [600]. The interaction between genetic susceptibility and DES deserves further study.

### 7.3. Animal models of meibomian gland dysfunction

Ideally, an animal model of human MGD will demonstrate the human MGD signs, as well as the tear film and ocular surface sequelae associated with MGD and EDE. The human MGD signs would include, among others, meibomian gland orifice obstruction and orifice metaplasia (a condition defined as an atypical growth and keratinization of duct epithelium [1219]), a reduced quality and altered lipid profile of meibum, cystic dilatation of the central duct, and acinar atrophy and loss [36,494,495,620–627,1206]. In particular, evidence of hyperkeratinization of the terminal meibomian

gland duct is important, given that this is a predominant feature of human MGD [36,494,620–622,624,627]. In addition, MGD, and the resulting meibum insufficiency, promote tear film evaporation, hyperosmolarity and instability and ocular surface stress, and lead to increased friction, inflammation, eye damage (e.g. corneal squamous metaplasia, loss of corneal microvilli, glycocalyx disruption) and visual impairment [1,36,190,196,549,628–632,1207]. Meibum in human DED also contains cytokeratin-positive inclusions [183].

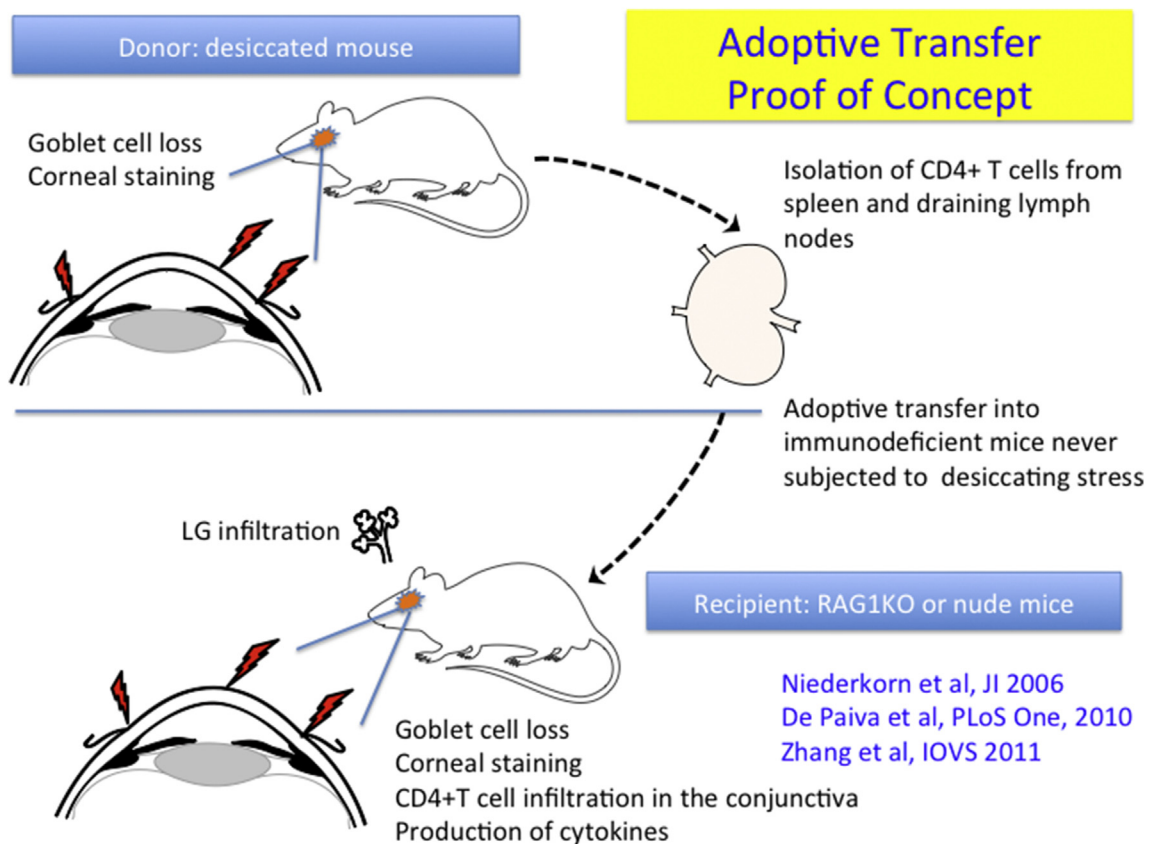
To date, a number of animal models of MGD have been identified or created that mimic, as least in part, human MGD. Monkey [633] and rabbit [39,634–636,1208] models that present hyperkeratinization of the meibomian gland terminal duct epithelium and meibomian gland orifice obstruction have been induced by polychlorinated biphenyl poisoning [633], systemic exposure to isotretinoin [1208] and the topical administration of epinephrine [39,634–636]. A common histopathological finding in these monkey and rabbit models is an abnormal dilatation of the ducts, which feature lumina filled with keratinized materials.

Similarly, rodent models of MGD have been discovered or developed. These are either natural, or have been generated by transgenic or knockout technologies, mutations, immunization, pharmaceutical treatment, exposure to desiccating stress, or alterations in nutrition (Table 9). The resulting strains may feature a variety of phenotypes, such as ductal hyperkeratinization, obstructed meibomian gland orifices, meibum and thickened ducts containing keratinized materials, and acinar cell atrophy, aplasia and loss (see Table 9 for references).

The following three strains show many of these aspects.

First, is a model induced in HR-1 hairless mice by feeding them a special diet with limited lipid content (HR-AD) [637]. This model was developed to facilitate understanding of MGD pathophysiology. After exposure to this diet for 4 weeks, mice develop hyperkeratinization of the meibomian gland ductal epithelium, loss of meibomian gland acini, and ultimately meibomian gland atrophy. Clinical examination of these mice reveals markedly plugged (i.e. obstructed) meibomian gland orifices, telangiectasia, and a toothpaste-like meibum compared with that of a normal eyelid. Of particular interest, topical azithromycin treatment in this mouse model significantly decreases the number of plugged orifices, the keratinization of meibomian gland ductal epithelium, the meibomian gland duct thickness, and the meibomian gland atrophy [637]. Azithromycin, in turn, is known to induce human meibomian gland epithelial cell differentiation [53,638–640], and is a very common therapy for human MGD [641].

A second model is induced by treatment with isotretinoin [642], a known and significant risk factor for the development of human MGD [643–652]. Treatment of rats for 3 months with isotretinoin led to keratinization and thickening of the meibomian gland ductal epithelium, a decrease in the quantity and size of acini, and many degenerated acini and acinar cell casts in the meibomian gland ducts. These isotretinoin-elicited effects could be inhibited by treatment with dehydroepiandrosterone, presumably, according to the investigators, through conversion to androgens [642]. Topical androgens, in turn, have been reported to be effective in the therapy of human MGD [653] (see Sex, Gender and Hormones



**Fig. 10.** Schematic depiction of adoptive transfer experiments. Mice that were subjected to desiccating stress (DES) had goblet cells loss, corneal staining and CD4<sup>+</sup>T cell infiltration in the conjunctiva. CD4<sup>+</sup>T cells were isolated from spleen and draining cervical lymph nodes using magnetic beads and adoptively transferred into immunodeficient mice that were never exposed to DES. Adoptively transferred recipients of CD4<sup>+</sup> T cells developed DED, with lacrimal gland (LG) infiltration, corneal staining, goblet cell loss, CD4<sup>+</sup>T cell infiltration in the conjunctiva and production of cytokines and matrix metalloproteinases, recapitulating the DED phenotype observed in donor mice.

Subcommittee report).

A third model involves interference with growth hormone (GH) action [57]. These include receptor (R) antagonist (A) transgenic mice (GHA) with reduced GH, as well as GHR KO mice with no GH activity. Many of the GHA and GHR KO meibomian glands present with hyperkeratinized and thickened meibomian gland ducts that contain cornified materials, secretory acini inserting into duct walls, and poorly differentiated acini. The GHR KO and GHA mice also have significantly smaller meibomian glands, as compared to wildtype controls [57]. Given that GH levels decline with aging, it is possible that this decrease contributes to the development of age-related MGD [1216].

Recently, Jester et al. have hypothesized that the primary target in MGD is the meibomian gland, as compared to duct hyperkeratinisation [654]. This hypothesis is based on studies in age-related [655] and evaporative stress mouse models [656]. They propose that key elements of MGD are glandular atrophy through a loss of meibocyte progenitors. Jester et al. also report that desiccating stress in mice results in a phase of acinar hyperproliferation, with a change in protein to lipid ratio causing an increase in lipid viscosity. According to this view, epithelial plugs within the gland ducts do not contain fully mature keratins [654]. Obata and colleagues have also found an age-related correlation between meibomian gland acinar epithelial cell loss and aging [495,624]. In contrast, other researchers have identified keratinization, meibomian gland orifice obstruction and metaplasia associated with human MGD during both aging [627] and in general [36,494,620–622,624]. Further, large quantities of nonlipid, protein-like inclusions that stain for cytokeratins have also been identified in abnormal meibum from DED patients [183]. These inclusions may possibly represent the keratinized materials that appear in the turbid meibum of elderly people [657].

Some of the mouse models listed in Table 9 may be also useful for studies on evaporative DED and corresponding ocular surface sequelae. Consistent with this proposal are the observations that MG absence in X-linked anhidrotic/hypohidrotic ectodermal dysplasia is associated with increased tear evaporation, scarce and shortened corneal microvilli (note: which would disrupt the glycocalyx [658]), corneal defects (e.g. neovascularization, keratinization, and squamous metaplasia), and ocular surface inflammation [1145,1215]. Further, MG atrophy in acyl-CoA:cholesterol acyltransferase-1 knockout mice is associated with corneal erosions [660].

Additional mouse models that display marked alterations in sebaceous gland structure and function (Table 9) may also serve as MGD models. However, studies have yet to be performed to examine these possibilities.

#### 7.4. The microbiome of the ocular surface

There is evidence that the gut and ocular surface microbiome may influence the occurrence of DED. The ocular surface is constantly exposed to the environment but, compared to the lid margins, is a relatively sterile site, based on studies using conjunctival swabs [661,662]. The ocular surface microbiota are regulated by numerous antimicrobial factors produced by the lacrimal glands, goblet cells and conjunctiva, which are secreted into the tears, such as lactoferrin, lysozyme, defensins  $\alpha$  and  $\beta$  and IgA [459–461,663]. Lately, there has been great interest in interactions between the host and the microbiota.

The term microbiota refers to the community of microbes that inhabit a particular site, and the microbiome refers to their collective genomes. Techniques used to assess the microbiome include traditional, microbial culture and cultivation-independent techniques such as polymerase chain reaction (PCR) and 16S ribosomal

DNA amplification and sequencing [664–666]. The literature has been unclear as to the presence of microbiota at the ocular surface [665,667,668], with some authors finding a stable presence, which may be modified by disease, while others indicate that microorganisms are present transiently, prior to their annihilation by ocular surface defence mechanisms. Recently a consensus has been reached that the ocular surface is a paucibacterial environment, but is not sterile [665,668].

The most common microbes cultured from the conjunctival surface, using traditional culture techniques, include *Staphylococcus* and *Propionibacterium acnes*, while more recent techniques indicate that there are many more genera to be found [664,665,668,669]. Swabs of the lid margins yield similar species, albeit at a higher count of colony-forming units [667].

Understanding the role of the microbiome in DED is important as this could provide a potential avenue for treatment. In a study by Graham et al., the bacterial population of the posterior lid margin and lower conjunctival sac of patients with and without DED were assessed using both conventional culture and 16S rDNA PCR [669]. A significantly greater number of bacteria were detected using the 16S rDNA PCR technique as compared to conventional culture which largely yielded coagulase negative staphylococci [669]. Interestingly, bacteria that are otherwise rarely associated with the ocular surface (*Rhodococcus erythropolis*, *Klebsiella oxytoca*, and *Erwinia* species) were identified in inflammatory DED, as well as at the normal ocular surface [669]. A significant difference in the mean bacterial count was found between the control group and the moderate to severe DED groups, a result supported by others [670]. Moreover, the authors found that a reduced goblet cell density was associated with greater bacterial presence [669]. Another study, comparing the ocular, oral and intestinal microbiome of controls and Sjögren syndrome patients showed that there was no difference in the ocular microbiome between the two groups [668]. Decreased diversity was noted in both in the oral and gut microbiome and specific changes in genera were observed. There was a relative decrease in the abundance of *Bacteroides*, *Parabacteroides*, *Faecalibacterium*, and *Prevotella*, with greater relative abundances of *Pseudobutyrvibrio*, *Escherichia/Shigella*, *Blautia*, and *Streptococcus* in Sjögren syndrome patients compared to controls. Furthermore, eye and systemic severity scores inversely correlated with microbial diversity [668].

Another study reported changes to the ocular surface microbiota that occur in the early stages of Sjögren syndrome-like disease in transpondin knock-out (TSP-1KO) mice, leading to the recommendation that TSP-1 derived peptides may be a means by which to reduce commensal flora and the resulting inflammation [671].

Tools to investigate the role of the microbiome in homeostasis and disease states involve the use of germ-free mice or the subjection of mice to a cocktail of antibiotics, either in drinking water or by oral gavage. Antibiotic treatment will induce changes in the bacterial community, leading to a dysbiotic state. Recently it was reported that mice subjected to DES, that drank oral antibiotics for 14 days prior to DES had greater goblet cell loss, greater T cell infiltration and worse corneal staining than mice that were subjected to the same protocol but drank normal water [668]. 16S sequencing of the stools of these mice indicated a decrease in *Clostridium* and an increase in *Enterobacter*, *Escherichia/Shigella*, and *Pseudomonas* after antibiotics + DES for 10 days.

A germ-free environment is very detrimental to ocular homeostasis in the mouse, as it predisposes to or worsens Sjögren syndrome-like disease in non-autoimmune and genetically predisposed mice, respectively [668,672]. Non-autoimmune C57BL/6 mice raised in germ-free conditions have Sjögren syndrome-like features, inclusive of dacryoadenitis and decreased EGF concentration in tears. This was accompanied by corneal staining, goblet

**Table 8**  
Murine models of Sjögren syndrome.

Age of onset	Model	Sex predi-lection	Main mechanism	Main organs affected	References
0–3 Weeks	TGF-β KO	♀ = ♂	Gene deletion of TGF- β	Fatal systemic autoimmunity, inclusive of LG	(Shull et al., 1992, McCartney-Francis et al., 1997) [596,1112]
	Scurfy	♀ = ♂	Deletion in the forkhead domain of Foxp3	Fatal systemic autoimmunity, inclusive of LG	(Brunkow et al., 2001, Sharma et al., 2006) [1113,1114]
4 Weeks	CD25KO	♀ = ♂	Lack of T regs; autoreactive T cells	LG; SMG; colon; ocular surface	(Sharma et al., 2006, de Paiva et al., 2010, Pelegrino et al., 2012, Rahimy et al., 2010) [536,581,1114,1115]
	MRL.lpr	♀	Autoreactive T cells; disruptive Fas-Fas ligand system	LG; SMG; ocular surface	(Jabs and Prendergast, 1991a, Jabs and Prendergast, 1991b, Toda et al., 1999) [556,574,1116]
	AIRE	♀	Defect in the negative selection of organ-specific T cells	LG; ocular surface	(Yeh et al., 2009, Li et al., 2008, Chen et al., 2010) [589,590,1117]
8 Weeks	IL-12 Tg	♀ = ♂	Transgenic mice with Increased expression of IL-12 in thyroid gland	SMG	(Vosters et al., 2009) [1118]
	NFKbiz KO	♀ = ♂	Epithelial apoptosis prior to lymphocytic infiltration	LG	(Okuma et al., 2013) [602]
12 Weeks	C57BL/6.NOD-Aec1Aec2	♀?	Transfer of 2 auto-reactive loci from NOD to non-autoimmune C57BL/6; milder SS phenotype than parenteral NOD	LG; SMG; ocular surface	(Cha et al., 2002, Robinson et al., 1998, You et al., 2015, Bulosan et al., 2008, Cha et al., 2004) [593,1119–1122]
	TSP1 KO	?	Lack of autologous activation of TGF-β; autoreactive T cells	LG; ocular surface	(Turpie et al., 2009, Contreras-Ruiz et al., 2013, Gandhi et al., 2013) [563,599,1123]
	NOD	♀ (S); ♂ (D)	Inbred strain that develops autoreactive T cells; a defect in T regs is controversial	SMG; LG; pancreas	(Tsubota et al., 2001, Lieberman et al., 2015, da Costa et al., 2006, D'Alise et al., 2008, Skarstein et al., 1995) [1124–1128]
	NHE8 KO	♀ = ♂	NHE are a group of membrane proteins that exchange extracellular Na + for intracellular H+	LG; ocular surface	(Xu et al., 2015) [1129]
14 Weeks	DN TGFβRII	♀ = ♂	Autoreactive T cells due to disruptive TGF-β signaling under T cell promoter	LG; ocular surface	(de Paiva et al., 2011) [1130]
16 Weeks	NOD.B10.H2b	♂	Replacement of the NOD MHC I-Ag7Idd1 diabetes susceptibility locus by the MHC I-Ab locus; milder SS phenotype than parenteral NOD in young mice.	LG; SMG; ocular surface	(Yoon et al., 2008, Yamachika et al., 1998, Robinson et al., 1998, Coursey et al., 2015) [564,618,1120,1131]
	OPN-Tg	♀?	Increased expression of osteopontin	SMG	(Husain-Krautter et al., 2015) [1132]
3 months	Tet-mev1 conditional knock-out	♂	Increased mitochondrial oxidative stress	LG; ocular surface	(Uchino et al., 2012) [770]
4 Months	Neurturin KO	♀ = ♂	Defective parasympathetic innervation of their lacrimal glands	LG; ocular surface	(Song et al., 2003) [1133]
	Act1.CD40 DKO	?	Deletion of negative regulator of B cell survival	SMG > LG; skin around eyes	(Qian et al., 2008) [612]
5 months	ArKO	Neither	Estrogen deficiency due to knock-out of aromatase (converts androgens to estrogens)	No inflammation in LG or meibomian gland; increased tear volume in male, not female, compared to wildtype controls	(Rahimi Darabad et al., 2014, Darabad et al., 2013) [691,692]
6 Months	NZB/NZW F1	♀	Hybrid inbred strain, autoreactive T cells	LG; ocular surface	(Kotzin and Palmer, 1988, Gilbard et al., 1987) [1134,1135]
	ArKO	♀	Estrogen deficiency due to knock-out of aromatase	SMG	(Iwasa et al., 2015, Ishimaru et al., 2003) [714,1136]
9 months	C57BL/6	♀ = ♂	Unknown; has accumulation of autoreactive T cells	LG; ocular surface	(McClellan et al., 2014) [1137]
11.5 months	SOD1 KO	♂	Knock-out of anti-oxidant defences (superoxide Dismutase)	LG; ocular surface, MGD	(Kojima et al., 2012) (Ibrahim et al., 2014) [1138,1139]
14 months	BAFF tg	♀ = ♂	Accumulation of B cells	SMG	(Groom et al., 2002) [611]
12–17 months	ArKO	♀ = ♂	Estrogen deficiency due to knock-out of aromatase	SMG	(Shim et al., 2004) [1140]

Abbreviations: ♀ - Female, ♂ - Male, S – sialadenitis, D - dacryoadenitis.

cell loss and pathogenic CD4<sup>+</sup> T cell infiltration [672]. On the other hand, germ-free CD25KO mice have early onset of dacryoadenitis and greater numbers of CD4<sup>+</sup>IFN- $\gamma$ <sup>+</sup> cells infiltrating the lacrimal glands of RAG1KO recipients. These results suggest that signals provided by commensal bacteria and/or their metabolites are capable of modulating ocular health.

### 7.5. Cellular models of dry eye *in vitro*

Ocular surface cell cultures have been used to explore the roles of multiple factors and pathways involved in the pathophysiology and possible treatment of DED. Several such cultures have also been reported to serve as DED models *in vitro*.

Three DED models use the cornea. One model utilizes rabbit corneal cultures with experimental time frames of up to 21 days [673]. Studies with this model have used optical coherence tomography to monitor the impact of DES, with a focus on changes in corneal layer thickness and in stromal scattering properties [673]. Another DED model *in vitro* utilizes human reconstructed corneal epithelium maintained in a controlled environmental setting (relative humidity <40% and 40 °C temperature) for 24 h and up to 72 h [674]. Culture conditions are controlled to mimic DED, and thereby permit identification of biomarkers that may be predictive of corneal damage and response to treatment. A third DED model uses human reconstructed corneal epithelium to assess the effects of severe osmotic stress and associated treatment on inflammatory pathway activity and barrier integrity [675].

A fourth DED model uses immortalized human meibomian gland epithelial cells [50]. This model involves exposure of these cells *in vitro* to isotretinoin [45], a well-known risk factor for the development of human MGD *in vivo* [643–652]. Exposure of human meibomian gland epithelial cells to isotretinoin: [a] alters the expression of thousands of genes, including an upregulation of genes for some inflammatory mediators (e.g. IL-8 and IL-1 $\beta$ ), proteases (e.g. MMP-9), MAPK signaling, lytic vesicles, apoptosis and cell death, and suppresses genes linked to DNA replication, cell cycle, RNA transport and mitochondria; [b] increases the levels of pro-IL-1 $\beta$ , IL-1 $\beta$  and MMP-9 proteins; [c] decreases the signaling of the cell growth and survival mediator, phosphoinositide 3-kinase protein kinase B; and [d] inhibits cell proliferation and induces cellular atrophy and death (e.g. by apoptosis, necrosis and/or autophagy) [45]. It is possible that these effects may be responsible for the acinar epithelial cell degeneration and atrophy, and reduced and abnormal secretions, that occur following isotretinoin induction of human MGD *in vivo* [643–652].

## 8. Human disease. Etiological classification of DED

It is still useful to discuss DED under two major headings, that of ADDE and EDE (Table 5).

### 9. Aqueous-deficient dry eye (ADDE)

ADDE is subdivided into Sjögren syndrome dry eye (SSDE) and non-Sjögren syndrome dry eye (NSDE).

#### 9.1. Sjögren Syndrome and Sjögren Syndrome dry eye

##### 9.1.1. Introduction

Sjögren syndrome is a chronic autoimmune disorder characterized by immune cell infiltration of exocrine glands (exocrinopathy or epitheliitis) and systemic complications due to autoantibody production, immune complex deposition and lymphocytic infiltration of many organs [676] (Table 10). The prevalence of primary Sjögren syndrome (pSS) in the USA has been

estimated to be 0.6–1%, affecting between 0.4 million to 3.1 million adults [677]. However, this estimate is different than that of another study, which reported Sjögren syndrome afflicts less than 40,000 people in the USA [678]. More recent data indicate that the average annual incidence of pSS in a physician-diagnosed, population-based cohort in the USA is 5.8 per 100,000 [679], and that the prevalence of pSS in a geographically well-defined population in Omstead County, Minnesota, is between 2 and 10/10,000 inhabitants [680]. If translatable to the USA population as a whole, this estimate would indicate that between 65,000 and 326,000 people in the USA have pSS.

Sjögren syndrome occurs predominantly in women, with a female/male ratio of 9:1<sup>557–559, 561</sup> and it may lead to a very severe form of DED [681]. The disease may result from a range of aberrant immune responses to environmental and viral triggers occurring in genetically susceptible individuals. Hormonal environment is also important (see Sex, Gender & Hormones Subcommittee report). It involves a loss of immune tolerance, the presentation of auto-antigens and dysregulation of both the innate and adaptive immune systems [682,683]. The lacrimal and salivary glands are major targets of the epitheliitis, leading to gland destruction and the key symptoms of DED and dry mouth (sicca symptoms).

Historically, Sjögren syndrome was described as a condition in its own right, pSS or as part of a systemic autoimmune disorder (secondary Sjögren syndrome - sSS), such as rheumatoid arthritis, systemic lupus erythematosus (SLE) and Wegener's granulomatosis [684]. More recently, the American College of Rheumatology has recommended that the diagnosis of Sjögren syndrome should be given to *any* patient who fulfills the diagnostic criteria of Sjögren syndrome [565] without distinguishing it as primary or secondary, recognizing them both to be a manifestation of immune dysregulation. The Subcommittee recognizes the value of this approach but the older terminology is retained here in relation to past literature.

Symptoms of DED and dry mouth are a major feature of Sjögren syndrome that are a result, at least in part, of infiltration of the salivary and lacrimal glands by T and B lymphocytes, dendritic cells (DCs), macrophages and other mononuclear cells, leading to tissue dysfunction or destruction [683]. In SSDE the lacrimal glands are considered to be primary targets of immune attack. This is less certain for the conjunctival epithelium and goblet cells, which are also involved clinically.

The signs and symptoms of SSDE are similar to those of NSDE. The ocular symptoms include blurred vision, grittiness and ocular discomfort and clinical signs include tear film instability, corneal and conjunctival staining, goblet cell loss and epithelial metaplasia [382,401,685,686]. However, the onset of SSDE is earlier and where populations of patients with either NSDE or SSDE are compared, SSDE patients are consistently younger and their disease more severe [610,687] suggesting a more rapid progression. There is also a greater risk of blindness with SSDE [688]. The higher frequency of severe MGD in patients with SSDE compared to NSDE contributes to its severity [375].

##### 9.1.2. Hormonal influences

SS affects more women than men and its prevalence increases in post-menopausal women [566,567,689]. Sex-related differences in the prevalence of DED have been linked, at least in part, to the effects of sex steroids (e.g. androgens and estrogens). These endocrine actions are detailed in the Sex, Hormone & Gender Subcommittee report. In brief, sex steroids act on the meibomian gland, lacrimal gland, conjunctiva and cornea. Hormonal influences occur most likely after local, intracrine synthesis and appear to be mediated primarily through nuclear, and possibly membrane, receptors. Sex steroids impact multiple structural and functional aspects of the ocular surface and adnexa, including tissue



architecture, gene expression, protein synthesis, immune activity, epithelial cell dynamics, aqueous secretion, meibum production, mucous output and tear film stability. For example, androgen deficiency has been linked to the development, and androgen administration to the treatment, of lacrimal gland inflammation (e.g. Sjögren syndrome), meibomian gland dysfunction (e.g. Sjögren syndrome and aging), corneal glycocalyx disruption, ocular surface damage, tear film instability, and aqueous-deficient and evaporative DED. In contrast, the precise role of estrogens in the physiology and pathophysiology of ocular surface and adnexal tissues is unclear and, in some cases, controversial. A foremost consideration is that a number of the sex steroid effects may be sex-specific (i.e. unique to males or females) [36,690–693]. Recognition of these sex-related differences and the determination of their underlying basis (e.g. sex steroid action) are extremely important. (A full discussion is provided in the report of the Sex, Hormones and Gender Subcommittee).

### 9.1.3. Etiology: genetic susceptibility

Genetic susceptibility plays a role in the etiology of Sjögren syndrome. A number of associations have been made between pSS and gene loci or specific genes [694]. (Table 11) Increased risk of pSS has been associated with HLA II, IL-12A, BLK, STAT4, CXCR5 and IRF5 in a recent study of subjects of European descent, fulfilling the European-American consensus criteria [694]. Loci of interest are not identical in all geographic locations, indicating ethnic differences in susceptibility [695].

Some of the clinical and immunological similarities between pSS and SLE may have a genetic background. A number of Sjögren syndrome-associated gene polymorphisms including the MHC-II, STAT4, IRF5, BLK, and TNIP1 genes are shared with SLE and other autoimmune conditions. However, the genes CXCR5 and GTF2L, have only been determined as risk factors in Sjögren syndrome and conversely, many genes associated with risk of SLE are not found in Sjögren syndrome [695].

Burbelo et al. [695] have proposed that the Sjögren syndrome-associated genes result in immune dysregulation via at least three pathways: 1. *Activation of the IFN signaling pathway*. 2. *Activation of B-cell function antibody production and clearance pathways*. 3. *Activation of NFκB activity pathways*.

A general prediction is that the possession of one or more such genetic risk factors influences affected individuals in terms of clinical manifestations, onset, severity and progression of the disease. Of interest is that none of the genes that confer risk are related to glandular physiology or sex. All polymorphisms occur in non-coding sequences, reflecting an epigenetic role that determines gene expression rather than gene product. All of the risk genes relate to the performance of the immune system.

### 9.1.4. Etiology: viral infection

The etiology of Sjögren syndrome remains unclear and involves multiple factors. One of the theories of the onset of Sjögren syndrome relates to viral infection. Indeed, various associations between viral infection and DED have been reported, including Hep B, HLTV1, HIV and Epstein Barr virus (EBV). Importantly, it has been suggested that the generation of tertiary or ectopic lymphoid structures (TLS) in response to viral infection may provide a site for autoantibody production in genetically disposed individuals [696].

### 9.1.5. The inflammatory process in Sjögren syndrome

Our understanding of the destructive inflammatory process that occurs in the lacrimal glands of Sjögren syndrome patients is partly inferred from the study of labial minor salivary gland biopsies. The typical pathologic lesion in the minor salivary glands consists of clusters of round cell infiltrates whose composition depends on

lesion severity. CD4<sup>+</sup> T cells predominate in milder lesions and CD8<sup>+</sup> T cells and B cells in more severe lesions [697]. The distribution of other infiltrating immune cells also correlates with the degree of inflammation, with macrophages increasing and interdigitating dendritic cells decreasing with increasing severity [698]. Sjögren syndrome patients have been categorized at diagnosis into distinct groups according to whether the predominating immune response is T or B cell mediated [699] and whether the T cell response is mainly of Th1, Th2 or Th17 type. According to Moutsopoulos [697], Th1 responses are the most common, Th2 cytokines predominate in mild lesions and Th17 reactivity correlates with greater lesion severity.

Of particular concern in Sjögren syndrome is the formation of germinal centres, which are predictive of a higher risk of lymphoma [700,701].

**9.1.5.1. T cells.** T cells, which play a major role in Sjögren syndrome inflammation, can be divided into several subsets according to the cytokines that they make. Th1 cells produce IFN-γ and IL-18; Th17 cells produce IL-17 and IL21 and Th2 cells secrete IL-4, IL-5 and IL-13. Historically, Sjögren syndrome has been identified as a Th-1-dependent autoimmune disease, with increased concentrations of IFN-γ in tears, conjunctiva, saliva, lacrimal and salivary gland and blood [235,478,522,582,702]. Moreover, a Th1/Th2 imbalance, with high levels of IFN-γ in blood, salivary glands, tears or conjunctiva correlates with a more severe phenotype, which may help to differentiate Sjögren syndrome-determined aqueous tear deficiency from a non- Sjögren syndrome aqueous tear deficiency [532,703].

Recently, Th17 cells have emerged as players in the pathogenesis of Sjögren syndrome and the interaction between Th1 and Th17 cells is starting to be elucidated. There is evidence for the presence of IL-17 in fluids such as the tears, saliva, serum and synovial fluid and in tissue lesions themselves in patients with Sjögren syndrome [704–706]. Data from animal models have shown a pro-inflammatory role for IL-17 in sialoadenitis, while its specific role in lacrimal gland inflammation is still under debate [536,562,581,582,591,707,708].

**9.1.5.2. Epithelial cells.** A contributor to glandular inflammation is the activation of acinar and ductal epithelial cells to perform immune functions and act as non-professional APCs whereby they mediate the recruitment and activation of almost all types of immune cells that drive the activation and differentiation of T and B cells. The factors which trigger epithelial activation are not known, but it has been suggested that latent viral infection (see above) or other intrinsic factors are responsible for their activation, in the context of an appropriate genetic and environmental background [709]. Activated salivary gland epithelial cells express a range of immunomodulatory molecules implicated in innate and acquired immune responses. They can also present autoantigens released from exosomal vesicles [710] or apoptotic bodies [711]. They therefore play an important role in initiating and perpetuating the local autoimmune process in the salivary glands, in Sjögren syndrome. A key feature of the process is that while infiltrating lymphocytes remain activated, the activated glandular epithelial cells undergo apoptotic cell death [712]. It is yet to be determined whether lacrimal gland epithelial cells play an analogous role.

**9.1.5.3. B cells.** B cell hyperactivity is now recognised as a central element of Sjögren syndrome, underscoring the loss of immune tolerance. It is manifested by hypergammaglobulinaemia, cryoglobulinaemia and the production of multiple autoantibodies, directed, for instance, against α-fodrin, the M<sub>3</sub> muscarinic receptor, and the ribonucleoprotein components Ro52 and Ro60 (anti-Ro/

SSA) and La (anti-La/SSB). The latter are included among the classification criteria for Sjögren syndrome and correlate with early disease onset, parotid gland enlargement, extraglandular manifestations and lymphocytic glandular infiltration [683].

B cells fulfill other functions besides producing autoantibodies, by acting as APCs and secreting cytokines that can sustain the immune response [713].

**9.1.5.4. Dendritic cells.** Dendritic cells help orchestrate the immune response. There is evidence of cross-talk between dendritic cells and epithelial cells. Epithelial cells secrete inflammatory cytokines that can activate dendritic cells and T-cells and these in turn can further activate the epithelium. For example, IFN- $\gamma$ -stimulated expression of MHC-II and HLA-DR, a ligand for the T-cell receptor, by epithelial cells, is well documented in the literature [714]. Expression of HLA-DR by both epithelium and DCs has been noted previously and recently used as an endpoint in clinical trials for DED [381,715–717].

**9.1.5.5. Autoantibodies.** Circulating autoantibodies in Sjögren syndrome contribute to its pathophysiology and can be of diagnostic importance [718]. Autoantibodies directed against Ro/SSA and La/SSB autoantigens are one of the recommended diagnostic tests for Sjögren syndrome [684,719].

Similarly, autoantibodies against the M<sub>3</sub> muscarinic receptor can be found in a subset of Sjögren syndrome patients, and have been considered to be pathogenic [720]. Some studies showed that these autoantibodies have agonistic (i.e., stimulating) activity whereas others showed that they have antagonistic (i.e., inhibitory) activity [721–724], although the difference may be methodological. The prevalence of these antibodies in the sera of Sjögren syndrome patients varies considerably, which questions their usefulness for diagnostic or prognostic purposes [720].

### 9.1.6. The lacrimal gland in Sjögren syndrome

The loss of aqueous tear flow in Sjögren syndrome is a result of inflammatory cell infiltration of the lacrimal glands which leads to acinar and duct destruction. Infiltrating lymphocytes, epithelial, endothelial and neural cells are all potential sources of inflammatory cytokines and other mediators that are responsible for lacrimal tissue damage. Additionally, inflammatory changes within the gland may lead to a decrease in lacrimal secretion by reason of damage to secretomotor innervation, or inhibition of neurotransmitter release or action by cytokines or antibodies [725]. The lacrimal glands in Sjögren syndrome are heavily infiltrated with mononuclear cells, the majority of which are T lymphocytes, with a lesser number of B cells and plasma cells (Fig. 11) [726]. These T cells express the activation marker IL-2R and contain cytotoxic granules such as granzyme A [727,728]. The degree of lymphocyte infiltration of the lacrimal glands correlates well with lacrimal secretion. Poor reflex tear secretion on nasal stimulation correlates with the presence of Sjögren syndrome autoantibodies and with both lacrimal and salivary lymphocyte infiltration in DED patients [729].

According to earlier reports, as in salivary gland biopsies, CD4<sup>+</sup> T cells predominate over CD8<sup>+</sup> cells in the lacrimal gland infiltrate, while B cells make up the smallest numbers.

Because of the constraints on using lacrimal gland biopsies for investigative purposes there would be great value in setting up prospective, post-mortem studies of lacrimal pathology in well-characterized Sjögren syndrome patients and NSDE, to further our understanding of natural history and to identify the likely time points for therapeutic intervention.

### 9.1.7. The conjunctiva in Sjögren syndrome

It is not known if the conjunctiva is a primary target of

inflammation in Sjögren syndrome or whether changes in it are secondary to lacrimal gland inflammation and the onset of DED. Much of what is known about the pathologic events in the conjunctiva of patients with DED is based on the study of conjunctival impression cytology specimens, which provide information about the epithelium, but not of full thickness conjunctiva. Therefore, the findings of Stern et al. [488] in conjunctival biopsy specimens from patients with either SSDE or NSDE are of great interest, particularly because there was no qualitative or quantitative difference in infiltrating cells and of activation markers between groups. A summary of inflammatory events in the conjunctiva of patients with both SSDE and NSDE is presented in Table 12.

Stern et al. demonstrated large numbers of infiltrating lymphocytes in both SSDE and NSDE specimens, which were mostly CD4<sup>+</sup>T cells but included CD8<sup>+</sup> cells [488]. T cells were mainly in the anterior substantia propria and subepithelium and rarely in the epithelium. A small number of B cells were also present. Immunoreactivity for major histocompatibility complex (MHC) class II antigens indicated the expression of both HLA-DR (a ligand for the T-cell receptor) and HLA-DQ (an essential accessory molecule for antigen presentation), not only by lymphocytes, but also by conjunctival epithelial cells, indicating a possible role for them as non-professional APCs.

Additionally, ICAM-1 immunoreactivity was detected on vascular endothelial cells, infiltrating lymphocytes in the *substantia propria* and on resident epithelial cells. ICAM-1 is a cell surface adhesion molecule that facilitates lymphocyte homing and entry into target tissues, which is of importance during inflammation [464,730]. Increased expression of lymphocyte function-associated antigen (LFA)-1, the T cell ligand for ICAM-1, was also detected. It was noted that expression of ICAM-1 by resident epithelial cells encouraged cell contact between infiltrating lymphocytes and the epithelial cells, facilitating apoptotic epithelial cell damage and that expression of ICAM-1 by infiltrating lymphocytes could provide a signaling molecule for antigen presentation [731,732].

### 9.1.8. The meibomian glands in Sjögren syndrome

It is not known if the meibomian glands are an autoimmune target in Sjögren syndrome. In a study by Shimazaki et al., patients with Sjögren syndrome were found to have more severe ocular surface changes (as verified by vital staining) even when they had the same tear production (as verified by Schirmer's test) as age-matched NSDE [375]. Sjögren syndrome patients had a higher prevalence of MGD, a higher tear evaporation rate and more severe MGD, (57.9% in the Sjögren group vs. 18.5% in NSDE individuals). The combination of ADDE with MGD-associated EDE is considered to amplify the dry eye state [207].

A greater disturbance of meibomian gland architecture has also been observed by confocal microscopy in SSDE-related MGD than in NSDE, MGD and in healthy controls. Meibomian glands in Sjögren syndrome patients were reported to show more periglandular inflammation and higher acinar cell reflectivity compared to normal controls and MGD patients without Sjögren syndrome [733]. There were no differences between the meibomian glands of pSS and sSS patients. Signs of obstructive MGD were also similar in both pSS and sSS (SLE and rheumatoid arthritis) [1201].

The question arises as to why the prevalence and degree of MGD is higher in Sjögren syndrome. One explanation could be that the meibomian glands are a primary autoimmune target in this disease, although there is no evidence for this possibility. Alternatively, they could be influenced directly by inflammatory cells or cytokines arising locally in the conjunctiva or delivered to the conjunctival sac in the lacrimal secretion [426,687]. Another proposal is that, in severe disease, the loss of reflex sensory drive seen in the lacrimal

**Table 9**  
Rodent models for altered meibomian (MG) and/or sebaceous (SG) gland structure and/or function.

Condition	Glandular effect	Reference
<b>Gene knockout</b>		
Acyl-CoA:cholesterol acyltransferase-1	MG atrophy	(Yagyu et al., 2000) [660]
Autoimmune regulatory	T cell infiltration in MGs	(Yeh et al., 2009) [590]
Barx2	MG defects	(Tsau et al., 2011) [1141]
Blimp1	Enlarged MGs	(Horsley et al., 2006) [1142]
CCAAT-enhancer-binding proteins $\alpha$ and $\beta$	MG atrophy, reduced number of differentiated MG acinar cells	(House et al., 2010) [1143]
CD147	Lower number of MG acini, loss of lipid-filled meibocytes	(Mauris et al., 2015) [1144]
Cu, Zn-superoxide dismutase-1	Increased oxidative stress of the MG acinar epithelium	(Ibrahim et al., 2014) [1139]
Ectodysplasin-A	No MG	(Cui et al., 2005 Wang et al., 2016 Kuramoto et al., 2011) [672,1145,1146]
Ectodysplasin-A receptor	No MG	(Naito et al., 2002) [1147]
Growth hormone receptor	MGs feature hyperkeratinized and thickened ducts containing cornified materials, secretory acini inserting into duct walls, poorly differentiated acini, and reduced MG sizes	(Liu et al., 2016a) [57]
Krüppel-like family 5 (conditional disruption)	Malformed MG	(Kenchegowda et al., 2011) [1148]
Map3k1, Dkk2, c-Jun, Egfr, Shp2, Map3k1/jnk1, Map3k1/Rhoa (systemic or conditional knockouts)	MG hypoplasia	(Meng et al., 2014) [1149]
Melanocortin-5 receptor	Decreased production of sebaceous lipids	(Thiboutot et al., 2000) [1150]
Smad4	Ectopic row of hair follicles in place of MGs	(Huang et al., 2009) [1151]
Stearoyl-coenzyme A desaturase 1	No MG	(Miyazaki et al., 2001) [1152]
Stearoyl-coenzyme A desaturase loss of function (Scd3-Cre-induced, diphtheria chain A toxin-mediated depletion)	MGD-like ocular surface effects	(Dahlhoff et al., 2016) [1153]
Tumor necrosis factor receptor-associated factor 6	Modified MGs	(Naito et al., 2002) [1147]
<b>Transgenic or gene overexpression</b>		
Biglycan overexpression, under control of the keratocyte-specific keratocan promoter	MG aplasia	(Hayashi et al., 2005) [1154]
c-Myc overexpression	Enhanced sebum production	Zouboulis and Boschnakow, 2001) [1155]
Ectodysplasin receptor	Enlarged MGs	(Chang et al., 2009) [1156]
Ectodysplasin-A	SG hyperplasia	(Cui et al., 2003) [1157]
Growth hormone receptor antagonist	MGs feature hyperkeratinized and thickened ducts containing cornified materials, secretory acini inserting into duct walls, poorly differentiated acini, and reduced MG sizes	(Liu et al., 2016a) [57]
Human apolipoprotein C1	MG atrophy	(Jong et al., 1998) [1158]
K14-noggin	Formation of ectopic pilosebaceous units at the expense of MGs	(Plikus et al., 2004) [1159]
Kera-rtTA/tet-O-TGF $\alpha$ (ectopic stromal expression of TGF- $\alpha$ )	Abnormal MG morphogenesis	(Dong et al., 2015) [1160]
Keratin 5 – glucocorticoid receptor	No MG	(Cascallana et al., 2005) [1161]
Rat erbB2 overexpression in basal layer of mouse epidermis, under control of the bovine keratin 5 promoter	SG enlargement	(Kiguchi et al., 2000) [1162]
Rescued fatty acid transport protein 4 null	Abnormal MG development	(Lin et al., 2013) [1163]
Smad7 or parathormone-related protein overexpression	SG hyperplasia	(Zouboulis and Boschnakow, 2001) [1155]
<b>Mutation</b>		
“Rhino”	MG ductal hyperkeratinization, acinar cell loss and eventual atrophy	(Jester et al., 1988) [1164]
“Rough fur” (ruf)	SG hypertrophy	(Park et al., 2001) [1165]
ADAM metallopeptidase domain 17, also called tumor necrosis factor- $\alpha$ -converting enzyme	No MG	(Hassemer et al., 2013) [1166]
Downless locus	MG defects	(Majumder et al., 1998 Naito et al., 2002) [1147,1167]
Elongation Of Very Long Chain Fatty Acids gene	Protruding orifices and anatomical changes in MGs	(McMahon et al., 2014) [1168]
Protein phosphatase 1 regulatory subunit 13 like	No MG	(Toonen et al., 2012) [1169]
Stratifin (14-3-3 $\sigma$ )	MG atrophy in aged heterozygotes	(Lu et al., 2011) [1170]
<b>Immunization</b>		
Murine immunization with a human monoclonal anti-DNA antibody, bearing a major Id 16/6ld	Hypertrophic MGs	Chan et al., 1995) [1171]
<b>Natural</b>		
“Crinkled”	No MG	(Naito et al., 2002) [1147]
Age	MG atrophy	(Parfitt et al., 2013) [1172]
<b>Pharmaceutical</b>		
Isotretinoin	Keratinization and thickening of MG ductal epithelium, decreased number and size of MG acini, multiple degenerated MG acini	(Ibrahim et al., 2017) [642]
<b>Environmental &amp; pharmaceutical</b>		
Desiccating stress and scopolamine	Increase in MG basal cell proliferation	(Suhaim et al., 2014) [656]
<b>Nutrition</b>		
HR-1 hairless mice fed special diet with limited lipid content	Hyperkeratinization of the MG ductal epithelium, toothpaste-like meibum, markedly plugged MG orifices, and loss and atrophy of MG acini,	(Miyake et al., 2016) [637]
n-3 fatty acid deficiency	Decreased MG meibum secretion	(Tanaka et al., 2015) [1173]

gland may similarly affect the maintenance of meibomian gland secretion. A further explanation is the androgen deficiency in Sjögren syndrome (see Sex, Gender and Hormones Subcommittee report).

#### 9.1.9. *The ocular surface in severe SS – squamous metaplasia*

In advanced DED, including Sjögren syndrome, a process of squamous metaplasia can occur in which the moist epithelial mucosa is converted to an epidermalised, non-wettable tissue by a process of transdifferentiation. There is a modification of the epithelial glycocalyx, a loss of goblet cells and keratinization of the conjunctival and corneal epithelia, with the aberrant expression of cornified envelope precursor proteins, including the small proline-rich proteins (SPRRs), involucrin, late envelope proteins (LEPs) and filaggrin.

Squamous metaplasia is a response to chronic inflammation, with IL-1  $\beta$  and IFN $\gamma$  playing a key role in the process. The expression of the relevant genes precedes the squamous phenotype [478]. Both cytokines have been demonstrated in excess at the ocular surface in DED. IL-1 $\beta$  is a potent inducer of inflammation and stimulates the production of many proinflammatory cytokines at the ocular surface, including IL-6, IL-8, TNF- $\alpha$ , and interferons [453]. The levels of IL-1 $\alpha$ , IL-1 $\beta$  and TNF-alpha are increased in the tears and conjunctiva of pSS patients and in animal models of DED [535,734,735] and there is a significant correlation between IL-1  $\beta$  expression by human conjunctival epithelial cells and pathological keratinization of the ocular surface, using SPRR1B expression as a measure of squamous metaplasia [589].

The role IFN- $\gamma$  in the process of squamous metaplasia has been studied. This cytokine is released at the ocular surface by infiltrating Th1 cells and NK cells. It can promote goblet cell loss, epithelial apoptosis and keratinization of the conjunctival epithelium in a DES mouse model of DED [478,530] and is an important contributor to squamous metaplasia in human DED [532]. It has been demonstrated to upregulate the expression of cornified envelope precursors in keratinocytes [736], corneal epithelial cells [737] and in conjunctival epithelial cells from patients with Sjögren syndrome [738,739].

Macrophages and T cells have been studied in mice and humans by McNamara's group. In a series of studies they examined the Aire KO mouse (a Sjögren syndrome model) and human Sjögren syndrome biopsies of conjunctival tissue [580]. These studies have shown that homing of autoreactive CD4<sup>+</sup> T cells to the eyes of Aire-deficient mice promotes both macrophage infiltration and the local release of IL-1 [453]. In adoptive transfer studies, it was shown that autoreactive CD4<sup>+</sup> T cells can initiate local inflammation at the ocular surface by activating IL-1R1 signaling in resident epithelial cells [453,589] which sustains inflammation through the local retention of the infiltrating T cells. Depletion of ocular surface macrophages by the subconjunctival injection of clodronate liposomes [580] decreases the signs of DED, such as lissamine green staining and epithelial SPRR expression, supporting their role in the development of ocular surface metaplasia. Similarly, depletion of APCs during the induction of DES blunted the DED phenotype [479].

IL-1 $\beta$  may also promote squamous metaplasia by inducing the expression of small proline rich proteins (SPRRs) which are minimally expressed in non-keratinized mucosal tissues but become overexpressed in response to stress or inflammation [453,478,740]. Li et al. [453] demonstrated the induction of SPRR by the addition of recombinant IL-1 $\beta$  to cultured human conjunctival epithelial cells, through activation of a p38 MAPK pathway, which appears to be a common intermediate of both the IL-1 $\beta$  and IFN- $\gamma$  signaling cascades. SPRRs have been shown to trap conjunctival goblet cells during DES and also to be upregulated by IFN-gamma [427].

The importance of IL-1 in this process is supported in additional ways. Ocular surface staining and expression of SPRR1B are markedly reduced in Aire KO mice lacking the IL-1 receptor (Aire/IL-1R1 double knockout mice) [589] even though lymphocyte infiltration is not attenuated. Additionally, local inhibition of IL-1 signaling at the ocular surface in Aire-deficient mice, by the topical application of the IL-1 receptor antagonist, anakinra, improved tear secretion, restored ocular surface integrity and reduced keratinization [741]. However, whether these findings can be translated to the treatment of humans remains to be shown. A recent clinical trial with a topical IL-1 receptor antagonist for the treatment of DED was not successful [1209].

## 9.2. *Non-Sjögren Syndrome dry eye*

NSDE includes congenital and acquired forms of DED without the systemic autoimmune features of Sjögren Syndrome. Conditions include age-related NSDE, congenital alacrima and familial dysautonomia [742].

### 9.2.1. *Intrinsic lacrimal deficiency*

9.2.1.1. *Lacrimal gland ablation.* DED may be caused by ablation of the lacrimal gland at any age, or by severance of the ducts during lid surgery. DED is not an inevitable outcome, since the accessory glands and conjunctival secretions may compensate in some cases [743].

9.2.1.2. *Congenital alacrima.* Congenital alacrima or lacrimal agenesis may occur as an inherited disorder [744] sometimes with agenesis of the salivary glands [745] and is a rare cause of DED in youth or infancy. Additional associations are with blepharophimosis [746], lacrimal-auriculo-dental-digital syndrome (LADD), Pierre-Robin sequence [747] and Allgrove syndrome (see below).

9.2.1.3. *Triple A-syndrome.* Triple A- or Allgrove syndrome, is a progressive, recessively inherited disorder, in which congenital alacrima is associated with achalasia of the cardia, Addison's disease, central neurodegeneration and autonomic dysfunction. It is caused by mutations in the AAAS gene, encoding the protein ALADIN [748–750].

### 9.2.2. *Age-related Non-Sjögren Syndrome dry eye*

The most common form of NSDE is age-related ADDE and corresponds to the term keratoconjunctivitis sicca (KCS) cited in the older literature (Lemp 1995). The clinical features resemble those of SSDE, but, in general, age of onset is later, the degree of lacrimal gland infiltration lower, the rate of progression slower and severe disease less common than in SSDE. Evidence for its increased frequency over the lifespan is presented in the report of the Epidemiology Subcommittee. A steady increase in incidence of this form of ADDE is identified from around the age of 50 years.

Aging may be defined as the accumulated changes in structure and function that occur in a tissue or organism over its lifespan. Such changes may contribute to but be distinct from those events that are responsible for age-related disease [751]. According to Rocha et al. [751] theories of aging may be usefully classified as Programmed – involving genetic, hormonal and immunological influences and Damage- or Error-based, involving wear and tear, tissue oxidation and cross-linking, post-translational modification or the consequences of somatic mutation.

Of these factors, the role of hormones is addressed by the Sex, Gender and Hormone Subcommittee, while, in contrast to the situation for Sjögren syndrome, genetic susceptibility has received little attention. In a study of monozygotic and dizygotic female twin

pairs, Vehof et al. found a heritability of 29% (95% confidence interval [CI], 18%–40%) for DED symptoms and of 41% (95% CI, 26%–56%) for DED, based on a physician's diagnosis and concurrent use of artificial tears. However this result derived from the use of a questionnaire, which did not identify the nature of the DED. Apart from this, there have been some small, candidate gene studies in NSDE patients which have reported a possible role for polymorphisms in proinflammatory cytokine genes [752], and in killer cell Ig-like receptor and human leukocyte antigen-C genes [753]. These results have not yet been replicated and a future search for genetic polymorphisms in age-related NSDE will be important to pursue.

**9.2.2.1. Aging of the lacrimal gland.** The potential contributions of tissue aging to this disorder have been reviewed by Rocha et al. [751], who point out that the reported fall in reflex Schirmer values over the life span [754–756] could be due to a failure of any of the elements that go to make up the lacrimal functional unit and therefore to any one of a combination of factors such as a loss of sensory drive from the ocular surface, a reduced delivery of secretory neurotransmitters, as well as the loss of functional secretory tissue. The Schirmer test measures the secretory response of the lacrimal gland to increased sensory drive and information about the influence of aging on lacrimal secretion in the absence of a sensory input from the cornea is not available. There would be some value to explore the effect of aging on the anesthetic Schirmer response or on lacrimal secretion as measured by fluorophotometry, in defined environmental conditions. Hamano et al. [757], inferred a loss of tear volume with age, based on results from the phenol red test.

Corneal sensitivity to mechanical [389,758–760] and chemical stimuli [389,760] falls with age, which could reduce the sensory drive to lacrimal secretion, but an age-related fall in thermal sensitivity (cold or hot) was not detected by Bourcier et al. [389], using the gas aesthesiometer. On the other hand, numerous papers report that the regulated secretion of the lacrimal-derived proteins, lysozyme, lactoferrin and peroxidase fall with age [755,756,761–763] which would be in keeping with a loss of lacrimal gland function.

T cell lymphocytes are among the normal immune cell population of the human lacrimal gland (Table 1). From about the age of 40 years, the glands are increasingly infiltrated by CD4<sup>+</sup> and CD8<sup>+</sup> T-cells, which are considered to be the basis of a gradual destruction of lacrimal acinar and ductal tissue. Histopathologically, a low-grade dacryoadenitis occurs, associated with interacinar and periductal fibrosis, paraductal blood vessel loss and acinar cell atrophy [764–766]. A marked leukocytic infiltration of the human lacrimal gland in older individuals was also recorded by Kojima et al. [767] It has been suggested that the acinar atrophy is secondary to duct obstruction, much as has been proposed for MGD. It is reasonable to suppose that infiltrating inflammatory cells, releasing cytokines and other mediators into the gland, contribute to the lacrimal tissue damage and that, at some point, the cumulative effects of this age-related, structural damage determines the onset of lacrimal secretory deficiency. Studies in MRL/lpr mice, a model for Sjögren syndrome, suggest that pro-inflammatory cytokines, such as IL-1 $\beta$ , released by lymphocytes infiltrating the lacrimal gland, can impair the release of neurotransmitters and inhibit agonist-mediated lacrimal gland secretion [768,769]. If this is relevant to SSDE in the human, it may be assumed that a similar mechanism could operate in age-related DED.

The potential role of viral infections in initiating a self-limiting inflammatory response in the human lacrimal gland and of the sex hormones in favouring a pro-inflammatory environment within the gland, are dealt with elsewhere in this and other reports.

One of the proposed mechanisms of glandular damage over the lifespan is oxidative stress, resulting from the production of reactive oxygen species (ROS) such as superoxide and hydrogen peroxide, in the process of aerobic metabolism. Free radical production occurs in the course of mitochondrial electron transfer as part of the process of energy production. These ROS are normally removed by the scavenging machinery of the cell, by enzymes such as superoxide dismutase (SOD) and reducing agents such as glutathione. Data from experimental studies in mice show that increased mitochondrial superoxide production (as seen in the conditional, Tet-mev1 transgenic mouse) [770] or decreased superoxide scavenging, (as seen in the superoxide dismutase knockout mouse - SOD1<sup>-/-</sup>) [767] cause lacrimal gland damage, associated with increased lipid peroxidation, oxidative DNA damage and inflammatory cell infiltration. This is accompanied by reduced tear volume and increased corneal staining, of greater severity in older animals. Intriguingly such changes do not occur in the salivary glands in the Tet-mev1 model [770]. It is not possible to say whether the corneal changes are a consequence of reduced lacrimal secretion, or to the direct effect of oxidative stress at the ocular surface, but such models suggest that oxidative stress could play a role in age-related DED. It is relevant that, in a comparison of human lacrimal tissue from young (17–48 year) versus old (76–87 year) cadavers, evidence of lipid peroxidation and of oxidative DNA damage was found in the older group [767]. Since activated, phagocytosing leucocytes are potent source of ROS [771] inflammatory cells, infiltrating either the lacrimal gland or conjunctiva, cannot be excluded as the source of this oxidative damage [772] or, of the lipid peroxides demonstrated in the tears of patients with age-related NSDE [773].

**9.2.2.2. Aging of the conjunctiva.** Giebel et al. showed an age-related expression of apoptosis-related genes such as casp-3, Bad, Bax and Bcl-2 in human conjunctival cells obtained by impression cytology [774]. Zhu et al. [775], using confocal microscopy, found an age-related decrease in structures interpreted as dendritic cells but no difference in conjunctival in either epithelial cell or goblet cell density. There was an increase in epithelial microcysts, which have been mooted by some to be the product of goblet cell degeneration [776]. Earlier, Kessing [97], using histology, had reported occlusion of goblet cells with retention of their contents, in older people and Abdel-Khalek et al. [777], observed the presence of hyaline bodies in the conjunctival epithelium in 25% of subjects over the age of 79 years. Overall, such reports suggest that the conjunctiva is relatively resistant to the deprivations of age.

**9.2.2.3. The ocular surface in age-related NSDE.** In age-related NSDE, a reduction in lacrimal secretion dominates the clinical picture and is the basis of tear hyperosmolarity. This results chiefly from loss of secretory lacrimal tissue, but a fall in corneal sensitivity to all sensory modalities, reported in both NSDE and SSDE may contribute to the reduced secretion based on a lack of sensory drive [389]. Conjunctival inflammation is a well-recognised aspect of NSDE, of lesser degree than encountered in SSDE. Its features are illustrated in Table 12. Marked conjunctival infiltration with CD4<sup>+</sup> T cells, expressing HLA-DR, has been reported [488] which likely orchestrate inflammatory events by the release of cytokines such as IFN- $\gamma$ , that can promote goblet cell loss, induce apoptosis and stimulate keratinization of conjunctival epithelium [478] as well as increasing the numbers of IFN- $\gamma$  secreting NK cells [522]. In addition, there is a decreased number of immunosuppressive T-regs and an increase of IL-17 producing T-cells which are involved in damage to the corneal and conjunctival epithelium. Th-1 and Th17 cells have been shown to infiltrate the ocular surface in a mouse model of DED [529]. Th17 cells secrete IL-17 as their signature cytokine,

**Table 10**  
Manifestations in primary Sjögren Syndrome.

Non-specific features
Musculoskeletal symptoms, Raynaud's phenomenon, CNS – Symptoms of Fatigue
Exocrine Epitheliitis (glandular)
Lacrimal and Salivary Glands–
Other glands - pancreas
Parenchymal Epitheliitis (extraglandular)
Bronchial, hepatic, renal - peri-epithelial lymphocytic infiltration
Endocrine Gland Involvement
Thyroid, adrenals, ovaries
Immunocomplex-mediated disease
Vasculitis - affecting small vessels of the skin, nerves, kidney as a result of B-cell hyperactivity)
Lymphoproliferative
B-cell lymphoma

From Ref. [697].

capable of up-regulating MMP-3 and MMP-9 mRNA in corneal epithelium. As has been indicated this cytokine may disrupt the integrity of the corneal barrier.

In keeping with these events, increased levels of inflammatory cytokines and chemokines are also detected in the tears of ADDE patients and these are discussed in detail in the Tear Film Subcommittee report. Their likely source is the conjunctiva but an origin from the inflamed lacrimal gland is also a possibility. Masingale et al. [778], found a correlation between the concentration of tear cytokines and severity of DED. Increased concentrations of IL-6, IL-8, and TNF- $\alpha$  could amplify inflammation by recruiting activated immune cells to the ocular surface [458].

### 9.2.3. Inflammatory and other infiltrations of the lacrimal glands

**9.2.3.1. Sarcoidosis.** Sarcoidosis is a chronic systemic disorder of unknown origin with an estimated prevalence ranging from 1 to 40 cases per 100,000 population [779]. It is characterized by the presence of non-caseating granulomas in multiple organs with the lungs being involved most frequently. Other organs include the spleen, liver, lymph nodes and skin, and the salivary and lacrimal glands [780,781]. Patients with lacrimal gland involvement (up to 63% of the cases) typically show significant enlargement of the gland [782]. The occurrence of DED secondary to sarcoidosis is very common and is consequent to lacrimal gland inflammation [782,783]. Scattered lymphocytic infiltrates are frequent, but, in contrast to those of Sjögren syndrome, do not form foci [784,785]. Elevated levels of circulating proinflammatory cytokines (TNF- $\alpha$ ) are also found [786,787].

**9.2.3.2. Lymphoma.** Infiltration of the lacrimal gland by lymphomatous cells may cause DED [788].

### 9.2.3.3. Viral infection

**9.2.3.3.1. Hepatitis C.** In a study of 321 patients infected with hepatitis C virus (HCV) sicca symptoms (eyes and/or mouth) were noted in 10% of the cases [789]. Several studies showed that patients with chronic HCV infection present extrahepatic manifestations that may mimic the clinical, immunologic and histologic manifestation of primary Sjögren syndrome [790] and in a study of 1020 HCV patients, nearly half the cases (47.5%) had Sjögren syndrome [791].

**9.2.3.3.2. HIV – AIDS.** DED is also a common finding in patients infected with human immunodeficiency virus (HIV) and its prevalence has been estimated at 38.8% [34,792,793]. In AIDS-related DED, unlike the situation in SSDE, there is an infiltration of the lacrimal gland with predominantly; CD8<sup>+</sup> suppressor cells, rather than CD4<sup>+</sup>, helper cells [794].

**9.2.3.4. Radiation injury.** DED may be a complication of radiotherapy for benign and malignant conditions of the orbit [795], or of the head and neck, if the periorbital area is included within the treatment field. Several human studies have reported that the development of DED is dose-dependent [345,795–798]. In summary, published data suggest that doses >57 Gy are predictive of certain DED whereas those <30 Gy are less likely to cause it [795]. Onset of DED symptoms is delayed after exposure, from 4 to 11 years at doses <30 Gy, or between 9 and 10 months after treatment at high doses [795].

The most frequent ophthalmic findings in response to radiation exposure in humans are external eye disorders [799]. As shown in studies of children after the Chernobyl disaster, these findings include decreased lacrimation, and acute and chronic blephar-conjunctivitis [799]. Those children who lived closest to the source of radiation had the greatest degree of aqueous tear deficiency.

In animal studies, there are fewer reports of the effects of radiation on the lacrimal gland than on the salivary gland [800–803]. One study reported the effect of a single dose of radiation (15 Gy) on rabbit lacrimal glands, 3 and 30 days post treatment [801]. In three other studies the effects of single doses of radiation, 2.5–20 Gy, on the lacrimal gland and other ocular adnexa, were studied in monkeys [802], 24–48 h [802,803] or up to 112 days [800] post treatment. A common finding in all these studies was the rapid (24 h) apoptotic loss of acinar and myoepithelial cells. In contrast, ductal cells were either unaffected, at low dose, or were dilated at higher doses and at later time points. Also, at 24 h following radiation treatment, the tissue was infiltrated with neutrophils, which were gradually replaced by mononuclear cells and macrophages. Other reported changes were secretory retention in acini, vacuole formation, extracellular edema and thickening of the basement membrane. One study showed redistribution of the tenascin-C matrix. The severity of the lacrimal gland lesions was dose-related and diminished with time, but the tissues did not recover completely in the longer term. The authors hypothesized that this is probably due to the death of the acinar progenitor or stem cells.

One finding from the study by Stephens et al. [802], was that radiation treatment (24–48 h) did not affect other ocular adnexae, namely the meibomian glands and conjunctival goblet cells. The authors hypothesized that “acute loss of lacrimal gland serous acini and the resulting reduction of tears is alone sufficient to cause DED and could predispose to the development of secondary changes in the other glands of the eyelids”. This hypothesis needs to be tested and this animal model could be a quantifiable model for ADDE.

### 9.2.4. Lacrimal gland obstruction

**9.2.4.1. Cicatricial conjunctivitis.** DED can be a serious outcome in those diseases causing extensive conjunctival scarring, such as chronic graft-versus-host disease, Stevens-Johnson Syndrome (SJS)/toxic epidermal necrosis (TEN), mucous membrane

**Table 11**  
Sjögren syndrome-associated non-HLA genes.

Gene	Gene Function
STAT4	Transcription Factor
IRF5	Transcription Factor
IL12A	Cytokine
BLK	B cell kinase
CXCR5	Chemokine
TNIP	NF $\kappa$ B signaling
GTF2I	Transcription Factor
TNFAIP3	NF $\kappa$ B signaling

From Refs. [694,1174].

pemphigoid and trachoma and also after physical and chemical injury. The DED is of mixed phenotype, due to the combined involvement of the lacrimal and meibomian glands and to ocular surface changes affecting its wettability and secretory capacity. Tear distribution may also be affected. As a consequence, clinical severity is often high and ocular surface inflammation due to DED is compounded by inflammatory events that are part of the primary disorder. At their worst, such conditions may lead to corneal opacification, perforation and blindness. In one UK report of cicatrizing conjunctivitis, OcMMP accounted for 61% of new cases in a single year, SJS/TEN for 20% and other causes for 20% [804]. Some causes of cicatricial conjunctivitis are discussed below.

#### 9.2.4.2. Ocular graft-versus-host disease

9.2.4.2.1. *Introduction.* Allogeneic hematopoietic stem cell transplantation (HSCT) is an effective treatment for hematological malignancies. However, success is hampered by chronic graft-versus-host disease (cGVHD), which can cause death or significant morbidity with a severely diminished quality of life [805]. DED is a major late complication [806–810] and has attracted worldwide attention [806,811–814]. Ocular cGVHD occurs in 40–80% of recipients and presents several months after the date of HSCT. The associated DED is an immune-mediated, inflammatory disorder [489,815].

Reported risk factors for cGVHD include: the presence of peripheral blood mononuclear cells among stem cell sources [816], female to male transplantation [817,818], Epstein-Barr virus in the donor, and previous, acute skin GVHD [818], repeated allo-HSCTs and diabetes mellitus. The occurrence of cGVHD in multiple organs may amplify the severity of ocular GVHD [819].

Chronic GVHD is considered to be a later phase of the acute GVHD reaction, due to host tissue recognition (allo-recognition) by donor T cells, but there may also be an autoimmune element. Accelerated, immune-mediated fibrosis leads to functional changes in the lacrimal gland, cornea, conjunctiva and lid, as well as in additional organs. The main histologic feature of cGVHD-related DED is widespread tissue atrophy and fibrosis, with lymphocytic infiltration. Immune-mediated fibrosis leads to both lacrimal gland duct obstruction [815,820–824] and obstruction of the meibomian gland ducts [825]. Donor-derived fibroblasts may be involved in this process [815,822] and epithelial mesenchymal transition (EMT) [821].

As mentioned earlier, EMT is a process whereby epithelial cells are converted into multipotent mesenchymal stem cells that can differentiate into a variety of cell types. In cGVHD-related DED, cross-reactions between the donor and recipient immune cells generates a “cytokine storm”, which compromises the mucosal barriers on the ocular surface and may trigger EMT at various sites. In the lacrimal gland, under the influence of local T cells, EMT affecting myoepithelial cells is considered to cause severe fibrosis, resulting in gland loss and lacrimal duct obstruction [821]. Epithelial mesenchymal transition in the conjunctival epithelium may disturb wettability by affecting microvilli and the expression of glyocalyx mucins [826]. The ocular features of GVHD are complex and involve an interaction between the lacrimal and meibomian glands and the ocular surface. Manifestations observed using OCT, include abnormal meibomian gland orifices, conjunctival keratinization and chemosis, and corneal epithelial opacification, thinning and sloughing [827].

9.2.4.2.2. *Involvement of the lacrimal gland.* Various events lead to lacrimal gland inflammation and tissue damage in cGVHD. Activated CD4<sup>+</sup> and CD8<sup>+</sup> T cells, present mainly in periductal areas, colocalise with the full complement of surface molecules necessary for antigen presentation, viz. periductal fibroblasts expressing CD34<sup>+</sup> and HLA-DR and adhesion molecules such as CD54<sup>+</sup>, and

costimulatory molecules such as CD40<sup>+</sup>, CD80<sup>+</sup>, and CD86<sup>+</sup> (Fig. 11) [823,828]. Macrophages within affected glands in cGVHD have been incriminated as a source of cytokines and chemokines and of increased oxidative stress, contributing to the cicatrizing lacrimal gland disease.

The tissue renin-angiotensin system (RAS) present in the lacrimal gland may contribute to lacrimal gland inflammation in cGVHD [820]. In a murine model, the frequency of CD45<sup>+</sup> inflammatory cells and HSP47<sup>+</sup> fibroblasts and the expression of fibrogenic molecules, increases in the cGVHD-affected lacrimal gland and is decreased by an AT1R antagonist [829], suggesting that tissue RAS is linked to the inflammatory and fibrotic cascade.

9.2.4.2.3. *Involvement of meibomian gland.* Periglandular meibomian gland changes have been observed in GVHD using confocal microscopy and infrared meibography. Inflammatory cell infiltration, fibrosis and obstruction of meibomian ducts have been reported which are more diffuse than those reported in MGD [825]. Early detection and monitoring of ocular GVHD changes will be feasible using this technique [830].

9.2.4.2.4. *Conjunctival involvement.* The conjunctiva is a recognised target in ocular cGVHD [821,831] and inflammatory cell infiltration together with conjunctival keratinization [824] and scarring are significant features [832], accompanied by local elevation of CXCL9 and CXCL10 chemokines and their C-X-C motif receptor 3 in GVHD-related DED [833].

9.2.4.2.5. *Corneal involvement.* Jabs et al. reported that corneal epithelial thinning and keratinization were the major features of GVHD [824]. Keratinization of the conjunctiva and cornea were attributed either to a primary manifestation of the GVHD or as secondary to the DED state, but it was also suggested that corneal epithelial thinning might be related to chemotherapy preceding transplantation. The GVHD cornea may show severe epithelial damage and the occurrence of early tear film breakup may add to the visual disability. Corneal perforation may occur occasionally and CD8<sup>+</sup> T cells [834] and macrophages have been shown to infiltrate the perforation margin. Matrix metalloproteases, such as MMP2 and MMP9, have also been detected and are assumed to be responsible for tissue loss [835].

9.2.4.2.6. *Findings in the tears.* Changes in the tears in GVHD either reflect or contribute to inflammation at the ocular surface. Tear turnover is reduced and the tear film lipid layer, observed by DR-1 interferometry, can be severely disturbed [836]. In one study, tear osmolality was raised ( $314.0 \pm 22.1$  mOsm/L) and inversely correlated with the TBUT and Schirmer test [837]. INF- $\gamma$  is reported to be elevated in the tears in the early phase of ocular GVHD and IL-6 in a later phase [838] while another study showed that IL-6, IL-10, and TNF- $\alpha$  elevation are strongly correlated with ocular findings [839]. In another study, soluble TNF receptor 1 expression was upregulated [840]. Tibrewal et al. [245], reported an increase in eDNA and NET formation in GVHD in common with other forms of DED.

9.2.4.2.7. *Preclinical models of ocular GVHD.* The pathophysiology of cGVHD has been studied in a number of animal models [489,815,841,842]. Herretes et al. [489] developed a mouse model of ocular GVHD in which donor T cells were recruited to the eyes of the recipients of MHC-matched, allogeneic hematopoietic stem cell transplants. In this model, MHC-matched (H2b) C3H.SW mice were lethally irradiated and several hours later received donor B6 BMCs replete with B6 T cells. Several weeks post HSCT, animals receiving donor T cells lost weight and began to exhibit clinical signs of murine GVHD including ruffled fur, hunching, and diarrhea. Approximately 3–4 weeks following transplantation, increased fluorescein staining was observed in the corneas of recipient mice, which progressed to corneal ulceration by about 6 weeks. There was a difference in the tempo of induction of systemic and ocular

GVHD. In another model, using an MHC-matched, minor histocompatibility mismatched, HSCT, donor fibroblasts derived from mesenchymal stem or stromal cells were shown to contribute to the pathogenesis of immune-mediated fibrosis [815]. Such models offer an opportunity to explore the underlying mechanisms of ocular GVHD.

**9.2.4.3. Stevens-Johnson syndrome/toxic epidermal necrosis.** Stevens-Johnson Syndrome/Toxic epidermal necrosis (SJS/TEN) is a life-threatening, dermatobullous disease that affects the skin and mucous membranes, including the cornea and conjunctiva [843]. Other targets include respiratory, gastrointestinal, hepatic, oral, otorhinolaryngologic, renal and genitourinary systems [844]. The condition involves widespread keratinocyte death and epidermal necrosis, leading to splitting of sub-epithelial layers and epithelial detachment at skin sites and mucosal surfaces. Diagnostically, SJS is distinguished from TEN by skin detachment affecting less than 10% of the body surface compared to a loss of over 30% in TEN. An overlap SJS/TEN syndrome is defined by a loss of 10–30% of skin [845]. SJS affects children and adolescents whereas TEN may occur at any age. The estimated incidence of SJS is approximately 0.4–7 cases per million.

SJS/TEN must be distinguished from another bullous skin disorder, erythema multiforme, which runs a shorter course with limited mucosal involvement. It is triggered by infection, usually herpes simplex virus, as opposed to drugs and other chemical and physical factors, which is more characteristic of SJS/TEN [846].

Antibiotics [847] are a common cause of SJS, in addition to analgesics, cough and cold medications, NSAIDs and anti-epileptics [848] and drugs used in the treatment of gout [849–851]. Doxycycline- and acetazolamide-sensitive cases have also been reported [852,853]. The use of antiretroviral treatment for HIV infection has been a cause of SJS in sub-Saharan Africa [854,855]. Other etiologies include physical agents such as sun exposure and radiation therapy [846]. It may also be idiopathic.

The occurrence of SJS/TEN shows a genetic susceptibility, which is related to ethnic group and may show drug specificity. HLA-B\*1502 is associated with carbamazepine-induced SJS in people of Han Chinese descent [856] and IKZF1 has been identified as a susceptibility gene for cold medicine-related SJS/TEN with severe mucosal involvement, in Japan, Korea, Brasil and India [850]. HLA-A\*02:06 and HLA-B\*44:03C appear to increase the risk of severe mucosal involvement in the Japanese.

Kinoshita and colleagues have proposed that susceptibility to the ocular complications of SJS/TEN is related to an imbalance of mechanisms controlling innate immunity at the ocular surface. This may determine colonization of the ocular surface by bacteria such

as methicillin-resistant *Staphylococcus aureus* (MRSA) or *Staphylococcus epidermidis* (MRSE) after the onset of disease, or be responsible for severe ocular manifestations in TEN [857,858]. Ueta et al. [857], reported a significant role for interactions of HLA-A and the Toll-like receptor 3 (TLR3) gene in the onset of ocular complications and in addition, an interaction between TLR3 and prostaglandin E receptor 3 (PTGER3) [859]. These authors [859] have also reported Gene polymorphisms that influence innate immunity. Sotozono et al. [858], emphasized the importance of NSAIDs and cold medicines in the etiology of SJS/TEN.

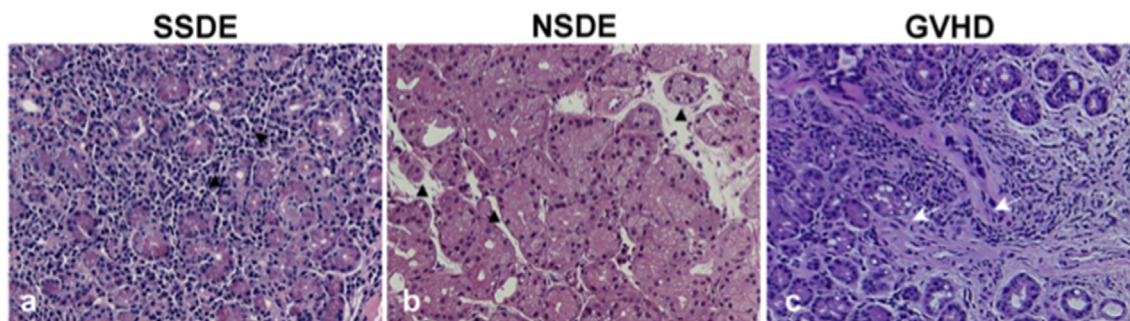
Acute SJS/TEN is generally considered to be a T-cell mediated type IV hypersensitivity disorder and there is strong support for the role of cytotoxic T cells in its pathogenesis [846]. In the early stages of TEN, CD8<sup>+</sup> lymphocytes predominate in the blister fluid and epidermis, many expressing surface markers normally found on NK cells, while CD4<sup>+</sup> lymphocytes are localized to the dermal layers [860]. Later, there is an increase in activated monocytes. Keratinocyte cell death occurs by apoptosis [846,861] either by a FAS/FAS-ligand process or by the delivery of granzyme B to target cells by activated T cells, through perforin-induced channels. Either mechanism activates the intracellular caspase cascade, leading to apoptotic cell death [862].

The acute stage of the ocular disease is characterized by the onset of a membranous keratoconjunctivitis. In the chronic stage of the disease, most patients have conjunctival inflammation, symblepharon, entropion, trichiasis, limbal stem cell deficiency and corneal conunctivalization and neovascularization [863]. There is a close relationship between corneal epithelial stem cell loss and the degree of visual impairment [864].

Various changes have been recorded in the tears of patients with SJS/TEN and IL-17 is elevated, as in other cicatrizing forms of severe DED [865]. A fall in level of two lacrimal-derived proteins, lactoferrin and epidermal growth factor (EGF), is thought to contribute to ocular surface damage [866]. MMP8, MMP9 and MPO were elevated in SJS and the MMP to tissue inhibitor of metalloproteinase ratio was high, suggesting a potential contribution to corneal melting [149].

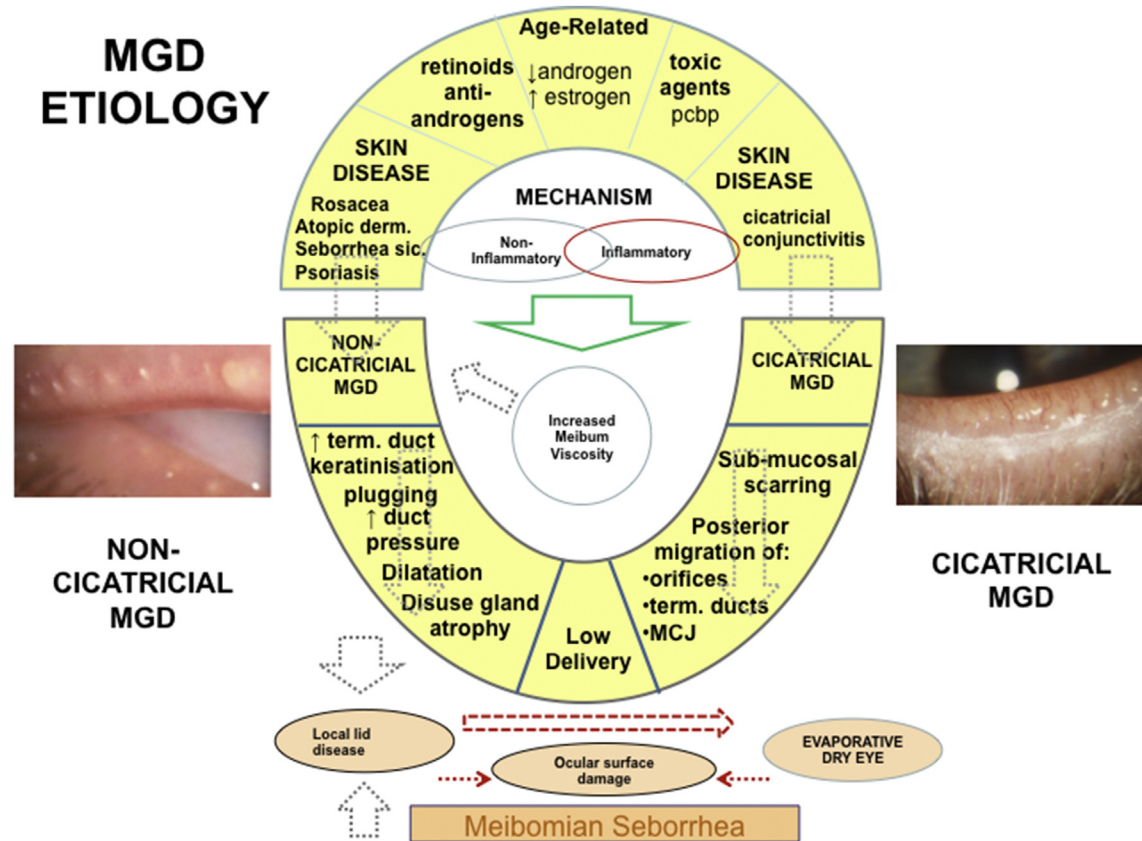
DED is often of extreme severity in SJS/TEN, with a total absence of tear production. In this case the relapsing inflammation induces squamous metaplasia and keratinization of the entire conjunctival epithelium, with decreased goblet cell density [867]. This is associated with epithelial hyperproliferation and expression of transglutaminase I [868–870], and flaggrin [871].

**9.2.4.4. Mucous membrane pemphigoid and ocular cicatricial pemphigoid.** Mucous membrane pemphigoid is a chronic progressive autoimmune, blistering disease, affecting mucous membranes at



**Fig. 11.** Histopathology of the lacrimal gland in various forms of DED. (a) In SSDE there is marked intralobular lymphocytic infiltration (▲) and fibrosis is not apparent. (b) In a patient with NSDE inflammatory cell infiltration is limited and again, fibrosis is scarcely detected (▲). The acini maintain an almost normal structure. (c) By contrast, in a patient with chronic graft-vs-host disease (GVHD) there is marked interstitial periductal fibrosis (arrows) in addition to the lymphocytic infiltration. The periphery of the lobules is irregularly replaced by fibrotic tissue. (Courtesy of Y. Ogawa).





**Fig. 12.** A schematic diagram to show the etiology and mechanism of meibomian gland dysfunction (MGD). Although many mechanistic aspects are not yet understood the figure attempts to summarize the current view. The upper part of the figure illustrates the etiology of the two forms of MGD which result in low delivery of meibomian oil, cicatricial and non-cicatricial MGD. With age, there is an increase in Meibomian gland dropout, particularly after the age of 50 years, which correlates with the appearance of primary MGD. A fall in bioavailable androgens may contribute to these events. In youth, treatment of acne vulgaris with *cis*-retinoic acid may induce gland atrophy and MGD, while in an older age group, androgen receptor insensitivity or blockade may induce signs of MGD. Polychlorinated biphenyls may cause a systemic disorder which includes MGD-like features. Certain skin disorders are strongly associated with MGD. In general, acne rosacea, atopic dermatitis, seborrhea sicca and psoriasis are associated with non-cicatricial MGD, while cicatricial conjunctival diseases such as trachoma, erythema multiforme and pemphigoid, lead to cicatricial MGD. A key event in non-cicatricial MGD is hyperkeratinisation of the terminal duct, leading to duct obstruction, duct dilatation and disuse atrophy of the glands. Later, obliteration of the orifices may occur. Obstruction may be exacerbated by changes in oil composition which increase meibum viscosity. The degree to which inflammatory changes are found around affected glands varies in different reports, but signs of inflammation are common at the lid margin. Inflammatory mediators and lipids may be released onto the ocular surface to cause epithelial damage. In cicatricial MGD, submucosal conjunctival scarring drags the Meibomian orifices, terminal ducts and mucocutaneous junction posteriorly, across the posterior lid border and onto the tarsal plate, where the narrowed and displaced ducts can no longer deliver oil effectively to the TFL. Low meibum delivery and changes in oil composition lead to tear film instability, increased evaporation and ultimately to EDE. In low delivery MGD, symptoms may arise from the local lid disease itself, from lid disease with ocular surface damage and from EDE. In Meibomian seborrhea, gland expression releases abundant quantities of meibum from the gland orifices, which has led to the concept that this is a hypersecretory condition. There is less gland dropout than in obstructive MGD and there are distinctive changes in meibum composition. It is associated with seborrheic dermatitis and is not a basis for EDE.

multiple sites and occasionally the skin. It affects women more than men (F:M 2:1) [872] and usually presents in the later decades of life ( $\geq 60$  years) although it may occur as early as the first decade.

Mucous membrane pemphigoid most frequently involves the oral mucosa (85% of patients) and conjunctiva (65%), and less, the nasal mucosa (20–40%), skin (25–30%), anogenital area/or pharynx (20%), larynx (5–15%), and esophagus (5–15%) [873–875]. Conjunctival involvement is referred to as ocular cicatricial pemphigoid (OCP). Episodes of inflammation and epithelial separation are followed by fibrosis, which may cause life-threatening strictures in the larynx or esophagus or, in the case of the eye, may lead to blindness. Severity, and the number of mucosal sites affected, varies, and the oral form may occur in isolation. In a UK survey, ocular mucous membrane pemphigoid (implying OCP) accounted for 61% of newly diagnosed cases of cicatricial conjunctivitis, with an estimated incidence of 0.8 per million population [804]. An incidence of 1.3–2.0 was reported in France and Germany [876,877].

Genetic susceptibility for OCP is suggested by associations with

HLA B12, HLA A3, HLA-DR4, and HLA-DQB1\*0301 [878,879]. Also, associations with rheumatoid arthritis [880] and Wegener's granulomatosis [881] have been reported. The disease may be triggered or exacerbated by surgery [882] and MMP is occasionally reported as a reaction to drug exposure.

The pathogenesis of MMP involves a loss of immune tolerance to components of the epithelial basal lamina and an antibody-induced, complement-mediated reaction, leading to epithelial detachment [873]. Epithelial separation may result from the cytotoxic effects of inflammatory mediators or from the release of lysosomal proteases [883]. TGF $\beta$  may play a role in the scarring process [884].

Serum autoantibodies have been detected against: bullous pemphigoid antigens (BPAG) 1 and 2. Integrin subunits  $\alpha 6/\beta 4$ , laminin-5, laminin-6, and collagen type I. BPAG2 and  $\alpha 6/\beta 4$  integrins are transmembrane proteins linked by laminin 5 to the epithelial anchoring fibrils, composed of type VII collagen. These elements are important to epithelial attachment. Diagnosis of mucous membrane pemphigoid or OCP is based on the clinical

**Table 12**  
Inflammatory events in the conjunctiva in patients with aqueous-deficient dry eye disease.

Event	Technique Used		mRNA - impression cytology	Findings compared to controls	Type of dry eye disease
	Flow cytometry	IHC or IF*			
Metaplasia		SPRR1 $\beta$	SPRR1 $\beta$ , SPRR2 $\alpha$ , SPRR2 $\gamma$	Increased	(Li et al., 2008, Kawasaki et al., 2003, Pflugfelder et al., 2015) SSDE [532,737,1175]
Inflam-mation			IL-1 $\alpha$ and $\beta$ , IL-6, IL-8, IL-10, TNF- $\alpha$ , and TGF- $\beta$ 1	Increased	Pisella et al., 2000, Jones et al., 1998, Jones et al., 1994) SSDE [471,1176,1177]
		MUC1		Decreased	(Yoon et al., 2007) SSDE [466]
		IL-6		Increased	(Zhang et al., 2016) NSDE [1178]
		IL-1 $\beta$ , TNF- $\alpha$	IL-8,, Ephrin	Increased	(Narayanan et al., 2006) Moderate DED [1179]
Immune Activation			IL-1 $\alpha$ , IL-6, IL-8, TNF- $\alpha$ and TGF- $\beta$ 1 HLA-DR	Increased	(Pflugfelder et al., 1999) SSDE [1180]
	HLA-DR + cells	CD11c + HLA-DR+		Increased in patients, decreased after treatment	(Kawasaki et al., 2003, Jones et al., 1994) SSDE [1175,1177] (Epstein et al., 2013, Baudouin et al., 2002, Baudouin et al., 2005, Brignole et al., 2000, Brignole et al., 2001, Sheppard et al., 2013, Pisella et al., 2000, Tsubota et al., 1999a, Tsubota et al., 1999b, Rolando et al., 2005, Kunert et al., 2000) SSDE and NSDE [471,1181–1190]
T Cell Response	CD4+CXCR3+ cells	HLA-DR CXCL9, –10, and –11, and CXCR3		Increased Increased	(Versura et al., 2011) NSDE [1191] (Yoon et al., 2010) SSDE and NSDE [1192]
	CD4+CCR5+ cells		CCR5	Increased	(Choi et al., 2012, Baudouin et al., 2005) SSDE and NSDE [468,1190]
		IFN- $\gamma$ , IFN- $\gamma$ R, IL-13, IL-13R, MUC5AC		Increased IFN- $\gamma$ and IFN- $\gamma$ R; no change in IL-13 and its receptor, decreased MUC5AC	(Pflugfelder et al., 2015) SSDE [532]
Immune Cell Trafficking	ICAM-1		IL1 $\beta$ , IL-6, IL-23, IL-17, TNF- $\alpha$ , IFN- $\gamma$ , MMP-9, TGF- $\beta$ 1, TGF- $\beta$ 2	Increased	Chotikavanich et al., 2009, de Paiva et al., 2009)SSDE and NSDE [316,456]
			ICAM-1	Increased	(Pisella et al., 2000) SSDE [471] (Tsubota et al., 1999b, Tsubota et al., 1999a) DE [1186,1187] (Jones et al., 1994) SSDE [1177] (Narayanan et al., 2006) NSDE [1179]
MMP Production		MMP-9	MMP-9	Increased	(Uchino et al., 2015, Chotikavanich et al., 2009, de Paiva et al., 2009, Gurdal et al., 2010) SSDE and NSDE [155,316,456,1193]
			MMP-9, Transglutam-inase 2	Increased	(Aragona et al., 2015) SSDE [1194]
Oxidative Stress		HEL, 4NE		Increased	(Wakamatsu et al., 2013) SSDE [1195]
		Peroxida-tion markers		Increased	(Choi et al., 2016) NSDE [1196]
		ROS generation XO ROS scavenging SOD, Cat, GP		Increased Decreased	(Cejkova et al., 2007) SSDE [1197] (Cejkova et al., 2008) SSDE [1198]
ER stress			GPR78, sXBP1	Increased	(Coursey et al., 2016) SSDE [1199]
Other			hBD2 hBD1, hBD3	Increased No change	(Narayanan et al., 2003) NSDE [1200]
			KLK7, CXCL9	Increased	(Kawasaki et al., 2003) SSDE [1175]
			Aquaporin 3; IFN- $\gamma$ R	Decreased	(Kawasaki et al., 2003) SSDE [1175]

Key: \* = biopsy or impression cytology; IHC = Immunohistochemistry; IF = Immunofluorescence; Cat = Catalase; hBD = human defensins; GP = Glutathione Peroxidase; NSDE = non-Sjögren Syndrome dry eye; SSDE = Sjögren Syndrome dry eye; SOD = Superoxide Dismutase; SPRR = small proline-rich proteins; XO = Xanthine oxidoreductase/xanthine oxidase; SOD; KLK7 = Kallikrein 7; GPR78 = 78 kDa glucose-regulated protein; sXBP1 = spliced X-box-binding protein-1. See text for other abbreviations. For a detailed list of biomarkers reported in the tears in dry eye disease, please refer to the Tear Film Subcommittee report.

picture and the demonstration, by direct immunofluorescence microscopy, of linear deposits of IgG and/or IgA and/or C3 in the basal lamina, in a perilesional biopsy.

The presence of CD4<sup>+</sup> T cells and B cells within conjunctival infiltrates suggests the involvement of cellular immunity in OCP [884,885,886], with Th17 lymphocytes playing a prominent role [887]. Langerhans cells expressing costimulatory molecules for T-cell activation (CD86<sup>+</sup>) have been demonstrated [888,889] and connective tissue mast cells are regarded as key players in the fibrotic process [890]. CD14<sup>+</sup> cells among CD45<sup>+</sup> cells are also found in OCP conjunctiva [891].

Additionally, increased expression of macrophage-colony stimulating factor, collagen binding heat shock protein 47, TGF-β1 and IL-4 are considered to enhance both conjunctival inflammation and scarring in OCP [892–895]. In keeping with other ocular surface inflammatory disorders an increase in levels of MMP8, MMP9, MPO has been demonstrated in the tears of OCP patients [149,896], together with IL-8 [896].

The clinical features of OCP include a progressive subepithelial fibrosis, fornix foreshortening, symblepharon, ankyloblepharon, meibomian duct obstruction and DED. Additionally, entropion, trichiasis, and corneal neovascularization and scarring occur. The conjunctival fibrosis resembles that seen in cGVHD and SJS/TEN. It may be staged as: stage I - subepithelial fibrosis, stage II - fornix foreshortening, stage III - symblepharon- and, stage IV - ankyloblepharon and surface keratinization [897].

As in other affected mucosae, the initiating cause of OCP is a separation of the epithelium from the underlying stroma followed by subepithelial fibrosis [898]. Its clinical evolution is slow and diagnosis is delayed compared to that of SJS/TEN, with a median of 225 days elapsing from symptom onset, compared to 7 days for SJS/TEN [804]. Severity may be asymmetrical between the two eyes but the disease usually progresses to involve the palpebral and bulbar conjunctiva bilaterally [899]. The onset of DED is relatively late in the disease. As in other forms of cicatricial conjunctivitis, contributing factors include obstruction of lacrimal gland and meibomian gland ducts, conjunctival goblet cell loss [435], altered expression of epithelial glycocalyx mucins, epithelial keratinization and impaired tear film spreading.

**9.2.4.5. Pemphigus.** Pemphigus is a potentially fatal autoimmune blistering disease of the skin and mucous membranes, with an incidence of 0.1–0.5 patients per 100,000 population per year. It is rare in childhood [900]. It is due to the formation of pathogenic autoantibodies directed against desmosomal proteins concerned in intercellular adhesion. Pemphigus vulgaris (PV), the most common variant, is characterized by circulating IgG antibodies against desmoglein 3 (Dsg3) and, in about half the patients, Dsg1 [901,902].

The characteristic ocular finding in PV is conjunctivitis with hyperemia and mucoid discharge [900]. Conjunctival blisters, erosions, and symblepharon are rare, although conjunctival biopsies may demonstrate similar histopathologic and direct immunofluorescence findings to skin biopsies [903]. Although the ocular manifestations of pemphigus vulgaris may precede oral or skin lesions by several days to months, eye sequelae are generally milder than in OCP and the symptoms usually improve with the institution of systemic therapy. It may be that the self-limiting nature of the ocular changes in pemphigus, compared to OCP, relates to the absence of involvement of the basal lamina [1210].

**9.2.4.6. Trachoma.** Trachoma is a chronic, scarring keratoconjunctivitis initiated by recurrent infections with *Chlamydia trachomatis* in childhood. The scarring complications, which are a cause of blindness on a global scale, usually occur in adulthood and include corneal opacity resulting from tarsal and conjunctival scarring,

limbal stem cell deficiency, and trichiasis. DED is part of the overall picture, resulting from lacrimal gland duct obstruction, goblet cell loss, a cicatrizing meibomian gland obstruction and lid malapposition [904]. In chronic disease, lid thickening is due to a fibrous subepithelial sheet adherent to the tarsal plate [905] whose quantification by *in vivo* confocal microscopy (IVCM) correlates well with histological findings [906]. A variable degree of meibomian gland atrophy was reported by Al-Rajhi [905]. No systematic study of the evolution of cicatricial lacrimal or meibomian gland changes appears to have been conducted.

**9.2.4.7. Chemical injury.** Accidental or deliberate chemical injury to the eyes, e.g., by exposure to acids and alkalis, are a major source of chronic, symptomatic, ocular disability including sight loss which may amount to blindness. It is the basis of considerable personal tragedy. When extensive, the effects of inflammation and tissue destruction may be compounded by DED, due to meibomian gland and ocular surface damage and obstruction of lacrimal secretion. Its numerical importance is indicated by a population-based study conducted in the United States, over a 2 year period, which recorded a mean of 15,865 new chemical burn cases per year, resulting in an incidence rate of 51.10 new cases per million per year [907]. Projecting this figure globally, a minimum of 357,710, burn accidents were predicted to occur per year, worldwide.

This is a major topic in its own right and will not be addressed in any detail by this Subcommittee other than to direct the reader to several excellent reviews of pathophysiology, classification and the influence of topographical extent and severity on prognosis [908–912]. Current approaches rely in particular on an assessment of the extent of limbal injury and the extent and depth of corneal injury [910,911]. Gupta et al. concluded that the subdivision of grade IV injury into a further 3 subdivisions, by Dua [910], was of predictive value compared to the Roper-Hall method [912]. Although there is a general recognition that the DED follows extensive chemical injury contributes to the poor prognosis, there has been little formal examination of its contribution [913]. The subject would benefit from a longitudinal, multicenter study.

### 9.3. Hyposecretory states due to failure of the lacrimal functional unit

This section deals with DED due to lacrimal hyposecretion as opposed to that due to organic disease of the lacrimal gland. In the healthy eye, lacrimal secretion is under the control of the LFU with additional input from higher centres. Secretory output is therefore dependent on the integrity of the afferent and efferent limbs of the reflex arc. The influence of such reflex failure on conjunctival and meibomian secretion is uncertain. The contribution of LFU failure to DED is considered below.

#### 9.3.1. Reflex afferent block

Tear production is under neural regulation and an alteration in the trigeminal inputs from the cornea can cause DED by blocking lacrimal protein, electrolyte and water secretion [13]. Corneal nerve terminals also exert a number of trophic functions, which support epithelial cell proliferation and/or migration [914–916] and possibly immune regulation. A loss of sensory drive can come about in several ways.

**9.3.1.1. Topical anesthetic use.** Bilateral topical proparacaine decreases blink rate by about 30% and tear secretion by 60–75% due to a lack of trigeminal, sensorineural stimulation [217]. The chronic use and abuse of topical anaesthetics can induce permanent damage to the cornea leading to corneal opacity, melting and perforation [917]. It is assumed that DED contributes to these changes, due

at least to the lack of tears and to reduced blinking, but additional factors are likely to be a loss of trophic nerve functions and direct toxicity.

**9.3.1.2. Trigeminal nerve injury.** Damage to the trigeminal nerve, through surgical or accidental injury may occur anywhere along its course, from the trigeminal nucleus, root or ganglion, its ophthalmic branch, and at the ocular surface. The severity of its effects on the eye, depend on the extent of the damage.

**9.3.1.3. Refractive surgery.** Complications due to a disruption of corneal sensory innervation are a feature of refractive surgery, such as photorefractive keratoplasty (PRK) and laser-in-situ keratomileusis (LASIK) [918], in part the result of reduced tear secretion [259,919], a fall in blink rate [259,920], loss of trophic support [921] and changes in tear composition and stability [922]. The clinical syndrome of pain, and of punctate keratitis on the flap has been called in the past, LASIK DED, and is still referred to as such. It occurs in up-to 60% of patients in the first month after surgery, declining in severity over 6–12 months [923,924]. Tear hyperosmolarity has been recorded by one observer [925]. Punctate keratitis on the flap, but sparing the region of the hinge, has supported a causal role for sensory denervation and neuropathic firing from damaged sensory endings – termed LASIK-Induced-Neuro-Epitheliopathy, or LINE, by Wilson [926]. Also, it is suggested, that NGF and other neuropeptides such as substance P or CGRP may be key factors in the syndrome [918]. The two etiologies are not mutually exclusive and it is likely that LASIK DED and LINE can occur together, in which case a clue to the presence of DED is punctate epitheliopathy that it affects both the LASIK flap and the cornea/conjunctiva outside it, in a distribution typical of DED. Further information is contained in the reports of the Iatrogenic Dry Eye and Pain and Sensation Subcommittee reports.

**9.3.1.4. Neurotrophic keratitis.** Neurotrophic keratitis (NK) is a rare disease of the cornea caused by impairment of corneal sensory innervation. The disease is characterized by decreased or absent corneal sensitivity combined with more extensive anesthesia of the globe and including at least the upper lid and nasal mucosa. Neurotrophic keratitis ranges in severity from punctate epithelial keratitis, corneal opacity with superficial neovascularization, severe inflammation and epithelial loss, persistent epithelial defect, and intractable corneal ulceration, which may proceed to perforation [927]. Because the eye is insensitive, diagnosis may be delayed. Although numerous ocular and systemic diseases may cause neurotrophic keratitis, the most common cause is viral infection, particularly, herpes zoster keratoconjunctivitis and rarely, herpes simplex keratitis. It may also be caused by nerve compression. Nowadays it is a less common outcome following surgical intervention for trigeminal neuralgia.

When the ophthalmic division of the trigeminal nerve is affected by H. Zoster, affection of the nasociliary branch of the ophthalmic nerve, heralded by a zosteriform rash at the root of the nose, is a risk factor for Herpes Zoster Ophthalmicus (HZO) [928]. DED is an important feature. In a study of neurotrophic keratitis due to HZO, sensory loss affected the cornea, upper lid and brow on the affected side and also the nasal mucosa, as indicated by a loss of the nasolacrimal reflex [255]. A diffuse punctate keratitis and a marked fall in reflex tear production occurred, the latter attributed to a loss of secretomotor drive from both the ipsilateral cornea and nasal mucosa. A lesser fall in reflex tearing on the contralateral side and a lesser degree of corneal staining, was postulated to be due to a reduction in blink rate and to an effect of cross-innervation on tear production in the fellow eye [255]. It is relevant that, in those patients with HZO without neurotrophic keratitis the nasolacrimal

reflex was intact.

A loss of trophic support is considered to be a feature of neurotrophic keratitis. Such trophic factors, which promote epithelial proliferation and differentiation and corneal healing [929] are expressed by the corneal nerves and in the epithelium and include Nerve Growth Factor (NGF), SP, CGRP, NPY and Insulin-like Growth Factor (IGF-1). They are discussed further in the report of the Pain and Sensation Subcommittee.

Clinically IGF-1 combined with a SP-derived peptide, has shown promise in the treatment of neurotrophic keratitis [930] and in another preliminary study, topical application of murine NGF was effective in healing the cornea and restoring corneal sensitivity in 12 patients with neurotrophic keratitis [931]. This was later confirmed in a larger group of patients with moderate to severe neurotrophic keratitis [932]. A clinical trial of a new hrNGF eye drop is now active in patients with moderate to severe neurotrophic keratitis both in Europe and in the USA.

**9.3.1.5. Contact lens wear.** Contact lens wearers may experience ocular discomfort, frequently interpreted as dryness, as well as variable degree of decreased corneal sensation. The subject is reviewed in the TFOS Workshop on Contact Lens Discomfort [933] and further comment will be found in the report of the Iatrogenic Dry Eye Subcommittee.

### 9.3.2. Secretomotor blockade

**9.3.2.1. Parasympathetic damage.** Damage to the parasympathetic innervation of the lacrimal gland may follow injury to the *nervus intermedius* during surgery for vestibular schwannomas in the cerebellopontine angle. An associated lagophthalmos due to injury of the seventh cranial nerve may compound the resulting DED [934]. DED has also been reported as a consequence of schwannomas affecting the greater superficial petrosal nerve or injury to the nerve at the time of their removal [935,936].

**9.3.2.2. Pharmacological inhibition of lacrimal secretion.** A large number of systemic medications have been reported as risk factors for DED, including antidepressants, anticholinergics, antipsychotics, antispasmodics and antihistamines as well as chemotherapeutics, antihypertensive, anti-arrhythmics, antithyroid agents, opioid analgesics [937,938]. These drugs are used in older patients to treat common conditions in the elderly such as depression, Parkinson's disease and arthritis. Approximately 76% of Americans 60 years or older used two or more prescription drugs and 37% used five or more between 2007 and 2008 [939]. Another study also showed that patients using decongestants, antihistamines, and vitamins have a higher incidence of DED [940]. In addition it may be assumed that reporting the prevalence of DED in clinical trials may be underestimated.

A full account of iatrogenic DED is provided in the report of the Iatrogenic Dry Eye Subcommittee.

### 9.3.2.3. Combined afferent and efferent blockade

**9.3.2.3.1. Familial dysautonomia.** *Familial dysautonomia* (Riley Day syndrome), is an autosomal recessive disorder due to mutations in a gene encoding an IκB kinase-associated protein [941]. Lacrimal dysfunction, DED and corneal damage are major features of the disorder, in which a generalized insensitivity to pain, present from birth, is accompanied by a marked lack of both emotional and reflex tearing. There is a progressive defect in the cervical sympathetic and parasympathetic innervation of the lacrimal gland and of the sensory innervation of the ocular surface, affecting both small myelinated (Aδ) and unmyelinated (C) trigeminal neurons.

#### 9.4. Other disorders

##### 9.4.1. Meige syndrome: blepharospasm and dry eye

Essential blepharospasm is a disease characterized by spontaneous, excessive, intermittent or constant, contraction of the peri-orbital muscles, mainly of *orbicularis oculi*, occurring without other neurological or ophthalmological cause [942]. In Meige syndrome the spasm extends to include other facial muscle, the tongue, the pharynx and the cervical muscles. The cause for the blepharospasm is not known but it may sometimes be drug-induced or associated with brain disease. There are several reports which indicate some relationship between blepharospasm and DED [943,944]. Also it is reported that 57% of DED resistant to treatment is associated with Meige syndrome [945]. In the past, oral psychotropic drugs or orbicular muscle resection have been applied effectively [942,946–948], but in recent years, local injection of Botulinum toxin is considered to be the most effective treatment [944,947,949].

##### 9.4.2. Diabetes mellitus

Patients with diabetes complain of DED symptoms. There is evidence that tear film parameters are altered in patients with diabetes, with a reduction in tear breakup time and tear secretion [950]. DED signs and symptoms have also been found to correlate with degree of peripheral neuropathy and severity of diabetic retinopathy [951]. Factors thought to contribute to reduced tear production in diabetes include microvascular damage to the lacrimal gland from hyperglycemia, reduced lacrimal innervation from autonomic neuropathy, reduction in trophic support to lacrimal tissue, and reduced reflex tearing due to impairment of corneal sensitivity [951]. Reduction in tear film stability and TBUT is likely to be due to reduced mucin production by goblet cells. Goblet cell density is thought to be dependent on corneal innervation, and reductions in corneal innervation have been observed to reduce goblet cell function [952]. This is also implicated in post-LASIK DED [918]. (See also Sex, Gender and Hormones Subcommittee report).

##### 9.4.3. Pseudoexfoliation

Pseudoexfoliation (PEX) is a basal lamina disorder encountered increasingly with age, characterized by the accumulation of clumps of micro-fibrils on the surface of the lens capsule, ciliary body, iris, trabecular meshwork and conjunctiva [953,954]. In PEX patients, both Schirmer test and tear film breakup time were significantly lower compared to a control group [955]. The number of goblet cells per unit area of conjunctiva was no different than in controls, but on electron microscopy, typical pseudoexfoliation filaments were found in the stroma in PEX patients and remarkable changes in mucin packaging and goblet cell morphology [956].

## 10. Evaporative dry eye

### 10.1. Introduction

As noted, all forms of DED are evaporative in the sense that tear and ocular surface hyperosmolarity can only arise in response to evaporation. Hyper-evaporative loss implies that the rate of evaporative loss per unit area of the ocular surface is above the normal range, measured in an individual blinking spontaneously in standard room conditions that do not impose DES.

According to the TFOS DEWS report [1], EDE comes about as a result of a loss of evaporative barrier function of the tears or due to reduced ocular surface wettability. This has led to a sub-classification into lid-related EDE and ocular surface-related DED. The latter form of EDE represents a distinct entry point into the vicious circle whereby tear instability, leading to tear film breakup

in the blink interval (and an OPI <1), is the initiator of tear hyperosmolarity. The existence of hybrid forms of DED, in which include an evaporative component is discussed elsewhere in the report and is summarised in Table 13.

### 10.2. Lid-related evaporative dry eye (intrinsic EDE)

#### 10.2.1. Age-related meibomian gland changes

There is general agreement that meibomian gland acini are lost with increasing age. Arita studied meibomian gland loss by non-contact infra-red meibography in 236 healthy volunteers between the ages of between 4 and 98 years [957]. Gland dropout was expressed as a combined meiboscore for the upper and lower lids of one eye. There were few meibomian gland changes in either males or females younger than 20 years, after which there was a significant dropout with age, without a statistical difference between the sexes. Den et al. [958], reported that the meibomian gland dropout score became positive after 40 years of age and a similar observation was made by Mathers et al. [763], who observed in addition, an alteration in the expressibility of meibum in keeping with obstructive MGD.

Villani et al. [390], using OCT, showed an age-related decrease in number of acini and acinar diameter with age, together with an increased secretion reflectivity and acinar wall changes, in a study of 100 asymptomatic subjects aged 20–83 year. Changes were similar in men and women and were not accompanied by changes in orifice size. They were most marked at 50 and 60 years of age, contrasting with the findings of Arita et al. [959], who observed dropout by meibography from the age of 20 years. Histopathological studies by Obata et al. [624], support the occurrence of acinar atrophy without acinar dilatation, distinct from the outcome of obstructive disease.

Such studies suggest that the loss of meibomian acini with age may on the one hand be caused by a primary, age-related, non-obstructive acinar atrophy and on the other by obstructive MGD. This is in keeping with the observations of Nien et al. [960], at the cellular level of a reduced meibocyte differentiation and cell cycling, together with a reduced expression of the lipogenesis factor, peroxisome proliferator-activated receptor gamma (PPAR  $\gamma$ ) in subjects over 50 years of age. Also, there are known, age-related changes in meibum polar and neutral lipid composition [627]. This article also reports that aging in men and women was also accompanied by a significant increase in eyelid erythema, telangiectasia, scurf, keratinization, irregular posterior margins, meibomian gland orifice metaplasia, and meibomian gland secretion opacity. Both simple atrophy and obstructive MGD could provide the basis for a reduced delivery of meibum with aging, potentially, but not necessarily a cause of tear dysfunction.

#### 10.2.2. The influence of sex hormones on meibomian gland function

Meibomian function is strongly influenced by the sex hormones, particularly androgens (see the Sex, Gender and Hormones Subcommittee report). In brief, androgens stimulate the synthesis and secretion of lipids by the meibomian gland and suppress the expression of genes related to keratinization [36,49,653,961,962]. Conversely a deficiency of androgen action, such as occurs in aging, Sjögren syndrome, antiandrogen treatment and complete androgen insensitivity syndrome, is associated with meibomian gland dysfunction, altered meibum lipid profiles and evidence of decreased tear film stability [36,622,623,628]. The influence of sex hormones and other hormones on meibomian gland function and disease is dealt with in full in the Sex, Gender and Hormones Subcommittee report.

### 10.2.3. Meibomian gland dysfunction

The term meibomian gland dysfunction (MGD) was introduced by Korb and Henriquez in 1981 and has been used for many years to identify the most common etiology of EDE and to distinguish it from other of meibomian gland diseases [963,964]. It is embedded in the literature and provides a convenient label for a well-characterized condition. It may be that in its earliest stages it takes the form of a functional disorder that impairs the delivery of meibomian oil to the lid margin but in the form that presents clinically it is a disease state, which involves pathological modifications to the gland which may be irreversible. The term *obstructive* MGD was coined by Mathers [965]. An excellent review of the history and concept of MGD and its relationship to other forms of blepharitis was published by Blackie and Korb [184].

**10.2.3.1. High meibum delivery state – meibomian seborrhea.** MGD has been sub-classified into high oil delivery and low oil delivery states (Fig. 12). The prevalence of high delivery states has not been reported but it is likely to be uncommon. It is referred to as *meibomian seborrhea* [966] and is encountered in association with seborrhoeic dermatitis and rosacea. Diagnosis has been based upon the manual *expression* of high volumes of meibum from affected glands and inference that it is a meibomian hypersecretory state is an assumption that awaits confirmation. It would be valuable to demonstrate, in patients designated as having Meibomian seborrhea that the condition of high volume expressibility persists over an extended period of time. At present there are no reliable methods to evaluate meibomian secretory rate but TFL thickness was significantly increased in a group of patients with DED associated with hypersecretory MGD and lid margin inflammation [967]. A causal role for hypersecretory MGD and DED is not established.

**10.2.3.2. Low meibum delivery states - obstructive meibomian gland dysfunction.** Meibomian gland dysfunction is the most common cause of low meibum delivery, chiefly due to obstructive disease. Obstructive MGD is the most common cause of EDE [37,180,968] and it is believed that MGD-dependent EDE is the most common form of DED overall [36,376,506,969,970,1066,1211,1212]. It was recently defined at the TFOS Workshop on MGD, as follows and further details may be found in that report [36,506,970]: “*meibomian gland dysfunction (MGD) is a chronic, diffuse abnormality of the meibomian glands, commonly characterized by terminal duct obstruction and/or qualitative/quantitative changes in the glandular secretion. This may result in alteration of the tear film, symptoms of eye irritation, clinically apparent inflammation, and ocular surface disease*”.

MGD may be *primary* or *secondary*. Primary MGD appears spontaneously and has no known disease association. Its prevalence increases with age. Secondary MGD has such an association, for instance with eyelid laxity [971] and eyelid tattooing [544]. In particular, MGD may regularly accompany certain skin diseases such as rosacea, atopic and seborrhoeic dermatitis psoriasis and ichthyosis [966,972] and may be induced by inflammatory disease of the lids and ocular surface and by chemical exposures, including topical benzalkonium chloride-containing topical medications for glaucoma. The manner in which MGD contributes to and is amplified by, DED, is reviewed by Baudouin et al. [385].

MGD exists in *cicatricial* and *non-cicatricial* forms [37].

**10.2.3.2.1. Cicatricial MGD.** In primary, cicatricial MGD, duct obstruction results from elongation, stretching and narrowing of the terminal ducts, so that each orifice and associated duct is dragged from its position anterior to the mucocutaneous junction, into the marginal conjunctival mucosa. As this occurs, the affected terminal duct comes to lie horizontally and is seen as a tell-tale,

elevated ridge in the occlusal mucosa of the free margin of the lid, which represents the dragged terminal ducts exposed under a thinned mucosal epithelium [37]. Primary, cicatricial MGD may affect scattered glands in the same lid exhibiting non-cicatricial MGD. It is probably less common than obstructive MGD but the frequency of its occurrence has not been documented.

Secondary, cicatricial MGD is caused by conjunctival scarring and occurs in cicatricial conjunctival diseases. It may also accompany rosacea and vernal kerato-conjunctivitis. The process is more extensive than in primary disease and the orifices and ducts are dragged into the tarsal mucosa, where, in severe cicatricial disease they may no longer be visible, as they are absorbed into the scar tissue. In both the primary and secondary forms of the disease, even at an early stage when the ducts are still patent, once the orifices have been dragged into the mucosa, and therefore into the region of the tear meniscus, the glands are unable to deliver their oil onto the surface of the tear film. With increasing severity the process leads to duct obstruction. Cicatricial MGD has not been studied histologically and would benefit from clinicopathological study directed specifically at orifices, ducts and glands. The Subcommittee recommends that this avenue should be pursued.

**10.2.3.2.2. Non-cicatricial MGD.** In non-cicatricial MGD, the terminal ducts are obstructed by a process of hyperkeratinisation [494,625] and the shedding of duct lining cells into the duct lumen to form keratotic plugs [36,39,973,974]. The hyperkeratinisation process may be linked to the significantly increased expression of keratin genes in meibomian glands of patients with MGD [505]. Further, it is likely that obstruction is compounded by an increase in meibomian lipid viscosity due to changes in meibomian lipid chemistry, and possibly interactions of lipids with cytokeratin proteins [183,975]. The relative contribution of cell debris and increased lipid viscosity to the obstructive process is not known.

The gland orifices remain located in the skin of the lid margin, initially anterior to the MCJ [37] although, with age they may come to lie behind it as the MCJ migrates forwards [454]. This has therapeutic implications, since, if gland function can be restored, the orifices remain in position for oil delivery. Obstruction is accompanied by a thickening and clouding of expressed meibum, which block the ducts and cause plugging of the orifices. Obstruction leads to secondary, disuse- or pressure-atrophy of the glands [494,976,977], which appears as gland ‘dropout’ on meibography [959]. Gland loss is similar between right and left eyes and correlated between the upper and lower lids. But there are regional differences, with less loss in the upper than lower lid [978,979] and greater losses nasally and temporally [979,980]. Dropout correlates positively with MGD grade and is inversely related to meibomian gland expressibility, TFL thickness and TBUT [959,980–983]. In another report, dropout correlated positively with the OSDI symptom score and ocular surface staining [983]. Of interest, reduced expressibility, consistent with a diagnosis of MGD, may occur in the absence of meibographic dropout [980]. (see Tear Film Subcommittee report for further details).

Non-cicatricial MGD most commonly occurs as a primary disorder, seen with increasing frequency after the age of 50 years [626]. It also has multiple secondary associations, including dermatoses such as rosacea, seborrhoeic dermatitis, and atopic dermatitis [966,972]. Additionally, the retinoid, isotretinoin, used in the treatment of acne vulgaris, causes meibomian gland atrophy in a proportion of patients, which may be accompanied by features of MGD [644,648].

In non-cicatricial MGD, diagnosis is based on the morphologic changes in the meibomian orifices and gland acini observed by biomicroscopy, non-contact meibography and confocal microscopy. The orifices become narrowed and the distinctive ring that surrounds them in health becomes less visible [37,984]. In severe

disease, at a stage when there is increased vascularity and the appearance of telangiectasia at the lid margin, the orifices may be distorted, finally becoming scarred and atrophic. At an earlier stage, features include plugging of the orifices by cellular debris and thickening, clouding or absence of expressed excreta. Histologically, it has been said that there is limited inflammatory reaction [624,625,978], but periglandular inflammatory cell infiltration has been reported in severe MGD, based on confocal microscopy. Infiltrates appear as roundish bodies with high reflectivity, which are reduced in number after intensive therapy with lid hygiene, topical steroids, topical non-preserved artificial tears and topical and oral antibiotics, in a comparative trial against lid hygiene and topical non-preserved artificial tears alone [985]. Hyper-reflective dots have also been observed in Sjögren syndrome-associated MGD [733]. Identification of such dots is required at histological level.

Methods exist to grade MGD [984,986,1206], by scoring the degree of gland dropout (meibography) [959,986,987], the amount of oil in the lid margin reservoir (meibometry) [186,988] and the appearance and spreading characteristics and thickness of the tear film lipid layer (interferometry) [195,989]. Confocal microscopy is being used increasingly to quantify the glandular changes in fine detail [390].

MGD is a symptomatic condition in its own right whose symptoms result from lid involvement and ocular surface inflammation in the absence of increased evaporation [376]. However, with progression of disease, the degree and extent of obstruction results in a reduced delivery of meibum to the tear film [36,180], a TFL deficiency [190,978] and loss of its barrier function [175]. Lipid compositional changes, a reduced spread time and lipid layer instability also play a part in the increased evaporation rate that leads to EDE [195,375,376,965,990,991].

In their summary of the MGD literature, Blackie and Korb have emphasized that, notwithstanding the features of well-established disease, MGD may often present as an asymptomatic condition with normal lid margin appearances at the slit-lamp which, they predict, is a risk factor for progressive symptomatic disease [184]. This form of MGD, which they call *non-obvious MGD*, (NOMGD) was recognised at the outset of the description of MGD [964] and has been noted by other authors [974]. Because there are no overt signs of disease, diagnosis must be based on a change in quality of expressed secretions. In an elderly male population over 60 years of age, a majority had at least one abnormal MGD parameter such as non-obvious meibum quality or visible lid vascularity, where lower lipid quality but not higher vascularity were significantly correlated with advancing age and DED symptoms [992].

Blackie et al. [184] emphasize the need to perform meibomian gland expression on a routine basis in order to detect NOMGD and recommend the use of standardized expression, using their custom-made expression device [993,994]. This offers the added advantage of providing a numerical score for expression, the number of Meibomian Glands Yielding Liquid Secretion (the MGYLS score). It is suggested that DED symptoms may be precipitated in patients with NOMGD in conditions of desiccating or other forms of ocular surface stress, as with contact lens wear [964], or in air-conditioned environments when performing work at video display terminals, so-called “office eye” [995–998].

**10.2.3.2.3. Tear volume in meibomian gland dysfunction.** In the steady state, tear meniscus dimensions such as height, radius of curvature and cross-sectional area are surrogates for meniscus volume and tear volume and flow [170]. They are, as expected, reduced in ADDE [172,477,999–1001]. In a study by Tung et al., tear meniscus height and area were reduced compared to controls, in patients with both NSDE and SSDE, and correlated negatively with epithelial corneal damage [999]. Patients with a tear meniscus height of <210 µm had a relative risk of 4.65 for developing severe

corneal epithelial disease (corneal fluorescein staining > 10) with an odds ratio = 5.59.

It has been predicted that, in MGD-related EDE, with normal lacrimal function, tear flow and hence tear volume and meniscus dimensions will be sustained by compensatory response, driven by the Lacrimal Functional Unit [207]. In keeping with this Tung et al. showed a non-significant difference between normal control values of tear meniscus height and area in a group of symptomatic MGD patients with a reduced BUT [999]. In another study it was concluded that an increase in tear production likely compensates for the loss of meibomian glands in patients with MGD [1002].

**10.2.3.2.4. MGD secondary to systemic chemical exposure.** Also, occurring in rare epidemics, systemic exposure to polychlorinated biphenyls, through ingestion of contaminated cooking oils, causes a chronic disorder with gross and extensive acneiform skin changes, meibomian seborrhea with thick excreta and glandular cyst formation [633,1003].

**10.2.3.2.5. Anterior blepharitis-related MGD.** Meibomian Gland Dysfunction may occur in conjunction with anterior blepharitis, particularly when they are both secondary manifestations of a dermatosis such as rosacea [641,966,1004–1006]. One potential source of inflammation is the commensal bacteria of the lid [1007] whose lipolytic enzymes are capable of degrading meibum, with the production of altered lipid species, such as free fatty acids, that are irritant to the tissues [1008,1009]. McCully and Dougherty [1007] reviewed the plethora of bacterial products capable of inducing inflammation, including lipopolysaccharide (LPS), chemo-attractant lipids such as the aldehyde 4-hydroxynonenal (HNE) derived from unsaturated fatty acids, reactive oxygen species and lipid-derived inflammatory mediators such as arachidonic acid, which are the source of prostaglandins and leukotrienes. The role of microorganisms in the etiology of MGD is not fully established and not all studies report an increased bacterial commensal population or a consistent bacterial profile. A recent report showed significantly higher culture rates for aerobes (especially *S. Epidermidis*) and anaerobes (especially *P. Acnes*) in expressed meibum and the conjunctival sacs of patients with MGD alone, and a more complex bacterial profile compared to controls [63], but in another report, no difference in bacterial spectrum, in either lid or expressed meibum cultures, was found between MGD patients and controls despite the presence of anterior blepharitis in 76% of the MGD patients [1010]. A higher than expected frequency of *P. acnes*-positive meibum cultures reported in meibomitis-related keratoconjunctivitis (MRKC) has been invoked to explain an association with the phlyctenular-like keratitis in young girls or adolescent females, acting through a delayed-type hypersensitivity (DTH) mechanism [1011].

Another cause of anterior blepharitis is the ectoparasite Demodex, which is found increasingly with age on the surface of the human body [1012–1014]. Demodex folliculorum, is found in hair and eye-lash follicles and Demodex brevis, within sebaceous glands including the meibomian glands [1012–1014]. Demodex infestation of the lids is suggested by the presence of cylindrical dandruff around the lash bases [1015] and may be confirmed by demonstration of the mites on epilated lashes. They have been observed non-invasively at the orifices of meibomian glands, by *in vivo* confocal microscopy (IVCM) [1016] but their causative role in MGD [1017] and DED is not established. The subject is reviewed by Cheng et al., [1018].

**10.2.3.2.6. Genetically determined meibomian gland diseases.** DED may be caused by a general absence of the meibomian glands or by diffuse changes in the glands distinct from those that characterise MGD.

**10.2.3.2.6.1. Meibomian agenesis and dystichiasis**

Meibomian glands may be absent or partially absent as a

sporadic condition [1019], or congenitally replaced by an extra row of lashes (distichiasis). Distichiasis may also occur as part of a wider, dominantly inherited syndrome of distichiasis with lower limb lymphoedema, that results from truncation mutations of the fork-head transcription factor, FOXC2 [1020]. A mouse model of this disorder exists, caused by the targeted disruption of FOXC2 [1021].

The meibomian glands may be diffusely affected in certain rare, inherited disorders such as anhydrotic ectodermal dysplasia, epidermolysis bullosa and ichthyosis, and has also been reported in Turner syndrome.

#### 10.2.3.2.6.2. Anhydrotic ectodermal dysplasia

*Anhydrotic ectodermal dysplasia* refers to a group of inherited disorders accompanied by malformations of ectodermal skin appendages such as teeth, hairs, nails and glands, including the meibomian glands. Over 90% of patients show a reduction of eyebrows, alterations of eye lashes and changes to the meibomian glands. Ninety four percent of such patients were reported to suffer from DED symptoms in a large case series reported by Kaercher [1006], who suggested that meibomian gland changes, detected by meibography, are the most reliable ocular sign of ectodermal dysplasia. It is likely that the meibomian epithelial cells are affected directly by the genetic defect and that the gland and ducts are affected diffusely.

The syndrome of Ectrodactyly (split-hand or foot), Ectodermal dysplasia, and Clefting (cleft lip and/or uvula and palate)-(EEC), is caused by mutations in the DNA-binding region of the gene p63, controlling a transcription factor active during embryogenesis and concerned with stem cell differentiation in stratified epithelia. It may occur sporadically or be inherited as an autosomal dominant disorder with variable phenotypic expression and penetrance. The condition is well reviewed by Di Iorio et al., [1022] who found an absence of the meibomian glands in almost 100% of their cohort and reduced aqueous secretion in 60%. Lacrimal drainage obstruction (including absence, stenosis or occlusion of the puncta and/or canaliculi) is reported in 59%–100% of cases. The major cause of visual morbidity, giving rise to a dense vascular keratopathy, is limbal stem cell deficiency, which was seen in 60.9% of the Di Iorio series.

#### 10.2.3.2.6.3. Epidermolysis bullosa

EB describes a spectrum of genetically-determined, bullous, mucocutaneous disorders, characterized by fragility and rupturing of the skin in response to friction or mild mechanical trauma [1023,1024]. The level of ocular involvement generally parallels that of the skin and consists of recurrent corneal and conjunctival erosions and scarring and, in the case of the conjunctiva, symblepharon. Repeated corneal and conjunctival blistering can lead to corneal abrasion, punctate keratopathy, symblepharon, ectropion, entropion, and corneal scarring, with reduced visual acuity and even blindness [1025–1028]. Tong et al. [1029], reported the incidence of ocular complications to be 4% in the dominant form of dystrophic EB (DDEB), 12% in the most common and mildest form, EB simplex, (EBS), 40% in junctional EB (JEB) and 51% in the severe, recessive form of dystrophic EB (RDEB). Of these, junctional EB and RDEB are less common than DDEB and much less common than EBS.

Subtypes of EB result from mutations affecting the functional integrity of the dermo-epidermal junction and of the equivalent region of the mucosa. They are designated according to the ultra-structural level of the blister formation. In the most common form, EBS, separation occurs within the basal layer of the epithelium, with less likelihood of scarring than in recessive form, where cleavage occurs at the level of the anchoring fibrils [1030]. In JEB the level of cleavage is within the lamina lucida of the hemidesmosomal complex and results in defective epithelial adhesion. One form of JEB (JEB Herlitz), results in extensive disease and death

in infancy [1031].

The frequency of lid abnormalities in children with EB, was based in the past on retrospective studies [1030] and confined to comment on the presence or absence of 'blepharitis' [1032,1033]. This has been reported to vary from 0.37% to 17.65%, depending on EB subtype [1034]. Jones et al. [1030], point out that the National EB registry reports blepharitis as an uncommon finding, with highest frequencies in RDEB inversa and severe, generalized RDEB (approximately 18% in each) and in JEB subtypes (6%–7%) [1034]. In contrast, Jones et al. [1030], in a large prospective study from Great Ormond St. London, reported a high frequency of MGD in all subtypes of EB with the greatest frequency and severity in the more severe forms, particularly RDEB and JEB. In this carefully conducted study, diagnosis of MGD was based upon the findings of gland orifice plugging and capping, lid margin telangiectasia, lid margin rounding, and retroplacement of the mucocutaneous junction. Because of the problems associated with lid manipulation, it was not possible to perform either gland expression or meibography in this group of patients. The authors were not able to determine whether MGD was of primary origin or secondary to the EB-related ocular surface disease but they emphasized that once established, it must contribute to the frequency and severity of ocular surface disease by means of lid- and DED-related mechanisms and therefore demanded treatment in its own right.

#### 10.2.3.2.6.4. Ichthyosis follicularis, atrichia and photophobia syndrome

(IFAP) is a rare X-linked disorder characterized by a non-cicatricial alopecia, with absent eyebrows and lashes, with photophobia of neonatal onset and a generalized cutaneous follicular hyperkeratosis. It is an inherited disorder of lipid metabolism. Disease severity ranges from mild skin disease to severe variants with multiple extracutaneous features (brain anomalies, retardation, ectodermal dysplasia and skeletal deformities [1035]).

The typical skin finding in IFAP is of 'thorn-like', follicular projections which impart a nutmeg-grater feel to the affected skin. Hyperkeratoses are sometimes seen over the elbows, knees, and dorsal fingers, while the palms and soles of the feet, the teeth, nails and sweat glands are unaffected [1035,1036]. Hair shafts and sebaceous glands are lacking [1036–1039], suggesting a failure of development of the pilosebaceous unit and Eramo reported plugged and irregularly spaced meibomian glands in an affected boy, aged 3, suggesting the presence of MGD or related meibomian gland disease [1036]. It is not yet certain whether meibomian glands as such are even present and this aspect of the disorder deserves comprehensive review. Histopathology of leg skin in this patient showed that the central lumen of all hair follicles contained only keratotic debris. There were no sebaceous glands or normal hair shafts. Well-developed sweat glands were present and mild mononuclear perivascular infiltrates. In female carriers, the trait may be non-penetrant or present with minor features.

Photophobia in this condition is likely to be due to keratitis, probably with a contribution from the MGD. Punctate epithelial erosions, pannus and progressive corneal vascularization and stromal opacification may lead to severe visual loss [1038].

IFAP is caused by mutations in the gene MBTPS2 (membrane-bound transcription factor peptidase, site 2 (S1P), located on chromosome Xp22.1 [1040], which is involved in the regulation of lipid biosynthesis. Oeffner et al. demonstrated a genotype/phenotype correlation between clinical severity and the effect mutations on peptidase activity [1041]. As discussed elsewhere in this report (Section 4.3), the proteases S1P and S2P work cooperatively to activate SREBP transcription factors and target a broad range of genes engaged in cholesterol and fatty acid metabolism. This is in keeping with the failure of pilosebaceous development in this condition apparently also affecting the meibomian glands.



A related disorder, also inherited as an X-linked trait and due to mutations in MBTPS2, is Keratosis Follicularis Spinulosa Decalvans (KFSD) [1041,1042] which, like IFAP, exhibits the combination of follicular ichthyosis, alopecia and photophobia, but differs by reason of a later onset of and more patchy distribution of alopecia in KFSD. The occurrence of atrophy and scarring of follicles is a later feature and the cicatricial alopecia contrasts with the scar-free alopecia of IFAP. Also, hyperkeratosis of the palms and soles and dorsal fingers occurs in KFSD but not in IFAP [1035]. Fong et al. [1035], reported an overlap in clinical and molecular features between IFAP and KSFSD.

### 10.3. Disorders of lid aperture, congruity and dynamics

A newly reported variant of nocturnal lagophthalmos, inadequate lid seal [544], refers to the inability of apparently closed lids to exclude air from the ocular surface during sleep. It may be responsible for symptoms occurring immediately upon rising. Diagnosis is made with a “light test”, using a transilluminator pressed against the closed lids. A strong correlation between a positive light test and symptoms immediately upon waking was reported in a Level 2 study.

As noted earlier, incomplete lid closure of some degree is not uncommon in normal subjects during blinking [343,409]. In normal subjects, increased ocular surface exposure and evaporation occurs in upgaze [288], so that DES may be imposed in the workplace by activities that demand attention by attending to goods placed on high shelves and to extreme elevation of the globes while the head is inclined downward as when taking aim when playing billiards. Elevations on the surface of the globe, close to the limbus, may also impair tear spreading and cause localized drying and dellen formation [1043,1044].

Incomplete lid closure or lid deformity, leading to increased exposure or poor tear film resurfacing, is accepted as a cause of ocular drying following a VIIth cranial nerve palsy (lagophthalmos) or after surgery to the lids [1045]. The relationship between VIIth cranial nerve palsy and the development of MGD [1046-1048] is of particular interest and its mechanism deserves further study. Wan et al. showed a clear correlation between the duration and severity of VIIth n. palsy and the onset and evolution of MGD [1048]. Tear breakup time was reduced in all groups of VIIth n. palsy.

An increase in palpebral fissure width or globe prominence exposes the tear film to greater evaporation [1049] and the risk of ocular desiccation and tear hyperosmolarity. In Graves' orbitopathy (GO), the effect of proptosis on exposure is compounded by lid retraction and lid lag, incomplete blinking or lid closure and by restriction of eye movements, each of which may compromise tear spreading [197]. Kim et al. found an increase in meibomian gland dropout in GO, correlating with a shortened TBUT, the degree of exophthalmos and palpebral aperture height [1050]. Increased gland dropout is also encountered with ocular prosthetic use [1051] and there is also an association with lid laxity [1052], with DED features including a decreased Schirmer score, reduced TBUT and increased corneal staining [971]. A parallel may be drawn between these conditions, with the proposition that gland dropout may be the consequence of meibum stasis due to incomplete or imperfect blinking. A contributing factor could also be the action of tear hyperosmolarity and inflammatory mediators, at the apex of the tear menisci, close to the terminal meibomian ducts [451].

#### 10.3.1. Other blink-related disorders

A reduced blink rate is potential basis for DED in Parkinson's disease (PD) and in progressive ophthalmoplegia [1053], where, in addition, the spreading of tears is impaired by an altered blink action and a reduction in eye movements. Other contributing

factors in PD include reduced meibomian oil delivery, decreased reflex tearing due to autonomic dysfunction [1054] and possibly effects of androgen deficiency on the lacrimal and meibomian glands [1055].

### 10.4. Ocular surface-related evaporative dry eye

#### 10.4.1. Allergic eye disease

Ocular allergies include a variety of clinical conditions (namely Seasonal Allergic Conjunctivitis-SAC, Perennial Allergic Conjunctivitis- PAC, Vernal Kerato-Conjunctivitis –VKC and Atopic Kerato-Conjunctivitis – AKC) ranging from mild, to severe and sight-threatening ocular diseases.

Although the pathophysiology of allergic eye disease, unlike that of DED, involves mostly a Th2 lymphocyte mechanism, these conditions may share some clinical and biochemical features.

Thus:

- a) In each, the conjunctiva is hyperaemic or inflamed, the corneal epithelium may be damaged and the corneal nerves affected; the tear film is rich in inflammatory cytokines, mediators and neuro-mediators that can initiate and maintain a chronic inflammation. Meibomian gland dysfunction is reported as a feature of allergic eye disease [1056] and may be a source of DED. Fibrosis and scarring are common outcomes in severe allergic conditions such as AKC and VKC as a result of a long-standing inflammation.
- b) Mucosal hyper-responsiveness to non-specific environmental stimuli has been described in both ocular allergy and DED. Patients with VKC show hyper-responsiveness to non-specific, non-allergic challenges such as histamine, air pollution or other environmental agents [1057-1060]. Similarly, in DED, both in experimental models and in humans, signs of ocular surface damage are induced by oxidative stress [767,770,772] or commonly encountered environmental factors such as air conditioning and dust, or pollutants such as smoke [772,1061].
- c) Both allergy and DED show a favorable response to topical anti-inflammatory agents such as steroids and cyclosporine. Artificial tears, that are routinely used for DED patients may improve symptoms in all the clinical varieties of ocular allergy [1,770,1062,1063].
- d) Both conditions have a negative impact on the quality of life as they evolve. In particular, increasing discomfort and a reduction of the visual function may be present in the severe forms of each disease, particularly when performing visual tasks requiring continuous attention (e.g. driving, reading, computer work and attention at school).

By contrast, ocular allergy and DED represent two different clinical entities with distinct immune cells involved in their pathogenic mechanism and a different histopathology (for instance increase of goblet cells in allergy [1064] and decreased numbers in DED [434]. Ocular allergy is a disease of youth while DED is more common at an older age when signs and symptoms of allergy generally disappear. They also differ in the quality of symptoms experienced, with allergic patients complaining in particular of itching and photophobia and DED patients of grittiness and foreign body sensation.

Intense itching is typical of VKC and together with photophobia, is the constant and major symptom of allergic eye disease [1065]. Although it is sometimes listed as a symptom of DED, its frequency intensity and topographic reference are not described. It would be of interest to know whether it is a symptom of DED secondary some form of blepharitis rather than, specifically, to DED itself.

**Table 13**  
Hybrid subtypes of dry eye disease.

Subtype	Example
Organic ADDE due to lacrimal gland pathology, combined with an organic, MGD-dependent EDE	In Sjögren syndrome
A combination of an organic ADDE, MGD-dependent EDE and EDE secondary to ocular surface disease.	GVHD or to varying degrees, other forms of cicatrizing conjunctivitis. There is obstruction to the lacrimal gland ducts, cicatrizing MGD and ocular surface disease secondary to the primary systemic disease.
Organic ADDE with a functional EDE	In severe ADDE there is defective spreading of the TFL and a predicted functional EDE
Organic EDE with a functional ADDE.	When DED is severe, there is a fall in corneal sensitivity. It is predicted that, in EDE, this leads to a loss of compensatory, sensory drive to the lacrimal gland, and a functional aqueous-deficient state.
ADDE evolving to EDE	When tear break up occurs within the blink interval, the cornea is subjected to excessive evaporation at the site of the breakup. Thus any ADDE of sufficient severity is predicted to be converted to an EDE. Tear proteins of lacrimal origin should be at a normal level.

Corneal involvement in the form of a diffuse punctate keratitis or a shield ulcer is typical of the severe forms of allergy. Conversely, DED is associated with a different fluorescein pattern including the involvement of the interpalpebral and most exposed ocular surface [74,1066].

A few biological markers of inflammation may be common to both DED and allergic eye disease but eosinophils, eosinophil-derived products and mast cells are typical findings in allergic eye disease [543,1067,1068]. Their absence in a patient with ocular surface symptoms is against a diagnosis of allergic eye disease, but their presence does not exclude DED. Demonstration of a shortened tear film breakup in patients with allergy biomarkers would support the presence of both conditions [1069]. A few clinical entities exist, such as that occurring in young women with polycystic ovaries, who show features of both conditions [1070]. Although the mechanism for this is not established, it is likely that sex hormones and insulin resistance play a part (see Sex, Gender and Hormones Subcommittee report).

Allergic eye diseases and DED are distinct clinical entities but some overlapping features suggest a complex interaction of mechanisms involving the immune, endocrine and nervous systems.

#### 10.4.2. Vitamin A deficiency

Vitamin A regulates epithelial growth, cell proliferation and differentiation [1071,1072]. Systemic vitamin A insufficiency remains an important cause of childhood mortality and blindness in much low-to middle income countries [1073,1074]. In the eyes, vitamin A deficiency induces xerophthalmia [1075], which includes night blindness [1076], conjunctival xerosis [1077], Bitot's spots [1078–1080], corneal xerosis [1081] and keratomalacia [1077]. Two forms of DED are recognised and may occur together. One is due to defective ocular surface wetting and the other to lacrimal gland insufficiency [1082]. Poor wetting can be caused by a defective epithelial glycocalyx at the ocular surface, to a loss of goblet cells and of glycocalyx mucin, and finally to ocular surface metaplasia and epithelial keratinization. Paradoxically, in current times, xerophthalmia may be encountered in developed countries

following bariatric surgery for obesity, due to decreased vitamin A absorption from the small intestine [659].

Vitamin A deficiency in the animal model can induce epithelial keratinization and squamous metaplasia (with Bitot's spot formation) [1083,1084] and also a profound decrease of conjunctival goblet cell density [1077,1083,1085]. Vitamin A is involved in the biosynthesis of glycoconjugates and is involved in mucin glycosylation in the ocular surface epithelium [1086,1087]. There is evidence of abnormal mucin synthesis in vitamin A deficiency. In the rat model, membrane-associated mucin rMUC4 mRNA and secretory mucin rMUC5AC mRNA were not detected in vitamin A deficient animals [1088]. In the human conjunctival epithelial cells, retinoic acid is associated with upregulation of MUC16 through an action on secretory phospholipase A2 Group IIA [1089]. Additionally, in a primary human corneal limbal epithelial cell culture model, retinoic acid stimulates MUC1, MUC4 and MUC16 expression and improves glycocalyx barrier function in a dose-dependent manner [1090]. Retinoic acid also destroys the meibomian gland. Please refer to the Iatrogenic Dry Eye Subcommittee report.

#### 10.4.3. Short breakup time dry eye

The term *short breakup time DED* (SBUDE) refers to a symptomatic form of DED with a fluorescein breakup time of  $\leq 5$  s, occurring in the presence of a normal tear secretion and tear clearance, normal Meibomian gland function and unassociated with epithelial damage [1069]. Symptoms include those of dryness, ocular fatigue and blurred vision, with a substantial effect on the quality of life (QOL).

In the study of Yamamoto et al., in those patients presenting with a "spot type" of breakup ( $= 0$  s), females were affected more commonly than males (ratio 3:1), with a peak frequency of 60 years in women and 20 years in men [1091]. SBUDE appears to be a common form of DED in the workplace in Japan. In the Osaka study of office workers engaged in prolonged work at VDTs 244 out of 303 recruited subjects (80.5%) were diagnosed with SBUDE [1092], which was highly symptomatic [165] and associated with a decreased functional visual acuity [298], quality of life [1093,1094] and loss of productivity [442]. Its elucidation is of high priority.

The mechanism of SBUDE is not yet established but current research suggests that it is precipitated by defective wetting of the ocular surface. In a study comparing patients with SBUDE or ADDE with normal controls, patients in each group had a fluorescein breakup time  $\leq 5$  s and MGD was excluded [425]. Neither Schirmer test values nor vital staining scores differed significantly between subjects with SBUDE and healthy controls. The expression of mRNA for both MUC1 and MUC 16 was significantly lower in patients than controls, but there was no difference between the two patient groups, implying that a loss of wettability was likely to have played a similar role in each group. Curiously, conjunctival impression cytology showed no significant differences in goblet cell density or level of squamous metaplasia among the 3 groups. Where it has been assessed, the tear film lipid layer is normal prior to breakup, too, suggesting that breakup is not triggered by a tear lipid deficiency. The source of symptoms in the absence of significant ocular surface staining is also intriguing and for the present it is assumed to relate to surface hyperosmolarity induced at the site of breakup.

In a study of 96 Japanese office workers working regularly with VDTs, the prevalence of definite and probable DED was 9% and 57%, respectively. The mean MUC5AC concentration was lower in the tears of VDT users with definite DED than in those with no DED and the mean MUC5AC concentration in tears was lower in the group that worked longer hours [1095]. Also, MUC5AC concentration was lower in subjects with symptomatic eye-strain than in asymptomatic individuals [1095]. These results, together, suggest that the circumstances of prolonged VDT use induce changes in mucin

expression that reduce ocular surface wettability and contribute to DED symptoms in this community. The pattern of tear breakup in SBUDE is of the so-called ‘spot’ or ‘dimple’ variety and studies are underway to explore whether these patterns are particularly related to surface mucin deficiency [178]. So-called, ‘line’ and ‘area’ breakup pattern are associated with ADDE, with *line* breakup seen in mild to moderate ADDE and *area* breakup in severe ADDE.

Some success in the treatment of SBUDE is claimed for topical diquafosol sodium, a purinergic agonist which stimulates conjunctival water and gel mucin production [1096], and also with rebamipide, which is reported to increase goblet cell density and also, gel mucin production [1097,1098]. Both agents are claimed to increase the expression of membrane-associated mucins. (See the report of the Management and Therapy Subcommittee for further details).

#### 10.4.4. Ocular surface disease due to topical agents

(See the Iatrogenic Dry Eye Subcommittee report.)

### 11. Summary and recommendations

The Subcommittee has reviewed how the physiology of the ocular surface is affected by and influences the onset and evolution of DED. There is good information about the control of lacrimal secretion in humans but less about that of the Meibomian glands, surface epithelia and goblet cells. Methods to measure their secretory performance *in vivo* are needed.

The structure and function of the precorneal tear film is still under intense scrutiny. One current opinion suggests that the tear film lipid layer alone is not a major barrier to water loss and that its chief role is to stabilize the spreading tear film. It is nonetheless still considered that deficiency and instability of the lipid layer enhances water loss sufficiently to generate clinically important hyperosmolarity at the ocular surface and that this contributes to ocular surface damage in DED.

The question whether there is an aqueous subphase immediately deep to the TFLL, as proposed by Wolff, is still debated. Clinical observation suggests that the fluid drawn into the menisci from the nascent tear film, in the upstroke of the blink, is more watery than the precorneal film itself and it seems likely that an aqueous layer is retained between the TFLL and the subjacent mucoaqueous layer whose behavior is distinctly gel-like. The mucoaqueous layer, deposited over the cornea during the blink, is derived chiefly from the upper tarsal conjunctiva and is likely to differ from that which coats the exposed bulbar conjunctiva, which must arise from both the bulbar and tarsal conjunctiva. This may be of relevance to SLK. In healthy eyes, zones of meniscus-induced thinning may be imprinted onto the precorneal tear film in various gaze positions and be associated with tear instability, threatening its integrity. This phenomenon should be explored further in healthy eyes in conditions of DES as well as in patients with DED.

It has been hypothesized that the physiological line of conjunctival staining, called Marx’s line, is due to a region of hyperosmolarity at the meniscus apex. Increased permeability of the epithelium, also postulated at this site could give pro-inflammatory proteins access to the terminal Meibomian ducts, explaining the association between the forward movement of Marx’s line with age and the occurrence of MGD. It would be worthwhile to study the composition of the glycocalyx at this site (expressed mucins and of galectin-3) and of layer 1 tight junctions in human samples. Its permeability might be explored using fluorescent dextrans.

Partial blinks are not uncommon in both normal and dry eyes but occur more frequently in DED. Because of their effect on evaporative loss this is important to the DED mechanism. It may

also direct the occurrence of punctate epitheliopathy to the lower part of the globe in DED states.

The tear film is spread over the exposed ocular surface by the blink, but eye *movements* also contribute to its deposition over the peripheral cornea and bulbar conjunctiva. Shearing events between the globe and the upper or lower lid wiper are likely to differ, with friction directed more to the upper lid wiper by the blink and more to the lower lid wiper by downgaze, with horizontal gaze movements making additional contributions. This probably explains how lid-wiper epitheliopathy affects both the upper and lower lid margins. Friction delivered by the blink will be greatest in the mid-zone of the upper lid where the linear velocity of the excursion is greatest.

The physical concepts of boundary lubrication and hydrodynamic lubrication are being usefully applied to the dynamics of lid and globe movement. A new boundary lubricant, lubricin, of corneal and conjunctival epithelial origin, has recently been described and may be of importance in DED. A deficiency of aqueous tears and the loss of ocular surface lubricants in various forms of DED are likely explain the increased frequency of punctate epitheliopathy, SLK, filamentary keratitis and LWE in DED and the symptoms associated with these conditions. It could also explain the sensations of lid heaviness and the difficulty in opening the eye on waking, in DED.

The epithelial glycocalyx is an integral component of the apical membranes of surface epithelial cells. Its molecular composition is now better known. It imparts wettability to the ocular surface and explains its lubricative and some of its barrier functions. The contribution of intercellular tight junctions to this barrier is also well understood. The epithelium turns over continuously and as old cells mature and die, the integrity and barrier function of this layer for these cells is lost. It is likely that frictional forces between lids and globe during blinking and eye movements participate in the shedding process. Although epithelial shedding is said to be increased in DED, the shedding rate does not appear to have been measured formally. The loss of barrier function in pre-shed cells is hypothesized to account for a low level of punctate staining of the normal corneal and conjunctival epithelium. About 17% of normal corneas show some degree of punctate staining after the instillation of 0.125% of fluorescein and it is assumed that, over a period of time, all corneas do so. The temporal aspects of such staining in an individual are worthy of further study. We recommend that, in clinical trials, zero staining should not be the default for normality. Because stainability is dependent on instilled dye concentration and the time of reading, methods of grading should be standardized.

Modeling considerations suggest that in healthy eyes the tear osmolarity of the menisci is slightly lower than that over the exposed ocular surface and that this discrepancy increases with increasing meniscus hyperosmolarity in DED. It is further predicted that, in DED, a wave of hyperosmolarity, driven by evaporative loss, spreads from the epicentre of a tear breakup, reaching high levels, of pathological and symptomatic consequence at the ocular surface, which will not be fully reflected by meniscus sampling. The earlier the onset of breakup in the blink interval, the longer the period of exposure to hyperosmolarity. In specialised clinics we recommend the routine measurement of the ocular protection index in patients with DED as a measure of this threat. A high level of osmolarity in a meniscus sample implies a much higher level at the ocular surface.

The Subcommittee found increasing evidence to support the role of tissue hyperosmolarity at the ocular surface as a central element in DED, generated by exposure to hyperosmolar tears, particularly following tear film breakup. While stressing this, the Subcommittee recognizes that the predicted high levels of osmolarity have not yet been measured directly at the corneal surface

and recommend that priority be given to the development of methods to measure of molarity at the tissue level.

A neutrophil defence mechanism (NETosis) known to be a source of mucosal damage in other diseases such as cystic fibrosis, may be a source of ocular surface damage in DED, amplified by increased epithelial shedding, tear hyperosmolarity and a fall in tear nuclease activity. DNA released into the tears (eDNA) from desquamating epithelial cells and invading neutrophils can, independently, or combined with other components of neutrophil origin, cause damage the ocular surface. Dying neutrophils can release their cellular contents into the extracellular space to form sticky, antimicrobial, Neutrophil Extracellular Traps or NETs. They form extracellular webs containing decondensed chromatin, histones, neutrophil elastase and antimicrobial peptides, each of which individually may be toxic for epithelial cells. Given that the tears are invaded physiologically by abundant neutrophils during overnight eye closure it would seem important to explore the relationship between the NET formation and closed eye tear phenomena. The Subcommittee recommends the investigation of closed eye tears and of conjunctival impression cytology specimens in DED patients, immediately after periods of prolonged eye closure.

In the TFOS DEWS report [1], the concept of a vicious circle of inflammatory events at the ocular surface was put forward, as a basis for the self-perpetuation of DED. Evidence indicated that tear hyperosmolarity could initiate a damaging cascade of inflammation at the ocular surface, which could decrease wettability, induce tear film instability and breakup and thereby amplify tear hyperosmolarity. Importantly, a given etiology of DED may enter the vicious circle at any point to participate in this process (Fig. 5) Abundant supportive evidence for the concept has accumulated since this time at an experimental and clinical level, with detailed knowledge of immune cell activation and invasion and of the inflammatory mediators and proteases involved. Further experimental evidence in a mouse model suggests that ocular surface inflammation can outlast exposure to DES and may be able to perpetuate the clinical features of the disease. The potential dissociation between cause and effect may explain in part the discrepancy between some objective signs and patient symptoms reported in the literature.

For any cause of DED, tear hyperosmolarity is initiated by either or both of two mechanisms. In ADDE there is a deficient lacrimal secretion but a normal rate of evaporation from a tear film of reduced volume. In EDE hyperosmolarity results from an excessive evaporation of tears in the presence of normal lacrimal function. Since all forms of DED are due to water loss from the tear film, the precipitation of hyperosmolarity at the ocular surface is strongly influenced by environment, including ambient humidity, airflow and temperature and also blink interval, lid aperture and globe prominence. Unfavourable conditions may either trigger the onset of DED or exacerbate its severity. The effect of environment is brought out by the newly described condition of SBUDE observed in Japanese office workers. The ergonomic and environmental factors that precipitate this form of DED require further study.

It is evident that many *hybrid forms of DED* exist in which lacrimal deficiency and increased evaporative loss collaborate to cause enhanced ocular surface hyperosmolarity. These are summarised in Table 13. Such hybrid states should be recognised in the inclusion criteria of clinical trials and in subgroup analyses of outcomes. Once a dry eye is of sufficient severity to cause tear breakup within the blink interval an additional evaporative component will be added to any form of DED, so that any ADDE will acquire an evaporative component and the evaporative basis of an existing EDE will be amplified. Studies which test this prediction by comparing the ocular protection index with evaporation rate and

tear osmolarity would be of value.

This hybrid state should not obscure the initiating mechanism of the DED. It is predicted that tear levels of the lacrimal proteins, lysozyme, lactoferrin and peroxidase will remain normal where the initiating cause is EDE but will be reduced where it is ADDE, due to lacrimal acinar destruction. This hypothesis should be tested in the field. A revised language is required to accommodate these and other forms of hybrid DED.

A variety of *animal models of DED* exist which address the several pathophysiological mechanisms responsible for DED including lacrimal gland insufficiency, MGD, impairment of the innervation, humoral mechanisms and environmental stress. Genetic manipulation has been used to explore the factors influencing susceptibility. Their study provides hypothesis-generating insights into the causes of human DED and, since domestic animals may suffer from spontaneous, autoimmune DED, the findings are of veterinary as well as human clinical interest. They also provide an opportunity for toxicological and pharmacokinetic study of potentially sight-saving new drugs.

Murine models of DES and SCP permit the evolution of DED to be timed from its initiation. A constellation of cytokines and chemokines has been identified in these models to cause damage to the ocular surface, with differences in outcome according to the experimental model.

Models of autoimmune DED, simulating Sjögren syndrome are dependent on genetic susceptibility. In various models the influence of autoreactive T cells, of disrupting TGF- $\beta$  signaling or the Fas-Fas ligand system, of inducing glandular apoptosis, of manipulating sex hormones and of generating autoantibodies encountered in human disease, has been explored. In the majority of these models the diseases evolve spontaneously over time to a varying level of severity. In contrast to the DES and SCP models the specific trigger for the onset of disease is not known. Therefore, those models in which DES is administered to genetically modified animals are of particular interest in bridging the gap in knowledge between initiation and susceptibility in different model systems. The role of genetic susceptibility in human, age-related NSDE has not yet been adequately explored.

Both aged and chronic models of DED have been developed, with sex differences in severity, including corneal damage (C57BL/6) and goblet cell density (MRL.lpr.B6), which are of great interest in relation to human disease. T helper cell (Th1 and Th2) cytokines have been shown to have opposing effects on conjunctival goblet cell development and maintenance. The Th2 cytokine IL-13 induces goblet cell differentiation and mucus production and the Th1 cytokine IFN- $\gamma$  causes goblet cell loss in a DES model of DED. In some models a sex bias for sialoadenitis versus dacryoadenitis has been shown.

This Subcommittee has taken some trouble to compare and contrast the clinical and pathological features of Sjögren syndrome as it affects the lacrimal and salivary glands. More work can be done at a number of levels. Fresh lacrimal tissue is scarce, but an opportunity should be taken to establish post-mortem banks of lacrimal and salivary gland tissues for research purposes, obtained from patients with well-characterized Sjögren syndrome and NSDE.

The potential role of *viral triggers* of Sjögren syndrome in genetically disposed individuals should be explored further. When exposure and infection are as common as is the case for the Epstein Barr virus, this task may at first seem disheartening, but stored blood data is potentially available for large numbers of exposed and unexposed individuals and has been used epidemiologically to study the role of EBV as a risk factor for multiple sclerosis and SLE [1099-1101]. This approach should be harnessed for the study of Sjögren syndrome.

## Acknowledgments

The Subcommittee wish to acknowledge the help of Jutta Horwath-Winter for reviewing key aspects of this report, to Barbara Caffery, Donald Korb and Tannin Schmidt for contributions to the sections on Sjögren Syndrome, blinking, and frictional forces, and to Maria Markoulli and Driss Zoukhri for their dedicated work in preparation of the manuscript.

## References

- [1] Report of the international dry eye workshop (DEWS). *Ocul Surf* 2007;5: 65–204.
- [2] Dean C, Ito M, Makarenkova HP, Faber SC, Lang RA. Bmp7 regulates branching morphogenesis of the lacrimal gland by promoting mesenchymal proliferation and condensation. *Development* 2004;131:4155–65.
- [3] Makarenkova HP, Ito M, Govindarajan V, Faber SC, Sun L, McMahon G, et al. FGF10 is an inducer and Pax6 a competence factor for lacrimal gland development. *Development* 2000;127:2563–72.
- [4] Grishina I, Lattes B. A novel Cdk2 interactor is phosphorylated by Cdc7 and associates with components of the replication complexes. *Cell Cycle* 2005;4: 1120–6.
- [5] Fernandez-Valencia R, Gomez Pellico L. Functional anatomy of the human saccus lacrimalis. *Acta Anat* 1990;139:54–9.
- [6] Bron AJ. Lacrimal streams: the demonstration of human lacrimal fluid secretion and the lacrimal ductules. *Br J Ophthalmol* 1986;70:241–5.
- [7] Seifert P, Spitznas M, Koch F, Cusumano A. The architecture of human accessory lacrimal glands. *Ger J Ophthalmol* 1993;2:444–54.
- [8] Bergmanson JP, Doughty MJ, Blocker Y. The acinar and ductal organisation of the tarsal accessory lacrimal gland of Wolfring in rabbit eyelid. *Exp Eye Res* 1999;68:411–21.
- [9] Allansmith MR, Kajiyama G, Abelson MB, Simon MA. Plasma cell content of main and accessory lacrimal glands and conjunctiva. *Am J Ophthalmol* 1976;82:819–26.
- [10] Seifert P, Spitznas M. Vasoactive intestinal polypeptide (VIP) innervation of the human eyelid glands. *Exp Eye Res* 1999;68:685–92.
- [11] Wiczorek R, Jakobiec FA, Sacks EH, Knowlens DM. The immunoreactivity of the normal human lacrimal gland. Relevance for understanding pathologic conditions. *Ophthalmology* 1988;95:100–9.
- [12] Dartt DA. Regulation of tear secretion. *Adv Exp Med Biol* 1994;350:1–9.
- [13] Dartt DA. Neural regulation of lacrimal gland secretory processes: relevance in dry eye diseases. *Prog Retin Eye Res* 2009;28:155–77.
- [14] Knop E, Knop N. The role of eye-associated lymphoid tissue in corneal immune protection. *J Anat* 2005;206:271–85.
- [15] Dartt DA. Signal transduction and control of lacrimal gland protein secretion: a review. *Curr Eye Res* 1989;8:619–36.
- [16] Jager K, Wu G, Sel S, Garreis F, Brauer L, Paulsen FP. MUC16 in the lacrimal apparatus. *Histochem Cell Biol* 2007;127:433–8.
- [17] Jumblatt MM, McKenzie RW, Steele PS, Emberts CG, Jumblatt JE. MUC7 expression in the human lacrimal gland and conjunctiva. *Cornea* 2003;22: 41–5.
- [18] Paulsen F, Langer G, Hoffmann W, Berry M. Human lacrimal gland mucins. *Cell Tissue Res* 2004;316:167–77.
- [19] Mircheff AK. Lacrimal gland fluid and electrolyte secretion: a review. *Curr Eye Res* 1989;8:607–17.
- [20] Mircheff AK. Water and electrolyte secretion and fluid modification. In: Albert D, Jakobiec F, editors. *Principles and Practice of Ophthalmology: Basic Sciences*. Philadelphia: WB Saunders Company; 1994. p. 466–72.
- [21] Makarenkova HP, Dartt DA. Myoepithelial cells: their origin and function in lacrimal gland morphogenesis, homeostasis, and repair. *Curr Mol Biol Rep* 2015;1:115–23.
- [22] Leeson TS, Leeson CR. Myoepithelial cells in the exorbital lacrimal and parotid glands of the rat in frozen-etched replicas. *Am J Anat* 1971;132: 133–45.
- [23] Botelho SY. Tears and the lacrimal gland. *Sci Am* 1964;211:78–86.
- [24] Sibony PA, Walcott B, McKeon C, Jakobiec FA. Vasoactive intestinal polypeptide and the innervation of the human lacrimal gland. *Arch Ophthalmol* 1988;106:1085–8.
- [25] Hodges RR, Dartt DA. Regulatory pathways in lacrimal gland epithelium. *Int Rev Cytol* 2003;231:129–96.
- [26] Gupta A, Heigle T, Pflugfelder SC. Nasolacrimal stimulation of aqueous tear production. *Cornea* 1997;16:645–8.
- [27] Berthong M. Pathologic changes secondary to radiation. *World J Surg* 1986;10:155–70.
- [28] Ackermann P, Hetz S, Dieckow J, Schicht M, Richter A, Kruse C, et al. Isolation and investigation of presumptive murine lacrimal gland stem cells. *Invest Ophthalmol Vis Sci* 2015;56:4350–63.
- [29] Shatos MA, Haugaard-Kedstrom L, Hodges RR, Dartt DA. Isolation and characterization of progenitor cells in uninjured, adult rat lacrimal gland. *Invest Ophthalmol Vis Sci* 2012;53:2749–59.
- [30] Zoukhri D. Mechanisms involved in injury and repair of the murine lacrimal gland: role of programmed cell death and mesenchymal stem cells. *Ocul Surf* 2010;8:60–9.
- [31] Zoukhri D, Fix A, Alroy J, Kublin CL. Mechanisms of murine lacrimal gland repair after experimentally induced inflammation. *Invest Ophthalmol Vis Sci* 2008;49:4399–406.
- [32] Zoukhri D. Effect of inflammation on lacrimal gland function. *Exp Eye Res* 2006;82:885–98.
- [33] Thiery JP, Aclouque H, Huang RY, Nieto MA. Epithelial-mesenchymal transitions in development and disease. *Cell* 2009;139:871–90.
- [34] Mani SA, Guo W, Liao MJ, Eaton EN, Ayyanan A, Zhou AY, et al. The epithelial-mesenchymal transition generates cells with properties of stem cells. *Cell* 2008;133:704–15.
- [35] You S, Avidan O, Tariq A, Ahluwalia I, Stark PC, Kublin CL, et al. Role of epithelial-mesenchymal transition in repair of the lacrimal gland after experimentally induced injury. *Invest Ophthalmol Vis Sci* 2012;53:126–35.
- [36] Knop E, Knop N, Millar T, Obata H, Sullivan DA. The international workshop on meibomian gland dysfunction: report of the subcommittee on anatomy, physiology, and pathophysiology of the meibomian gland. *Invest Ophthalmol Vis Sci* 2011;52:1938–78.
- [37] Foulks GN, Bron AJ. Meibomian gland dysfunction: a clinical scheme for description, diagnosis, classification, and grading. *Ocul Surf* 2003;1:107–26.
- [38] Andersen H, Ehlers N, Matthiessen ME. Histochemistry and development of the human eyelids. *Acta Ophthalmol (Copenh)* 1965;43:642–68.
- [39] Jester JV, Nicolaides N, Kiss-Palvolgyi I, Smith RE. Meibomian gland dysfunction. II. The role of keratinization in a rabbit model of MGD. *Invest Ophthalmol Vis Sci* 1989;30:936–45.
- [40] Knop E, Knop N, Zhivov A, Kraak R, Korb DR, Blackie C, et al. The lid wiper and muco-cutaneous junction anatomy of the human eyelid margins: an in vivo confocal and histological study. *J Anat* 2011;218:449–61.
- [41] Cox SM, Nichols JJ. The neurobiology of the meibomian glands. *Ocul Surf* 2014;12:167–77.
- [42] Kam WR, Sullivan DA. Neurotransmitter influence on human meibomian gland epithelial cells. *Invest Ophthalmol Vis Sci* 2011;52:8543–8.
- [43] Sullivan DA, Liu Y, Kam WR, Ding J, Green KM, Shaffer SA, et al. Serum-induced differentiation of human meibomian gland epithelial cells. *Invest Ophthalmol Vis Sci* 2014;55:3866–77.
- [44] Schirra F, Suzuki T, Richards SM, Jensen RV, Liu M, Lombardi MJ, et al. Androgen control of gene expression in the mouse meibomian gland. *Invest Ophthalmol Vis Sci* 2005;46:3666–75.
- [45] Ding J, Kam WR, Dieckow J, Sullivan DA. The influence of 13-cis retinoic acid on human meibomian gland epithelial cells. *Invest Ophthalmol Vis Sci* 2013;54:4341–50.
- [46] Ding J, Liu Y, Sullivan DA. Effects of insulin and high glucose on human meibomian gland epithelial cells. *Invest Ophthalmol Vis Sci* 2015;56: 7814–20.
- [47] Ding J, Sullivan DA. The effects of insulin-like growth factor 1 and growth hormone on human meibomian gland epithelial cells. *JAMA Ophthalmol* 2014;132:593–9.
- [48] Gidfar S, Afsharkhamseh N, Sanjari S, Djalilian AR. Notch signaling in meibomian gland epithelial cell differentiation. *Invest Ophthalmol Vis Sci* 2016;57:859–65.
- [49] Khandelwal P, Liu S, Sullivan DA. Androgen regulation of gene expression in human meibomian gland and conjunctival epithelial cells. *Mol Vis* 2012;18: 1055–67.
- [50] Liu S, Hatton MP, Khandelwal P, Sullivan DA. Culture, immortalization, and characterization of human meibomian gland epithelial cells. *Invest Ophthalmol Vis Sci* 2010;51:3993–4005.
- [51] Liu S, Kam WR, Ding J, Hatton MP, Sullivan DA. Effect of growth factors on the proliferation and gene expression of human meibomian gland epithelial cells. *Invest Ophthalmol Vis Sci* 2013;54:2541–50.
- [52] Liu Y, Ding J. The combined effect of azithromycin and insulin-like growth factor-1 on cultured human meibomian gland epithelial cells. *Invest Ophthalmol Vis Sci* 2014;55:5596–601.
- [53] Liu Y, Kam WR, Ding J, Sullivan DA. Can tetracycline antibiotics duplicate the ability of azithromycin to stimulate human meibomian gland epithelial cell differentiation? *Cornea* 2015;34:342–6.
- [54] Liu Y, Kam WR, Ding J, Sullivan DA. Effect of azithromycin on lipid accumulation in immortalized human meibomian gland epithelial cells. *JAMA Ophthalmol* 2014;132:226–8.
- [55] Liu Y, Kam WR, Ding J, Sullivan DA. One man's poison is another man's meat: using azithromycin-induced phospholipidosis to promote ocular surface health. *Toxicology* 2014;320:1–5.
- [56] Liu Y, Kam WR, Sullivan DA. Influence of omega 3 and 6 fatty acids on human meibomian gland epithelial cells. *Cornea* 2016;35:1122–6.
- [57] Liu Y, Knop E, Knop N, Sullivan DA, List EO, Kopchick JJ, et al. Growth hormone influence on the morphology and size of the mouse meibomian gland. *J Ophthalmol* 2016;2016:5728071.
- [58] Liu Y, Kam WR, Fernandes P, Sullivan DA. The effect of solithromycin, a cationic amphiphilic drug, on the proliferation and differentiation of human meibomian gland epithelial cells. *Invest Ophthalmol Vis Sci* 2017. ARVO abstract #4379.
- [59] Kam W, Sullivan D. Suppressive effects of 17 $\beta$ -estradiol on immortalized human meibomian gland epithelial cells. *Invest Ophthalmol Vis Sci* 2013. ARVO e-abstract #4316.
- [60] Sahin A, Kam WR, Darabad RR, Topilow K, S DA. Regulation of leukotriene B4

- secretion by human corneal, conjunctival, and meibomian gland epithelial cells. *Arch Ophthalmol* 2012;130:1013–8.
- [61] Zhang Y, Kam WR, Liu Y, Chen X, Sullivan DA. Influence of pilocarpine and timolol on human meibomian gland epithelial cells. *Cornea* 2017;36:719–24.
- [62] Kam W, Sullivan DA, Sullivan BD, Venkiteshwar. Does hyperosmolarity induce an irreversible process leading to human corneal epithelial cell death? *Invest Ophthalmol Vis Sci* 2016. ARVO Abstract #6161.
- [63] Zhang SD, He JN, Niu TT, et al. Bacteriological profile of ocular surface flora in meibomian gland dysfunction. *Ocul Surf* 2017;15:242–7.
- [64] Butovich IA. Lipidomic analysis of human meibum using HPLC-MSn. *Methods Mol Biol* 2009;579:221–46.
- [65] Brown SH, Kunnen CM, Papas EB, Lazon de la Jara P, Willcox MD, Blanksby SJ, et al. Intersubject and Interday variability in human tear and meibum lipidomes: a pilot study. *Ocul Surf* 2016;14:43–8.
- [66] Brown SH, Kunnen CM, Duchoslav E, Dolla NK, Kelso MJ, Papas EB, et al. A comparison of patient matched meibum and tear lipidomes. *Invest Ophthalmol Vis Sci* 2013;54:7417–24.
- [67] Berg JM, Tymoczko JL, Stryer L. *Biochemistry*. fifth ed. New York: W. H. Freeman and Co; 2002.
- [68] Schirra F, Suzuki T, Dickinson DP, Townsend DJ, Gipson IK, Sullivan DA. Identification of steroidogenic enzyme mRNAs in the human lacrimal gland, meibomian gland, cornea, and conjunctiva. *Cornea* 2006;25:438–42.
- [69] Schirra F, Richards SM, Liu M, Suzuki T, Yamagami H, Sullivan DA. Androgen regulation of lipogenic pathways in the mouse meibomian gland. *Exp Eye Res* 2006;83:291–6.
- [70] Rawson RB. The site-2 protease. *Biochim Biophys Acta* 2013;1828:2801–7.
- [71] Horton JD, Shah NA, Warrington JA, Anderson NN, Park SW, Brown MS, et al. Combined analysis of oligonucleotide microarray data from transgenic and knockout mice identifies direct SREBP target genes. *Proc Natl Acad Sci U S A* 2003;100:12027–32.
- [72] Swinnen JV, Heemers H, van de Sande T, de Schrijver E, Brusselmans K, Heyns W, et al. Androgens, lipogenesis and prostate cancer. *J Steroid Biochem Mol Biol* 2004;92:273–9.
- [73] Megarbane H, Megarbane A. Ichthyosis follicularis, alopecia, and photophobia (IFAP) syndrome. *Orphanet J Rare Dis* 2011;6:29.
- [74] Bron AJ, Evans VE, Smith JA. Grading of corneal and conjunctival staining in the context of other dry eye tests. *Cornea* 2003;22:640–50.
- [75] Knop N, Knop E. Ultrastructural anatomy of CALT follicles in the rabbit reveals characteristics of M-cells, germinal centres and high endothelial venules. *J Anat* 2005;207:409–26.
- [76] Wolff [Not Available] *Homeopath Fr* 1946;22:189.
- [77] Bron AJ. The Doyné lecture. Reflections on the tears. *Eye (Lond)* 1997;11(Pt 5):583–602.
- [78] Mantelli F, Massaro-Giordano M, Macchi I, Lambiase A, Bonini S. The cellular mechanisms of dry eye: from pathogenesis to treatment. *J Cell Physiol* 2013;228:2253–6.
- [79] Bron AJ. The definition and classification of dry eye disease. In: Chan C, editor. *Dry Eye: A Practical Approach*. Springer; 2015.
- [80] Pellegrini G, Golisano O, Paterna P, Lambiase A, Bonini S, Rama P, et al. Location and clonal analysis of stem cells and their differentiated progeny in the human ocular surface. *J Cell Biol* 1999;145:769–82.
- [81] Dartt DA. Regulation of mucin and fluid secretion by conjunctival epithelial cells. *Prog Retin Eye Res* 2002;21:555–76.
- [82] Schmidt TA, Sullivan DA, Knop E, Richards SM, Knop N, Liu S, et al. Transcription, translation, and function of lubricin, a boundary lubricant, at the ocular surface. *JAMA Ophthalmol* 2013;131:766–76.
- [83] Argueso P, Gipson IK. Epithelial mucins of the ocular surface: structure, biosynthesis and function. *Exp Eye Res* 2001;73:281–9.
- [84] Levin MH, Verkman AS. Aquaporin-dependent water permeation at the mouse ocular surface: in vivo microfluorimetric measurements in cornea and conjunctiva. *Invest Ophthalmol Vis Sci* 2004;45:4423–32.
- [85] Knop E, Knop N, Claus P. Local production of secretory IgA in the eye-associated lymphoid tissue (EALT) of the normal human ocular surface. *Invest Ophthalmol Vis Sci* 2008;49:2322–9.
- [86] Barrandon Y. The biology of epidermal stem cells. *Ann Dermatol Venerol* 1998;125(Suppl 2):S5–6.
- [87] Lajtha LG. Stem cell concepts. *Nouv Rev Fr Hematol* 1979;21:59–65.
- [88] Dua HS, Miri A, Alomar T, Yeung AM, Said DG. The role of limbal stem cells in corneal epithelial maintenance: testing the dogma. *Ophthalmology* 2009;116:856–63.
- [89] Dziasko MA, Daniels JT. Anatomical features and cell-cell interactions in the human limbal epithelial stem cell niche. *Ocul Surf* 2016;14:322–30.
- [90] Ramos T, Scott D, Ahmad S. An update on ocular surface epithelial stem cells: cornea and conjunctiva. *Stem Cells Int* 2015;2015:601731.
- [91] Tseng SC, He H, Zhang S, Chen SY. Niche regulation of limbal epithelial stem cells: relationship between inflammation and regeneration. *Ocul Surf* 2016;14:100–12.
- [92] Wei ZG, Sun TT, Lavker RM. Rabbit conjunctival and corneal epithelial cells belong to two separate lineages. *Invest Ophthalmol Vis Sci* 1996;37:523–33.
- [93] Wei ZG, Wu RL, Lavker RM, Sun TT. In vitro growth and differentiation of rabbit bulbar, fornix, and palpebral conjunctival epithelia. Implications on conjunctival epithelial transdifferentiation and stem cells. *Invest Ophthalmol Vis Sci* 1993;34:1814–28.
- [94] Pe'er J, Zajicek G, Greifner H, Kogan M. Streaming conjunctiva. *Anat Rec* 1996;245:36–40.
- [95] Wirtschafter JD, Ketcham JM, Weinstock RJ, Tabesh T, McLoon LK. Mucocutaneous junction as the major source of replacement palpebral conjunctival epithelial cells. *Invest Ophthalmol Vis Sci* 1999;40:3138–46.
- [96] Stewart RM, Sheridan CM, Hiscott PS, Czanner G, Kaye SB. Human conjunctival stem cells are predominantly located in the medial canthal and inferior Forniceal areas. *Invest Ophthalmol Vis Sci* 2015;56:2021–30.
- [97] Kessing SV. Mucous gland system of the conjunctiva. A quantitative normal anatomical study. *Acta Ophthalmol (Copenh)* 1968;(Suppl 95):91+.
- [98] Perez-Vilar J, Hill RL. The structure and assembly of secreted mucins. *J Biol Chem* 1999;274:31751–4.
- [99] Gipson IK. Distribution of mucins at the ocular surface. *Exp Eye Res* 2004;78:379–88.
- [100] Mantelli F, Argueso P. Functions of ocular surface mucins in health and disease. *Curr Opin Allergy Clin Immunol* 2008;8:477–83.
- [101] Knop N, Korb DR, Blackie CA, Knop E. The lid wiper contains goblet cells and goblet cell crypts for ocular surface lubrication during the blink. *Cornea* 2012;31:668–79.
- [102] Knop N, Knop E. The crypt system of the human conjunctiva. *Adv Exp Med Biol* 2002;506:867–72.
- [103] Gordon YJ, Romanowski EG, McDermott AM. A review of antimicrobial peptides and their therapeutic potential as anti-infective drugs. *Curr Eye Res* 2005;30:505–15.
- [104] Knop E, Korb DR, Blackie CA, Knop N. The lid margin is an underestimated structure for preservation of ocular surface health and development of dry eye disease. *Dev Ophthalmol* 2010;45:108–22.
- [105] De Paiva CS, Raince JK, McClellan AJ, Shanmugam KP, Pangelinan SB, Volpe EA, et al. Homeostatic control of conjunctival mucosal goblet cells by NKT-derived IL-13. *Mucosal Immunol* 2011;4:397–408.
- [106] Diebold Y, Rios JD, Hodges RR, Rawe I, Dartt DA. Presence of nerves and their receptors in mouse and human conjunctival goblet cells. *Invest Ophthalmol Vis Sci* 2001;42:2270–82.
- [107] Rios JD, Forde K, Diebold Y, Lightman J, Zieske JD, Dartt DA. Development of conjunctival goblet cells and their neuroreceptor subtype expression. *Invest Ophthalmol Vis Sci* 2000;41:2127–37.
- [108] Rios JD, Zoukhri D, Rawe IM, Hodges RR, Zieske JD, Dartt DA. Immunolocalization of muscarinic and VIP receptor subtypes and their role in stimulating goblet cell secretion. *Invest Ophthalmol Vis Sci* 1999;40:1102–11.
- [109] Dartt DA, Kessler TL, Chung EH, Zieske JD. Vasoactive intestinal peptide-stimulated glycoconjugate secretion from conjunctival goblet cells. *Exp Eye Res* 1996;63:27–34.
- [110] Hodges RR, Bair JA, Carozza RB, Li D, Shatos MA, Dartt DA. Signaling pathways used by EGF to stimulate conjunctival goblet cell secretion. *Exp Eye Res* 2012;103:99–113.
- [111] Fujihara T, Murakami T, Fujita H, Nakamura M, Nakata K. Improvement of corneal barrier function by the P2Y<sub>2</sub> agonist INS365 in a rat dry eye model. *Invest Ophthalmol Vis Sci* 2001;42:96–100.
- [112] Jumblatt JE, Jumblatt MM. Regulation of ocular mucin secretion by P2Y<sub>2</sub> nucleotide receptors in rabbit and human conjunctiva. *Exp Eye Res* 1998;67:341–6.
- [113] Rios JD, Ghinelli E, Gu J, Hodges RR, Dartt DA. Role of neurotrophins and neurotrophin receptors in rat conjunctival goblet cell secretion and proliferation. *Invest Ophthalmol Vis Sci* 2007;48:1543–51.
- [114] Hingorani M, Metz D, Lightman SL. Characterisation of the normal conjunctival leukocyte population. *Exp Eye Res* 1997;64:905–12.
- [115] Allansmith MR, Greiner JV, Baird RS. Number of inflammatory cells in the normal conjunctiva. *Am J Ophthalmol* 1978;86:250–9.
- [116] Allansmith M, de Ramus A, Maurice D. The dynamics of IgG in the cornea. *Invest Ophthalmol Vis Sci* 1979;18:947–55.
- [117] Knop N, Knop E. Conjunctiva-associated lymphoid tissue in the human eye. *Invest Ophthalmol Vis Sci* 2000;41:1270–9.
- [118] Knop E, Knop N. Conjunctiva-associated lymphoid tissue (CALT) in the human eye – components and topographical distribution. *Ophthalmic Res* 1999;31(Suppl.):156.
- [119] Knop E, Knop N. A functional unit for ocular surface immune defense formed by the lacrimal gland, conjunctiva and lacrimal drainage system. *Adv Exp Med Biol* 2002;506:835–44.
- [120] Dua HS, Gomes JA, Jindal VK, Appa SN, Schwarting R, Eagle Jr RC, et al. Mucosa specific lymphocytes in the human conjunctiva, corneoscleral limbus and lacrimal gland. *Curr Eye Res* 1994;13:87–93.
- [121] Wotherspoon AC, Hardman-Lea S, Isaacson PG. Mucosa-associated lymphoid tissue (MALT) in the human conjunctiva. *J Pathol* 1994;174:33–7.
- [122] Nichols B, Dawson CR, Togni B. Surface features of the conjunctiva and cornea. *Invest Ophthalmol Vis Sci* 1983;24:570–6.
- [123] Cope C, Dilly PN, Kaura R, Tiffany JM. Wettability of the corneal surface: a reappraisal. *Curr Eye Res* 1986;5:777–85.
- [124] Gipson IK, Argueso P. Role of mucins in the function of the corneal and conjunctival epithelia. *Int Rev Cytol* 2003;231:1–49.
- [125] Liotet S, Van Bijsterveld OP, Kogbe O, Laroche L. A new hypothesis on tear film stability. *Ophthalmologica* 1987;195:119–24.
- [126] Cai K, Wei R. Interleukin-7 expression in tears and orbital tissues of patients with Graves' ophthalmopathy. *Endocrine* 2013;44:140–4.
- [127] Sumiyoshi M, Ricciuto J, Tisdale A, Gipson IK, Mantelli F, Argueso P. Anti-adhesive character of mucin O-glycans at the apical surface of corneal epithelial cells. *Invest Ophthalmol Vis Sci* 2008;49:197–203.

- [128] Blalock TD, Spurr-Michaud SJ, Tisdale AS, Heimer SR, Gilmore MS, Ramesh V, et al. Functions of MUC16 in corneal epithelial cells. *Invest Ophthalmol Vis Sci* 2007;48:4509–18.
- [129] Ricciuto J, Heimer SR, Gilmore MS, Argueso P. Cell surface O-glycans limit *Staphylococcus aureus* adherence to corneal epithelial cells. *Infect Immun* 2008;76:5215–20.
- [130] Govindarajan B, Gipson IK. Membrane-tethered mucins have multiple functions on the ocular surface. *Exp Eye Res* 2010;90:655–63.
- [131] Inatomi T, Spurr-Michaud S, Tisdale AS, Gipson IK. Human corneal and conjunctival epithelia express MUC1 mucin. *Invest Ophthalmol Vis Sci* 1995;36:1818–27.
- [132] Inatomi T, Spurr-Michaud S, Tisdale AS, Zhan Q, Feldman ST, Gipson IK. Expression of secretory mucin genes by human conjunctival epithelia. *Invest Ophthalmol Vis Sci* 1996;37:1684–92.
- [133] Argueso P, Spurr-Michaud S, Russo CL, Tisdale A, Gipson IK. MUC16 mucin is expressed by the human ocular surface epithelia and carries the H185 carbohydrate epitope. *Invest Ophthalmol Vis Sci* 2003;44:2487–95.
- [134] Argueso P, Guzman-Aranguez A, Mantelli F, Cao Z, Ricciuto J, Panjwani N. Association of cell surface mucins with galectin-3 contributes to the ocular surface epithelial barrier. *J Biol Chem* 2009;284:23037–45.
- [135] Moniaux N, Escande F, Porchet N, Aubert JP, Batra SK. Structural organization and classification of the human mucin genes. *Front Biosci* 2001;6:D1192–206.
- [136] Yin BW, Lloyd KO. Molecular cloning of the CA125 ovarian cancer antigen: identification as a new mucin, MUC16. *J Biol Chem* 2001;276:27371–5.
- [137] Komatsu M, Yee L, Carraway KL. Overexpression of sialomucin complex, a rat homologue of MUC4, inhibits tumor killing by lymphokine-activated killer cells. *Cancer Res* 1999;59:2229–36.
- [138] Carraway KL, Hull SR. Cell surface mucin-type glycoproteins and mucin-like domains. *Glycobiology* 1991;1:131–8.
- [139] Hattstrup CL, Gendler SJ. Structure and function of the cell surface (tethered) mucins. *Annu Rev Physiol* 2008;70:431–57.
- [140] Hilken J, Vos HL, Wesseling J, Boer M, Storm J, van der Valk S, et al. Is episialin/MUC1 involved in breast cancer progression? *Cancer Lett* 1995;90:27–33.
- [141] Wesseling J, van der Valk SW, Vos HL, Sonnenberg A, Hilken J. Episialin (MUC1) overexpression inhibits integrin-mediated cell adhesion to extracellular matrix components. *J Cell Biol* 1995;129:255–65.
- [142] Cascio S, Zhang L, Finn OJ. MUC1 protein expression in tumor cells regulates transcription of proinflammatory cytokines by forming a complex with nuclear factor-kappaB p65 and binding to cytokine promoters: importance of extracellular domain. *J Biol Chem* 2011;286:42248–56.
- [143] Roy LD, Sahraei M, Subramani DB, Besmer D, Nath S, Tinder TL, et al. MUC1 enhances invasiveness of pancreatic cancer cells by inducing epithelial to mesenchymal transition. *Oncogene* 2011;30:1449–59.
- [144] Pflugfelder SC, Liu Z, Monroy D, Li DQ, Carvajal ME, Price-Schiavi SA, et al. Detection of sialomucin complex (MUC4) in human ocular surface epithelium and tear fluid. *Invest Ophthalmol Vis Sci* 2000;41:1316–26.
- [145] O'Brien TJ, Beard JB, Underwood LJ, Dennis RA, Santin AD, York L. The CA 125 gene: an extracellular superstructure dominated by repeat sequences. *Tumour Biol* 2001;22:348–66.
- [146] O'Brien TJ, Beard JB, Underwood LJ, Shigemasa K. The CA 125 gene: a newly discovered extension of the glycosylated N-terminal domain doubles the size of this extracellular superstructure. *Tumour Biol* 2002;23:154–69.
- [147] Gipson IK, Spurr-Michaud S, Tisdale A, Menon BB. Comparison of the transmembrane mucins MUC1 and MUC16 in epithelial barrier function. *PLoS One* 2014;9:e100393.
- [148] Argueso P, Tisdale A, Spurr-Michaud S, Sumiyoshi M, Gipson IK. Mucin characteristics of human corneal-limbal epithelial cells that exclude the rose bengal anionic dye. *Invest Ophthalmol Vis Sci* 2006;47:113–9.
- [149] Arafat SN, Suelves AM, Spurr-Michaud S, Chodosh J, Foster CS, Dohlman CH, et al. Neutrophil collagenase, gelatinase, and myeloperoxidase in tears of patients with stevens-johnson syndrome and ocular cicatricial pemphigoid. *Ophthalmology* 2014;121:79–87.
- [150] Mantelli F, Schaffer L, Dana R, Head SR, Argueso P. Glycogene expression in conjunctiva of patients with dry eye: downregulation of Notch signaling. *Invest Ophthalmol Vis Sci* 2009;50:2666–72.
- [151] Ahmad N, Gabius HJ, Andre S, Kaltner H, Sabesan S, Roy R, et al. Galectin-3 precipitates as a pentamer with synthetic multivalent carbohydrates and forms heterogeneous cross-linked complexes. *J Biol Chem* 2004;279:10841–7.
- [152] Barondes SH, Castronovo V, Cooper DN, Cummings RD, Drickamer K, Feizi T, et al. Galectins: a family of animal beta-galactoside-binding lectins. *Cell* 1994;76:597–8.
- [153] Rabinovich GA, Toscano MA, Jackson SS, Vasta GR. Functions of cell surface galectin-glycoprotein lattices. *Curr Opin Struct Biol* 2007;17:513–20.
- [154] Argueso P. Glycobiology of the ocular surface: mucins and lectins. *Jpn J Ophthalmol* 2013;57:150–5.
- [155] Uchino Y, Mauris J, Woodward AM, Dieckow J, Amparo F, Dana R, et al. Alteration of galectin-3 in tears of patients with dry eye disease. *Am J Ophthalmol* 2015;159:1027 e3–35 e3.
- [156] Jumblatt MM, McKenzie RW, Jumblatt JE. MUC5AC mucin is a component of the human precorneal tear film. *Invest Ophthalmol Vis Sci* 1999;40:43–9.
- [157] McKenzie RW, Jumblatt JE, Jumblatt MM. Quantification of MUC2 and MUC5AC transcripts in human conjunctiva. *Invest Ophthalmol Vis Sci* 2000;41:703–8.
- [158] Corrales RM, Galarreta D, Herreras JM, Saez V, Arranz I, Gonzalez MJ, et al. Conjunctival mucin mRNA expression in contact lens wear. *Optom Vis Sci* 2009;86:1051–8.
- [159] Spurr-Michaud S, Argueso P, Gipson I. Assay of mucins in human tear fluid. *Exp Eye Res* 2007;84:939–50.
- [160] Woodward AM, Argueso P. Expression analysis of the transmembrane mucin MUC20 in human corneal and conjunctival epithelia. *Invest Ophthalmol Vis Sci* 2014;55:6132–8.
- [161] Kinoshita S. Ocular surface reconstruction by tissue engineering. *Nihon Ganka Gakkai Zasshi* 2002;106:837–68. discussion 869.
- [162] King-Smith PE, Fink BA, Fogt N, Nichols KK, Hill RM, Wilson GS. The thickness of the human precorneal tear film: evidence from reflection spectra. *Invest Ophthalmol Vis Sci* 2000;41:3348–59.
- [163] Bron AJ, Yokoi N, Gaffney EA, Tiffany JM. A solute gradient in the tear meniscus. I. A hypothesis to explain Marx's line. *Ocul Surf* 2011;9:70–91.
- [164] McDonald JE. Surface phenomena of the tear film. *Am J Ophthalmol* 1969;67:56–64.
- [165] Yokoi N, Uchino M, Uchino Y, Dogru M, Kawashima M, Komuro A, et al. Importance of tear film instability in dry eye disease in office workers using visual display terminals: the Osaka study. *Am J Ophthalmol* 2015;159:748–54.
- [166] Bron AJ, Yokoi N, Yang Z, Georgiev GA. The pre-corneal fluid shell. What is the effect of drop instillation? *Invest Ophthalmol Vis Sci* 2015;2015. ARVO poster, Abstract 2496.
- [167] Doane MG. Dynamics of the human blink. *Ber Zusammenkunft Dtsch Ophthalmol Ges* 1979;13–7.
- [168] Yokoi N, Kinoshita S, Bron AJ, Tiffany JM, Sugita J, Inatomi T. Tear meniscus changes during cotton thread and Schirmer testing. *Invest Ophthalmol Vis Sci* 2000;41:3748–53.
- [169] Yokoi N, Bron AJ, Tiffany JM, Maruyama K, Komuro A, Kinoshita S. Relationship between tear volume and tear meniscus curvature. *Arch Ophthalmol* 2004;122:1265–9.
- [170] Mishima S, Gasset A, Klyce Jr SD, Baum JL. Determination of tear volume and tear flow. *Invest Ophthalmol* 1966;5:264–76.
- [171] Mainstone JC, Bruce AS, Golding TR. Tear meniscus measurement in the diagnosis of dry eye. *Curr Eye Res* 1996;15:653–61.
- [172] Shen M, Li J, Wang J, Ma H, Cai C, Tao A, et al. Upper and lower tear menisci in the diagnosis of dry eye. *Invest Ophthalmol Vis Sci* 2009;50:2722–6.
- [173] Mishima S. Some physiological aspects of the precorneal tear film. *Arch Ophthalmol* 1965;73:233–41.
- [174] Tomlinson A, Doane MG, McFadyen A. Inputs and outputs of the lacrimal system: review of production and evaporative loss. *Ocul Surf* 2009;7:186–98.
- [175] Craig JP, Tomlinson A. Importance of the lipid layer in human tear film stability and evaporation. *Optom Vis Sci* 1997;74:8–13.
- [176] Gaffney EA, Tiffany JM, Yokoi N, Bron AJ. A mass and solute balance model for tear volume and osmolarity in the normal and the dry eye. *Prog Retin Eye Res* 2010;29:59–78.
- [177] Nichols JJ, Mitchell GL, King-Smith PE. Thinning rate of the precorneal and preclear tear films. *Invest Ophthalmol Vis Sci* 2005;46:2353–61.
- [178] Yokoi N, Kato H, Sakai R, Georgiev GA, Kinoshita S. Investigation of the difference in clinical manifestations in different patterns of tear film breakup. *Invest Ophthalmol Vis Sci* 2014;55:1978.
- [179] King-Smith PE, Hinel EA, Nichols JJ. Application of a novel interferometric method to investigate the relation between lipid layer thickness and tear film thinning. *Invest Ophthalmol Vis Sci* 2010;51:2418–23.
- [180] Bron AJ, Tiffany JM. The contribution of meibomian disease to dry eye. *Ocul Surf* 2004;2:149–65.
- [181] Tiffany JM. The lipid secretion of the meibomian glands. *Adv Lipid Res* 1987;22:1–62.
- [182] Georgiev GA, Yokoi N, Ivanova S, Tonchev V, Nencheva Y, Krastev R. Surface relaxations as a tool to distinguish the dynamic interfacial properties of films formed by normal and diseased meibomian lipids. *Soft Matter* 2014;10:5579–88.
- [183] Butovich IA, Lu H, McMahon A, Ketelson H, Senchyna M, Meadows D, et al. Biophysical and morphological evaluation of human normal and dry eye meibum using hot stage polarized light microscopy. *Invest Ophthalmol Vis Sci* 2014;55:87–101.
- [184] Blackie CA, Korb DR, Knop E, Bedi R, Knop N, Holland EJ. Nonobvious obstructive meibomian gland dysfunction. *Cornea* 2010;29:1333–45.
- [185] Chew CK, Hykin PG, Jansweijer C, Dikstein S, Tiffany JM, Bron AJ. The casual level of meibomian lipids in humans. *Curr Eye Res* 1993;12:255–9.
- [186] Chew CK, Jansweijer C, Tiffany JM, Dikstein S, Bron AJ. An instrument for quantifying meibomian lipid on the lid margin: the Meibometer. *Curr Eye Res* 1993;12:247–54.
- [187] Holly FJ, Lemp MA. Tear physiology and dry eyes. *Surv Ophthalmol* 1977;22:69–87.
- [188] McCulley JP, Shine W. A compositional based model for the tear film lipid layer. *Trans Am Ophthalmol Soc* 1997;95:79–88. discussion 88–93.
- [189] Butovich IA. On the lipid composition of human meibum and tears: comparative analysis of nonpolar lipids. *Invest Ophthalmol Vis Sci* 2008;49:3779–89.
- [190] Green-Church KB, Butovich I, Wilcox M, Borchman D, Paulsen F, Barabino S, et al. The international workshop on meibomian gland dysfunction: report of

- the subcommittee on tear film lipids and lipid-protein interactions in health and disease. *Invest Ophthalmol Vis Sci* 2011;52:1979–93.
- [191] Millar TJ. Elucidate the contribution of proteins to tears. A challenge for researchers. *Arch Soc Esp Ophthalmol* 2006;81:187–90.
- [192] Bron AJ, Tomlinson A, Foulks GN, Pepose JS, Baudouin C, Geerling G, et al. Rethinking dry eye disease: a perspective on clinical implications. *Ocul Surf* 2014;12:S1–31.
- [193] King-Smith PE, Fink BA, Hill RM, Koelling KW, Tiffany JM. The thickness of the tear film. *Curr Eye Res* 2004;29:357–68.
- [194] Yokoi N, Yamada H, Mizukusa Y, Bron AJ, Tiffany JM, Kato T, et al. Rheology of tear film lipid layer spread in normal and aqueous tear-deficient dry eyes. *Invest Ophthalmol Vis Sci* 2008;49:5319–24.
- [195] Goto E, Tseng SC. Kinetic analysis of tear interference images in aqueous tear deficiency dry eye before and after punctal occlusion. *Invest Ophthalmol Vis Sci* 2003;44:1897–905.
- [196] Sullivan DA, Tsubota K, Dartt DA, Stern ME, Sullivan RM, Bromberg BB, editors. *Lacrimal Gland, Tear Film and Dry Eye Syndromes 3. Basic Science and Clinical Relevance*. New York: Kluwer Academic/Plenum Press; 2002.
- [197] Yokoi N, Bron AJ, Georgiev GA. The precorneal tear film as a fluid shell: the effect of blinking and saccades on tear film distribution and dynamics. *Ocul Surf* 2014;12:252–66.
- [198] Yañez-Soto B, Mannis MJ, Schwab IR, Li JY, Leonard BC, Abbott NL, et al. Interfacial phenomena and the ocular surface. *Ocul Surf* 2014;12:178–201.
- [199] Rolando M, Valente C, Barabino S. New test to quantify lipid layer behavior in healthy subjects and patients with keratoconjunctivitis sicca. *Cornea* 2008;27:866–70.
- [200] Cher I. A new look at lubrication of the ocular surface: fluid mechanics behind the blinking eyelids. *Ocul Surf* 2008;6:79–86.
- [201] Holly FJ, Lemp MA. Wettability and wetting of corneal epithelium. *Exp Eye Res* 1971;11:239–50.
- [202] Norn MS. Vital staining of the canaliculus lacrimalis and the palpebral border (Marx' line). *Acta Ophthalmol (Copenh)* 1966;44:948–59.
- [203] Norn MS. Dead, degenerate, and living cells in conjunctival fluid and mucous thread. *Acta Ophthalmol (Copenh)* 1969;47:1102–15.
- [204] Garreis F, Gottschalt M, Paulsen FP. Antimicrobial peptides as a major part of the innate immune defense at the ocular surface. *Dev Ophthalmol* 2010;45:16–22.
- [205] Van Haeringen NJ. Clinical biochemistry of tears. *Surv Ophthalmol* 1981;26:84–96.
- [206] Paulsen F. Cell and molecular biology of human lacrimal gland and nasolacrimal duct mucins. *Int Rev Cytol* 2006;249:229–79.
- [207] Bron AJ, Yokoi N, Gafney E, Tiffany JM. Predicted phenotypes of dry eye: proposed consequences of its natural history. *Ocul Surf* 2009;7:78–92.
- [208] Mackie IA, Seal DV. The questionably dry eye. *Br J Ophthalmol* 1981;65:2–9.
- [209] Sack RA, Tan KO, Tan A. Diurnal tear cycle: evidence for a nocturnal inflammatory constitutive tear fluid. *Invest Ophthalmol Vis Sci* 1992;33:626–40.
- [210] Fullard RJ, Carney LG. Diurnal variation in human tear enzymes. *Exp Eye Res* 1984;38:15–26.
- [211] Fullard RJ, Carney LG. Human tear enzyme changes as indicators of the corneal response to anterior hypoxia. *Acta Ophthalmol (Copenh)* 1985;63:678–83.
- [212] Carney LG, Hill RM. Human tear pH. Diurnal variations. *Arch Ophthalmol* 1976;94:821–4.
- [213] Terry JE, Hill RM. Human tear osmotic pressure: diurnal variations and the closed eye. *Arch Ophthalmol* 1978;96:120–2.
- [214] Bonanno JA, Polse KA. Measurement of in vivo human corneal stromal pH: open and closed eyes. *Invest Ophthalmol Vis Sci* 1987;28:522–30.
- [215] McNamara NA, Chan JS, Han SC, Polse KA, McKenney CD. Effects of hypoxia on corneal epithelial permeability. *Am J Ophthalmol* 1999;127:153–7.
- [216] Daum KM, Hill RM. Human tears: glucose instabilities. *Acta Ophthalmol (Copenh)* 1984;62:530–6.
- [217] Jordan A, Baum J. Basic tear flow. Does it exist? *Ophthalmology* 1980;87:920–30.
- [218] Sack RA, Beaton A, Sathe S, Morris C, Willcox M, Bogart B. Towards a closed eye model of the pre-ocular tear layer. *Prog Retin Eye Res* 2000;19:649–68.
- [219] Fullard RJ, Tucker DL. Changes in human tear protein levels with progressively increasing stimulus. *Invest Ophthalmol Vis Sci* 1991;32:2290–301.
- [220] Sack RA, Underwood PA, Tan KO, Sutherland H, Morris CA. Vitronectin: possible contribution to the closed-eye external host-defense mechanism. *Ocul Immunol Inflamm* 1993;1:327–36.
- [221] Sathe S, Sakata M, Beaton AR, Sack RA. Identification, origins and the diurnal role of the principal serine protease inhibitors in human tear fluid. *Curr Eye Res* 1998;17:348–62.
- [222] Lan JX, Willcox MD, Jackson GD, Thakur A. Effect of tear secretory IgA on chemotaxis of polymorphonuclear leucocytes. *Aust N Z J Ophthalmol* 1998;26(Suppl 1):S36–9.
- [223] Connors MS, Stoltz RA, Davis KL, Dunn MW, Abraham NG, Levere RD, et al. A closed eye contact lens model of corneal inflammation. Part 2: inhibition of cytochrome P450 arachidonic acid metabolism alleviates inflammatory sequelae. *Invest Ophthalmol Vis Sci* 1995;36:841–50.
- [224] Willcox MD, Morris CA, Thakur A, Sack RA, Wickson J, Boey W. Complement and complement regulatory proteins in human tears. *Invest Ophthalmol Vis Sci* 1997;38:1–8.
- [225] Sonawane S, Khanolkar V, Namavari A, Chaudhary S, Gandhi S, Tibrewal S, et al. Ocular surface extracellular DNA and nuclease activity imbalance: a new paradigm for inflammation in dry eye disease. *Invest Ophthalmol Vis Sci* 2012;53:8253–63.
- [226] Lande R, Gregorio J, Facchinetti V, Chatterjee B, Wang YH, Homey B, et al. Plasmacytoid dendritic cells sense self-DNA coupled with antimicrobial peptide. *Nature* 2007;449:564–9.
- [227] Pisetsky DS. The origin and properties of extracellular DNA: from PAMP to DAMP. *Clin Immunol* 2012;144:32–40.
- [228] Schnare M, Holt AC, Takeda K, Akira S, Medzhitov R. Recognition of CpG DNA is mediated by signaling pathways dependent on the adaptor protein MyD88. *Curr Biol* 2000;10:1139–42.
- [229] Hayashi F, Means TK, Luster AD. Toll-like receptors stimulate human neutrophil function. *Blood* 2003;102:2660–9.
- [230] Nance SC, Yi AK, Re FC, Fitzpatrick EA. MyD88 is necessary for neutrophil recruitment in hypersensitivity pneumonitis. *J Leukoc Biol* 2008;83:1207–17.
- [231] Krysko DV, Agostinis P, Krysko O, Garg AD, Bachert C, Lambrecht BN, et al. Emerging role of damage-associated molecular patterns derived from mitochondria in inflammation. *Trends Immunol* 2011;32:157–64.
- [232] Chinnery HR, McLaren S, Binz N, Sun Y, Forrester JV, Degli-Esposti MA, et al. TLR9 ligand CpG-ODN applied to the injured mouse cornea elicits retinal inflammation. *Am J Pathol* 2012;180:209–20.
- [233] Gottenberg JE, Cagnard N, Lucchesi C, Letourneur F, Mistou S, Lazure T, et al. Activation of IFN pathways and plasmacytoid dendritic cell recruitment in target organs of primary Sjogren's syndrome. *Proc Natl Acad Sci U S A* 2006;103:2770–5.
- [234] Barabino S, Chen Y, Chauhan S, Dana R. Ocular surface immunity: homeostatic mechanisms and their disruption in dry eye disease. *Prog Retin Eye Res* 2012;31:271–85.
- [235] Corrales RM, Villarreal A, Farley W, Stern ME, Li DQ, Pflugfelder SC. Strain-related cytokine profiles on the murine ocular surface in response to desiccating stress. *Cornea* 2007;26:579–84.
- [236] Fuchs TA, Abed U, Goosmann C, Hurwitz R, Schulze I, Wahn V, et al. Novel cell death program leads to neutrophil extracellular traps. *J Cell Biol* 2007;176:231–41.
- [237] Saffarzadeh M, Juenemann C, Queisser MA, Lochnit G, Barreto G, Galuska SP, et al. Neutrophil extracellular traps directly induce epithelial and endothelial cell death: a predominant role of histones. *PLoS One* 2012;7: e32366.
- [238] Xu J, Zhang X, Pelayo R, Monestier M, Ammollo CT, Semeraro F, et al. Extracellular histones are major mediators of death in sepsis. *Nat Med* 2009;15:1318–21.
- [239] Reinholz M, Ruzicka T, Schaubert J. Cathelicidin LL-37: an antimicrobial peptide with a role in inflammatory skin disease. *Ann Dermatol* 2012;24:126–35.
- [240] Song JS, Kang CM, Rhee CK, et al. Effects of elastase inhibitor on the epithelial cell apoptosis in bleomycin-induced pulmonary fibrosis. *Exp Lung Res* 2009;35:817–29.
- [241] Blalock TD, Spurr-Michaud SJ, Tisdale AS, Gipson IK. Release of membrane-associated mucins from ocular surface epithelia. *Invest Ophthalmol Vis Sci* 2008;49:1864–71.
- [242] Aknin ML, Berry M, Dick AD, Khan-Lim D. Normal but not altered mucins activate neutrophils. *Cell Tissue Res* 2004;318:545–51.
- [243] Medina E. Neutrophil extracellular traps: a strategic tactic to defeat pathogens with potential consequences for the host. *J Innate Immun* 2009;1:176–80.
- [244] Tibrewal S, Ivanir Y, Sarkar J, Nayeb-Hashemi N, Bouchard CS, Kim E, et al. Hyperosmolar stress induces neutrophil extracellular trap formation: implications for dry eye disease. *Invest Ophthalmol Vis Sci* 2014;55:7961–9.
- [245] Tibrewal S, Sarkar J, Jassim SH, Gandhi S, Sonawane S, Chaudhary S, et al. Tear fluid extracellular DNA: diagnostic and therapeutic implications in dry eye disease. *Invest Ophthalmol Vis Sci* 2013;54:8051–61.
- [246] Sullivan BD, Crews LA, Sonmez B, de la Paz MF, Comert E, Charoenrook V, et al. Clinical utility of objective tests for dry eye disease: variability over time and implications for clinical trials and disease management. *Cornea* 2012;31:1000–8.
- [247] Stern ME, Gao J, Siemasko KF, Beuerman RW, Pflugfelder SC. The role of the lacrimal functional unit in the pathophysiology of dry eye. *Exp Eye Res* 2004;78:409–16.
- [248] Paulsen F. The human nasolacrimal ducts. *Adv Anat Embryol Cell Biol* 2003;170(III-XI):1–106.
- [249] Rozsa AJ, Beuerman RW. Density and organization of free nerve endings in the corneal epithelium of the rabbit. *Pain* 1982;14:105–20.
- [250] McGowan DP, Lawrenson JG, Ruskell GL. Touch sensitivity of the eyelid margin and palpebral conjunctiva. *Acta Ophthalmol* 1994;72:57–60.
- [251] Ruskell GL. Distribution of pterygopalatine ganglion efferents to the lacrimal gland in man. *Exp Eye Res* 2004;78:329–35.
- [252] Willshire C, Buckley RJ, Bron AJ. Central connections of the lacrimal functional unit. *Cornea* 2017. in press.
- [253] Schargus M, Geerling G. The “wet” dry eye. *Ophthalmologie* 2009;106:235–8. 40–41.
- [254] Cross DA, Krupin T. Implications of the effects of general anesthesia on basal tear production. *Anesth Analg* 1977;56:35–7.
- [255] Heigle TJ, Pflugfelder SC. Aqueous tear production in patients with neurotrophic keratitis. *Cornea* 1996;15:135–8.
- [256] Murube J, Murube L, Murube A. Origin and types of emotional tearing. *Eur J*



- Ophthalmol 1999;9:77–84.
- [257] Standring S. *Grays Anatomy 40th Edition. Anatomical Basis Of Clinical Practic*. 40. London: Churchill Livingstone; 2008. p. 415.
- [258] Collins M, Seeto R, Campbell L, Ross M. Blinking and corneal sensitivity. *Acta Ophthalmol (Copenh)* 1989;67:525–31.
- [259] Toda I, Asano-Kato N, Komai-Hori Y, Tsubota K. Dry eye after laser in situ keratomileusis. *Am J Ophthalmol* 2001;132:1–7.
- [260] Collins MJ, Kloevekorin-Norgall K, Buehren T, Voetz SC, Lingelbach B. Regression of lid-induced corneal topography changes after reading. *Optom Vis Sci* 2005;82:843–9.
- [261] Tsubota K. Tear dynamics and dry eye. *Prog Retin Eye Res* 1998;17:565–96.
- [262] Tsubota K, Fujishima H, Toda I, Katagiri S, Kawashima Y, Saito I. Increased levels of Epstein-Barr virus DNA in lacrimal glands of Sjogren's syndrome patients. *Acta Ophthalmol Scand* 1995;73:425–30.
- [263] Tsubota K, Satake Y, Shimazaki J. Treatment of severe dry eye. *Lancet* 1996;348:123.
- [264] Alex A, Edwards A, Hays JD, Kerkstra M, Shih A, de Paiva CS, et al. Factors predicting the ocular surface response to desiccating environmental stress. *Invest Ophthalmol Vis Sci* 2013;54:3325–32.
- [265] Moore QL, De Paiva CS, Pflugfelder SC. Effects of dry eye therapies on environmentally induced ocular surface disease. *Am J Ophthalmol* 2015;160:135 e1–42 e1.
- [266] Montes-Mico R, Alio JL, Charman WN. Dynamic changes in the tear film in dry eyes. *Invest Ophthalmol Vis Sci* 2005;46:1615–9.
- [267] Pflugfelder SC. Tear dysfunction and the cornea: LXVIII Edward Jackson memorial lecture. *Am J Ophthalmol* 2011;152:900 e1–9 e1.
- [268] Baudouin C, Aragona P, Messmer EM, Tomlinson A, Calonge M, Boboridis KG, et al. Role of hyperosmolarity in the pathogenesis and management of dry eye disease: proceedings of the OCEAN group meeting. *Ocul Surf* 2013;11:246–58.
- [269] Lemp MA, Bron AJ, Baudouin C, Benitez Del Castillo JM, Geffen D, Tauber J, et al. Tear osmolarity in the diagnosis and management of dry eye disease. *Am J Ophthalmol* 2011;151:792 e1–8 e1.
- [270] Tomlinson A, Khanal S, Ramaesh K, Diaper C, McFadyen A. Tear film osmolarity: determination of a referent for dry eye diagnosis. *Invest Ophthalmol Vis Sci* 2006;47:4309–15.
- [271] Sullivan BD, Pepose JS, Foulks GN. Progressively increased variation in tear osmolarity mirrors dry eye severity. *JAMA Ophthalmol* 2015;133:1481–2.
- [272] Bron AJ, Tiffany JM, Yokoi N, Gouveia SM. Using osmolarity to diagnose dry eye: a compartmental hypothesis and review of our assumptions. *Adv Exp Med Biol* 2002;506:1087–95.
- [273] Begley CG, Himebaugh N, Renner D, Liu H, Chalmers R, Simpson T, et al. Tear breakup dynamics: a technique for quantifying tear film instability. *Optom Vis Sci* 2006;83:15–21.
- [274] Liu H, Begley CG, Chalmers R, Wilson G, Srinivas SP, Wilkinson JA. Temporal progression and spatial repeatability of tear breakup. *Optom Vis Sci* 2006;83:723–30.
- [275] Harrison WW, Begley CG, Liu H, Chen M, Garcia M, Smith JA. Menisci and fullness of the blink in dry eye. *Optom Vis Sci* 2008;85:706–14.
- [276] Liu H, Begley C, Chen M, Bradley A, Bonanno J, McNamara NA, et al. A link between tear instability and hyperosmolarity in dry eye. *Invest Ophthalmol Vis Sci* 2009;50:3671–9.
- [277] Braun RJ, Gewecke NR, Begley CG, King-Smith PE, Siddique JI. A model for tear film thinning with osmolarity and fluorescein. *Invest Ophthalmol Vis Sci* 2014;55:1133–42.
- [278] Braun RJ, King-Smith PE, Begley CG, Li L, Gewecke NR. Dynamics and function of the tear film in relation to the blink cycle. *Prog Retin Eye Res* 2015;45:132–64.
- [279] Peng CC, Cerretani C, Braun RJ, Radke CJ. Evaporation-driven instability of the precorneal tear film. *Adv Colloid Interface Sci* 2014;206:250–64.
- [280] Nichols JJ, King-Smith PE, Hinel EA, Thangavelu M, Nichols KK. The use of fluorescent quenching in studying the contribution of evaporation to tear thinning. *Invest Ophthalmol Vis Sci* 2012;53:5426–32.
- [281] Sullivan BD, Whitmer D, Nichols KK, Tomlinson A, Foulks GN, Geerling G, et al. An objective approach to dry eye disease severity. *Invest Ophthalmol Vis Sci* 2010;51:6125–30.
- [282] Szalai E, Berta A, Szekanez Z, Szucs G, Modis Jr L. Evaluation of tear osmolarity in non-Sjogren and Sjogren syndrome dry eye patients with the TearLab system. *Cornea* 2012;31:867–71.
- [283] Fortes MB, Diment BC, Di Felice U, Gunn AE, Kendall JL, Esmaeelpour M, et al. Tear fluid osmolarity as a potential marker of hydration status. *Med Sci Sports Exerc* 2011;43:1590–7.
- [284] Walsh NP, Fortes MB, Esmaeelpour M. Influence of modest changes in whole-body hydration on tear fluid osmolarity: important considerations for dry eye disease detection. *Cornea* 2011;30:1517. author reply 1517–1518.
- [285] Walsh NP, Fortes MB, Raymond-Barker P, Bishop C, Owen J, Tye E, et al. Is whole-body hydration an important consideration in dry eye? *Invest Ophthalmol Vis Sci* 2012;53:6622–7.
- [286] Craig JP, Tomlinson A. Effect of age on tear osmolality. *Optom Vis Sci* 1995;72:713–7.
- [287] Arciniega JC, Wojtowicz JC, Mohamed EM, McCulley JP. Changes in the evaporation rate of tear film after digital expression of meibomian glands in patients with and without dry eye. *Cornea* 2011;30:843–7.
- [288] Tsubota K, Nakamori K. Effects of ocular surface area and blink rate on tear dynamics. *Arch Ophthalmol* 1995;113:155–8.
- [289] Ousler 3rd GW, Rodriguez JD, Smith LM, Lane KJ, Heckley C, Angjeli E, et al. Optimizing reading tests for dry eye disease. *Cornea* 2015;34:917–21.
- [290] Jansen ME, Begley CG, Himebaugh NH, Port NL. Effect of contact lens wear and a near task on tear film break-up. *Optom Vis Sci* 2010;87:350–7.
- [291] Tsubota K, Shimmura S, Shinozaki N, Holland EJ, Shimazaki J. Clinical application of living-related conjunctival-limbal allograft. *Am J Ophthalmol* 2002;133:134–5.
- [292] Rieger G. The importance of the precorneal tear film for the quality of optical imaging. *Br J Ophthalmol* 1992;76:157–8.
- [293] Tutt R, Bradley A, Begley C, Thibos LN. Optical and visual impact of tear break-up in human eyes. *Invest Ophthalmol Vis Sci* 2000;41:4117–23.
- [294] Puell MC, Benitez-del-Castillo JM, Martinez-de-la-Casa J, Sanchez-Ramos C, Vico E, Perez-Carrasco MJ, et al. Contrast sensitivity and disability glare in patients with dry eye. *Acta Ophthalmol Scand* 2006;84:527–31.
- [295] Diaz-Valle D, Arriola-Villalobos P, Garcia-Vidal SE, Sanchez-Pulgarin M, Borrego Sanz L, Gegundez-Fernandez JA, et al. Effect of lubricating eyedrops on ocular light scattering as a measure of vision quality in patients with dry eye. *J Cataract Refract Surg* 2012;38:1192–7.
- [296] Ridder 3rd WH, Tomlinson A, Huang JF, Li J. Impaired visual performance in patients with dry eye. *Ocul Surf* 2011;9:42–55.
- [297] Kaido M, Dogru M, Ishida R, Tsubota K. Concept of functional visual acuity and its applications. *Cornea* 2007;26:S29–35.
- [298] Kaido M, Uchino MN, Uchino Y, Dogru M, Kawashima M, et al. Dry-eye screening by using a functional visual acuity measurement system: the Osaka Study. *Invest Ophthalmol Vis Sci* 2014;55:3275–81.
- [299] Lemp MA. Tear substitutes in the treatment of dry eyes. *Int Ophthalmol Clin* 1973;13:145–53.
- [300] Ousler 3rd GW, Hagberg KW, Schindelar M, Welch D, Abelson MB. The Ocular Protection Index. *Cornea* 2008;27:509–13.
- [301] Ruiz-Ederra J, Levin MH, Verkman AS. In situ fluorescence measurement of tear film [Na<sup>+</sup>], [K<sup>+</sup>], [Cl<sup>-</sup>], and pH in mice showing marked hypertonicity in aquaporin-5 deficiency. *Invest Ophthalmol Vis Sci* 2009;50:2132–8.
- [302] Ogasawara K, Mitsubayashi K, Tsuru T, Karube I. Electrical conductivity of tear fluid in healthy persons and keratoconjunctivitis sicca patients measured by a flexible conductimetric sensor. *Graefes Arch Clin Exp Ophthalmol* 1996;234:542–6.
- [303] Gupta Y, Gupta M, Rizvi SA, Gupta M. 'Xerosis meter': a new concept in dry eye evaluation. *Graefes Arch Clin Exp Ophthalmol* 2006;244:9–13.
- [304] Tsubota K, Yamada M. Tear evaporation from the ocular surface. *Invest Ophthalmol Vis Sci* 1992;33:2942–50.
- [305] Uchiyama E, Aronowicz JD, Butovich IA, McCulley JP. Increased evaporative rates in laboratory testing conditions simulating airplane cabin relative humidity: an important factor for dry eye syndrome. *Eye Contact Lens* 2007;33:174–6.
- [306] Enriquez-de-Salamanca A, Castellanos E, Stern ME, Fernandez I, Carreno E, Garcia-Vazquez C, et al. Tear cytokine and chemokine analysis and clinical correlations in evaporative-type dry eye disease. *Mol Vis* 2010;16:862–73.
- [307] Beardsley RM, De Paiva CS, Power DF, Pflugfelder SC. Desiccating stress decreases apical corneal epithelial cell size—modulation by the metalloproteinase inhibitor doxycycline. *Cornea* 2008;27:935–40.
- [308] Li MO, Wan YY, Sanjabi S, Robertson AK, Flavell RA. Transforming growth factor-beta regulation of immune responses. *Annu Rev Immunol* 2006;24:99–146.
- [309] Luo L, Li DQ, Doshi A, Farley W, Corrales RM, Pflugfelder SC. Experimental dry eye stimulates production of inflammatory cytokines and MMP-9 and activates MAPK signaling pathways on the ocular surface. *Invest Ophthalmol Vis Sci* 2004;45:4293–301.
- [310] Li DQ, Chen Z, Song XJ, Farley W, Pflugfelder SC. Hyperosmolarity Stimulates Production of MMP-9, IL-1 $\alpha$  and TNF- by Human Corneal Epithelial Cells Via a c-Jun NH 2- terminal kinase pathway. *Invest Ophthalmol Vis Sci* 2002;43: EAbstract 1981.
- [311] Li DQ, Chen Z, Song XJ, Luo L, Pflugfelder SC. Stimulation of matrix metalloproteinases by hyperosmolarity via a JNK pathway in human corneal epithelial cells. *Invest Ophthalmol Vis Sci* 2004;45:4302–11.
- [312] Li DQ, Lokeshwar BL, Solomon A, Monroy D, Ji Z, Pflugfelder SC. Regulation of MMP-9 production by human corneal epithelial cells. *Exp Eye Res* 2001;73:449–59.
- [313] Kim HS, Luo L, Pflugfelder SC, Li DQ. Doxycycline inhibits TGF-beta1-induced MMP-9 via Smad and MAPK pathways in human corneal epithelial cells. *Invest Ophthalmol Vis Sci* 2005;46:840–8.
- [314] Huet E, Vallee B, Delbe J, Mourah S, Prulliere-Escabasse V, Tremouilleres M, et al. EMMPRIN modulates epithelial barrier function through a MMP-mediated occludin cleavage: implications in dry eye disease. *Am J Pathol* 2011;179:1278–86.
- [315] Pflugfelder SC, de Paiva CS, Tong L, Luo L, Stern ME, Li DQ. Stress-activated protein kinase signaling pathways in dry eye and ocular surface disease. *Ocul Surf* 2005;3:S154–7.
- [316] Chotikavanich S, de Paiva CS, D-Q L, Chen JJ, Bian F, Farley WJ, et al. Production and activity of matrix Metalloproteinase-9 on the ocular surface increase in dysfunctional tear syndrome. *Invest Ophthalmol Vis Sci* 2009;50:3203–9.
- [317] Schargus M, Ivanova S, Kakkassery V, Dick HB, Joachim S. Correlation of Tear Film Osmolarity and 2 Different MMP-9 Tests With Common Dry Eye Tests in a Cohort of Non-Dry Eye Patients. *Cornea* 2015;34:739–44.
- [318] VanDerMeid KR, Su SP, Ward KW, Zhang JZ. Correlation of tear inflammatory

- cytokines and matrix metalloproteinases with four dry eye diagnostic tests. *Invest Ophthalmol Vis Sci* 2012;53:1512–8.
- [319] Gabison EE, Huet E, Baudouin C, Menashi S. Direct epithelial-stromal interaction in corneal wound healing: Role of EMMPRIN/CD147 in MMPs induction and beyond. *Prog Retin Eye Res* 2009;28:19–33.
- [320] Labbe A, Gabison E, Brignole-Baudouin F, Riancho L, Menashi S, Baudouin C. Increased extracellular matrix metalloproteinase inducer (EMMPRIN) expression in the conjunctival epithelium exposed to antiglaucoma treatments. *Curr Eye Res* 2015;40:40–7.
- [321] Mauris J, Mantelli F, Woodward AM, Cao Z, Bertozzi CR, Panjwani N, et al. Modulation of ocular surface glycocalyx barrier function by a galectin-3 N-terminal deletion mutant and membrane-anchored synthetic glycopolymers. *PLoS One* 2013;8: e72304.
- [322] Pult H, Korb DR, Murphy PJ, Riede-Pult BH, Blackie C. A new model of central lid margin apposition and tear film mixing in spontaneous blinking. *Cont Lens Anterior Eye* 2015;38:173–80.
- [323] Ehlers N. The Precorneal Film. *Biomicroscopical, Histological and Chemical Investigations*. *Acta Ophthalmol Suppl* 1965;(Suppl 81):81–134.
- [324] Korb DR, Herman JP, Blackie CA, Scaffidi RC, Greiner JV, Exford JM, et al. Prevalence of lid wiper epitheliopathy in subjects with dry eye signs and symptoms. *Cornea* 2010;29:377–83.
- [325] Pult H, Tosatti SG, Spencer ND, Asfour JM, Ebenhoch M, Murphy PJ. Spontaneous Blinking from a Tribological Viewpoint. *Ocul Surf* 2015;13:236–49.
- [326] Jones MB, Fulford GR, Please CP, McElwain DL, Collins MJ. Elastohydrodynamics of the eyelid wiper. *Bull Math Biol* 2008;70:323–43.
- [327] Bielecki P, Komor U, Bielecka A, Musken M, Puchalka J, Pletz MW, et al. Ex vivo transcriptional profiling reveals a common set of genes important for the adaptation of *Pseudomonas aeruginosa* to chronically infected host sites. *Environ Microbiol* 2013;15:570–87.
- [328] Bielecki T, Dohan Ehrenfest DM. Platelet-rich plasma (PRP) and Platelet-Rich Fibrin (PRF): surgical adjuvants, preparations for in situ regenerative medicine and tools for tissue engineering. *Curr Pharm Biotechnol* 2012;13:1121–30.
- [329] Swann DA, Slayter HS, Silver FH. The molecular structure of lubricating glycoprotein-I, the boundary lubricant for articular cartilage. *J Biol Chem* 1981;256:5921–5.
- [330] Cheriyan T, Schmid TM, Spector M. Presence and distribution of the lubricating protein, lubricin, in the meibomian gland in rabbits. *Mol Vis* 2011;17:3055–61.
- [331] Morrison S, Sullivan DA, Sullivan BD, Sheardown H, Schmidt TA. Dose-dependent and synergistic effects of proteoglycan 4 on boundary lubrication at a human cornea-polydimethylsiloxane biointerface. *Eye Contact Lens* 2012;38:27–35.
- [332] Samsom ML, Morrison S, Masala N, Sullivan BD, Sullivan DA, Sheardown H, et al. Characterization of full-length recombinant human Proteoglycan 4 as an ocular surface boundary lubricant. *Exp Eye Res* 2014;127:14–9.
- [333] Lambiase A, Sullivan BD, Schmidt TA, Sullivan DA, Jay G, Truitt ERI, et al. A two-week, randomized, double-masked study to evaluate safety and efficacy of lubricin (150 µg/ml) eye drops versus sodium hyaluronate (HA) 0.18% eye drops (Vismed®) in patients with moderate dry eye disease. *Ocul Surf* 2017;15:77–87.
- [334] Doane MG. Interactions of eyelids and tears in corneal wetting and the dynamics of the normal human eyeblink. *Am J Ophthalmol* 1980;89:507–16.
- [335] Cher I. Another way to think of tears: blood, sweat, and... "dacruon". *Ocul Surf* 2007;5:251–4.
- [336] Cher I. Fluids of the ocular surface: concepts, functions and physics. *Clin Exp Ophthalmol* 2012;40:634–43.
- [337] Dunn AC, Sawyer WG, Angelini TE. Gemini Interfaces in Aqueous Lubrication with Hydrogels. *Tribol Lett* 2014;54:59–66.
- [338] Pandit JC, Nagyova B, Bron AJ, Tiffany JM. Physical properties of stimulated and unstimulated tears. *Exp Eye Res* 1999;68:247–53.
- [339] Tiffany JM. The viscosity of human tears. *Int Ophthalmol* 1991;15:371–6.
- [340] Tiffany JM, Bron AJ, Mossa F, Dikstein S. Delivery of meibomian oil using the Clinical Meibometer. *Adv Exp Med Biol* 1998;438:333–8.
- [341] Donald C, Hamilton L, Doughty M. A quantitative assessment of the location and width of Marx's line along the marginal zone of the human eyelid. *Optom Vis Sci* 2003;80:564–72.
- [342] Korb DR, Herman JP, Greiner JV, Scaffidi RC, Finnemore VM, Exford JM, et al. Lid wiper epitheliopathy and dry eye symptoms. *Eye Contact Lens* 2005;31:2–8.
- [343] Pult H, Riede-Pult BH, Murphy PJ. The relation between blinking and conjunctival folds and dry eye symptoms. *Optom Vis Sci* 2013;90:1034–9.
- [344] Korb DR, Greiner JV, Herman JP, Hebert E, Finnemore VM, Exford JM, et al. Lid-wiper epitheliopathy and dry-eye symptoms in contact lens wearers. *CLAO J* 2002;28:211–6.
- [345] Parsons JT, Bova FJ, Fitzgerald CR, Mendenhall WM, Million RR. Severe dry-eye syndrome following external beam irradiation. *Int J Radiat Oncol Biol Phys* 1994;30:775–80.
- [346] Shiraishi A, Yamaguchi M, Ohashi Y. Prevalence of upper- and lower-lid-wiper epitheliopathy in contact lens wearers and non-wearers. *Eye Contact Lens* 2014;40:220–4.
- [347] Shaw AJ, Collins MJ, Davis BA, Carney LG. Eyelid pressure and contact with the ocular surface. *Invest Ophthalmol Vis Sci* 2010;51:1911–7.
- [348] Bron AJ, Argueso P, Irkec M, Bright FV. Clinical staining of the ocular surface: mechanisms and interpretations. *Prog Retin Eye Res* 2015;44:36–61.
- [349] Tseng SC. Concept and application of limbal stem cells. *Eye (Lond)* 1989;3(Pt 2):141–57.
- [350] Bandamwar KL, Papas EB, Garrett Q. Fluorescein staining and physiological state of corneal epithelial cells. *Cont Lens Anterior Eye* 2014;37:213–23.
- [351] Dundas M, Walker A, Woods RL. Clinical grading of corneal staining of non-contact lens wearers. *Ophthalmic Physiol Opt* 2001;21:30–5.
- [352] Norn MS. Vital staining of cornea and conjunctiva. *Acta Ophthalmol (Copenh)* 1962;40:389–401.
- [353] Korb DR, Korb JM. Corneal staining prior to contact lens wearing. *J Am Optom Assoc* 1970;41:228–32.
- [354] Korb DR, Herman JP. Corneal staining subsequent to sequential fluorescein instillations. *J Am Optom Assoc* 1979;50:361–7.
- [355] Josephson JE, Caffery BE. Corneal staining after instillation of topical anesthetic (SSII). *Invest Ophthalmol Vis Sci* 1988;29:1096–9.
- [356] Caffery BE, Josephson JE. Corneal staining after sequential instillations of fluorescein over 30 days. *Optom Vis Sci* 1991;68:467–9.
- [357] Brautaset RL, Nilsson M, Leach N, Miller WL, Gire A, Quintero S, et al. Corneal and conjunctival epithelial staining in hydrogel contact lens wearers. *Eye Contact Lens* 2008;34:312–6.
- [358] Efron N. Response to re: putting vital stains in context. *Clin Exp Optom* 2013;96:511–2.
- [359] Lakkis C, Brennan NA. Bulbar conjunctival fluorescein staining in hydrogel contact lens wearers. *CLAO J* 1996;22:189–94.
- [360] Norn MS. Desiccation of the precorneal film. I. Corneal wetting-time. *Acta Ophthalmol (Copenh)* 1969;47:865–80.
- [361] Soni PS, Horner DG, Ross J. Ocular response to lens care systems in adolescent soft contact lens wearers. *Optom Vis Sci* 1996;73:70–85.
- [362] Schwallye JD, Long Jr WD, McKenney CD. Day to day variations in ocular surface staining of the bulbar conjunctiva. *Optom Vis Sci* 1998;75:55–61.
- [363] Mokhtarzadeh M, Casey R, Glasgow BJ. Fluorescein punctate staining traced to superficial corneal epithelial cells by impression cytology and confocal microscopy. *Invest Ophthalmol Vis Sci* 2011;52:2127–35.
- [364] Morgan PB, Maldonado-Codina C. Corneal staining: do we really understand what we are seeing? *Cont Lens Anterior Eye* 2009;32:48–54.
- [365] Ward KW. Superficial punctate fluorescein staining of the ocular surface. *Optom Vis Sci* 2008;85:8–16.
- [366] Luensmann D, Moezzi A, Peterson RC, Woods C, Fonn D. Corneal staining and cell shedding during the development of solution-induced corneal staining. *Optom Vis Sci* 2012;89:868–74.
- [367] Zhou J, Begley CG, Wright A, Wilson G, Tokarski T. Characterization of cells collected from the normal human ocular surface by contact lens cytology. *Cornea* 2000;19:824–32.
- [368] Ren H, Wilson G. Apoptosis in the corneal epithelium. *Invest Ophthalmol Vis Sci* 1996;37:1017–25.
- [369] Estil S, Primo EJ, Wilson G. Apoptosis in shed human corneal cells. *Invest Ophthalmol Vis Sci* 2000;41:3360–4.
- [370] Feenstra RP, Tseng SC. What is actually stained by rose bengal? *Arch Ophthalmol* 1992;110:984–93.
- [371] Feenstra RP, Tseng SC. Comparison of fluorescein and rose bengal staining. *Ophthalmology* 1992;99:605–17.
- [372] Wilson G, Ren H, Laurent J. Corneal epithelial fluorescein staining. *J Am Optom Assoc* 1995;66:435–41.
- [373] Kikkawa Y. Normal corneal staining with fluorescein. *Exp Eye Res* 1972;14:13–20.
- [374] Bandamwar KL, Garrett Q, Papas EB. Mechanisms of superficial micro-punctate corneal staining with sodium fluorescein: the contribution of pooling. *Cont Lens Anterior Eye* 2012;35:81–4.
- [375] Shimazaki J, Goto E, Ono M, Shimmura S, Tsubota K. Meibomian gland dysfunction in patients with Sjogren syndrome. *Ophthalmology* 1998;105:1485–8.
- [376] Shimazaki J, Sakata M, Tsubota K. Ocular surface changes and discomfort in patients with meibomian gland dysfunction. *Arch Ophthalmol* 1995;113:1266–70.
- [377] Baudouin C. A new approach for better comprehension of diseases of the ocular surface. *J Fr Ophtalmol* 2007;30:239–46.
- [378] De Paiva CS, Corrales RM, Villarreal AL, Farley WJ, Li DQ, Stern ME, et al. Corticosteroid and doxycycline suppress MMP-9 and inflammatory cytokine expression, MAPK activation in the corneal epithelium in experimental dry eye. *Exp Eye Res* 2006;83:526–35.
- [379] Baudouin C. The pathology of dry eye. *Surv Ophthalmol* 2001;45(Suppl 2):S211–20.
- [380] Yeh S, Song XJ, Farley W, Li DQ, Stern ME, Pflugfelder SC. Apoptosis of ocular surface cells in experimentally induced dry eye. *Invest Ophthalmol Vis Sci* 2003;44:124–9.
- [381] Brignole F, Pisella PJ, Goldschild M, De Saint Jean M, Goguel A, Baudouin C. Flow cytometric analysis of inflammatory markers in conjunctival epithelial cells of patients with dry eyes. *Invest Ophthalmol Vis Sci* 2000;41:1356–63.
- [382] Kunert KS, Tisdale AS, Gipson IK. Goblet cell numbers and epithelial proliferation in the conjunctiva of patients with dry eye syndrome treated with cyclosporine. *Arch Ophthalmol* 2002;120:330–7.
- [383] Argueso P, Balaram M, Spurr-Michaud S, Keutmann HT, Dana MR, Gipson IK. Decreased levels of the goblet cell mucin MUC5AC in tears of patients with Sjogren syndrome. *Invest Ophthalmol Vis Sci* 2002;43:1004–11.
- [384] Zhao H, Jumblatt JE, Wood TO, Jumblatt MM. Quantification of MUC5AC protein in human tears. *Cornea* 2001;20:873–7.

- [385] Baudouin C, Messmer EM, Aragona P, Geerling G, Akova YA, Benitez-Del-Castillo J, et al. Revisiting the vicious circle of dry eye disease: a focus on the pathophysiology of meibomian gland dysfunction. *Br J Ophthalmol* 2016;100:300–6.
- [386] Abreau K, Callan C, Kottaiyan R, Zhang A, Yoon G, Aquavella JV, et al. Temperatures of the Ocular Surface, Lid, and Periorbital Regions of Sjogren's, Evaporative, and Aqueous-Deficient Dry Eyes Relative to Normals. *Ocul Surf* 2016;14:64–73.
- [387] De Paiva CS, Pflugfelder SC. Corneal epitheliopathy of dry eye induces hyperesthesia to mechanical air jet stimulation. *Am J Ophthalmol* 2004;137:109–15.
- [388] Xu KP, Yagi Y, Toda I, Tsubota K. Tear function index. A new measure of dry eye. *Arch Ophthalmol* 1995;113:84–8.
- [389] Bourcier T, Acosta MC, Borderie V, Borrás F, Gallar J, Bury T, et al. Decreased corneal sensitivity in patients with dry eye. *Invest Ophthalmol Vis Sci* 2005;46:2341–5.
- [390] Villani E, Magnani F, Viola F, Santaniello A, Scorza R, Nucci P, et al. In vivo confocal evaluation of the ocular surface morpho-functional unit in dry eye. *Optom Vis Sci* 2013;90:576–86.
- [391] Begley C, Simpson T, Liu H, Salvo E, Wu Z, Bradley A, et al. Quantitative analysis of tear film fluorescence and discomfort during tear film instability and thinning. *Invest Ophthalmol Vis Sci* 2013;54:2645–53.
- [392] Vehof J, Sillevius Smitt-Kamminga N, Kozareva D, Nibourg SA, Hammond CJ. Clinical Characteristics of Dry Eye Patients With Chronic Pain Syndromes. *Am J Ophthalmol* 2016;162:59 e2–65 e2.
- [393] Pflugfelder SC, Maskin SL, Anderson B, Chodosh J, Holland EJ, De Paiva CS, et al. A randomized, double-masked, placebo-controlled, multicenter comparison of loteprednol etabonate ophthalmic suspension, 0.5%, and placebo for treatment of keratoconjunctivitis sicca in patients with delayed tear clearance. *Am J Ophthalmol* 2004;138:444–57.
- [394] Hirata H, Rosenblatt ML. Hyperosmolar tears enhance cooling sensitivity of the corneal nerves in rats: possible neural basis for cold-induced dry eye pain. *Invest Ophthalmol Vis Sci* 2014;55:5821–33.
- [395] Madrid R, de la Pena E, Donovan-Rodriguez T, Belmonte C, Viana F. Variable threshold of trigeminal cold-thermosensitive neurons is determined by a balance between TRPM8 and Kv1 potassium channels. *J Neurosci* 2009;29:3120–31.
- [396] Chen L, Li J, Guo T, Ghosh S, Koh SK, Tian D, et al. Global Metabonomic and Proteomic Analysis of Human Conjunctival Epithelial Cells (IOBA-NHC) in Response to Hyperosmotic Stress. *J Proteom Res* 2015;14:3982–95.
- [397] Tabery HM. Dual appearance of fluorescein staining in vivo of diseased human corneal epithelium. A non-contact photomicrographic study. *Br J Ophthalmol* 1992;76:43–4.
- [398] Tabery HM. Micropunctate fluorescein staining of the human corneal surface: microerosions or cystic spaces? A non-contact photomicrographic in vivo study. *Acta Ophthalmol Scand* 1997;75:134–6.
- [399] Watanabe H, Fabricant M, Tisdale AS, Spurr-Michaud SJ, Lindberg K, Gipson IK. Human corneal and conjunctival epithelia produce a mucin-like glycoprotein for the apical surface. *Invest Ophthalmol Vis Sci* 1995;36:337–44.
- [400] Danjo Y, Watanabe H, Tisdale AS, George M, Tsumura T, Abelson MB, et al. Alteration of mucin in human conjunctival epithelia in dry eye. *Invest Ophthalmol Vis Sci* 1998;39:2602–9.
- [401] Pflugfelder SC, Tseng SC, Yoshino K, Monroy D, Felix C, Reis BL. Correlation of goblet cell density and mucosal epithelial membrane mucin expression with rose bengal staining in patients with ocular irritation. *Ophthalmology* 1997;104:223–35.
- [402] Glasgow BJ, Gasymov OK, Casey RC. Exfoliative epitheliopathy of bullous keratopathy with breaches in the MUC16 Glycocalyx. *Invest Ophthalmol Vis Sci* 2009;50:4060–4.
- [403] Komuro A, Yokoi N, Fukuoka H, Kinoshita S. Evaluation of Galectin-3 expression in rose bengal-stained conjunctival epithelium. *Invest Ophthalmol Vis Sci* 2012;53:3994.
- [404] Williams KK, Watsky MA. Bicarbonate promotes dye coupling in the epithelium and endothelium of the rabbit cornea. *Curr Eye Res* 2004;28:109–20.
- [405] McMonnies CW. An examination of the relationship between ocular surface tear osmolarity compartments and epitheliopathy. *Ocul Surf* 2015;13:110–7.
- [406] Abelson MB, Holly FJ. A tentative mechanism for inferior punctate keratopathy. *Am J Ophthalmol* 1977;83:866–9.
- [407] Collin SP, Collin HB. The corneal epithelial surface in the eyes of vertebrates: environmental and evolutionary influences on structure and function. *J Morphol* 2006;267:273–91.
- [408] Cruz AA, Garcia DM, Pinto CT, Cechetti SP. Spontaneous eyeblink activity. *Ocul Surf* 2011;9:29–41.
- [409] Himebaugh NL, Begley CG, Bradley A, Wilkinson JA. Blinking and tear break-up during four visual tasks. *Optom Vis Sci* 2009;86:E106–14.
- [410] Ousler 3rd GW, Abelson MB, Johnston PR, Rodriguez J, Lane K, Smith LM. Blink patterns and lid-contact times in dry-eye and normal subjects. *Clin Ophthalmol* 2014;8:869–74.
- [411] Zubkov VS, Breward CJ, Gaffney EA. Meniscal tear film fluid dynamics near Marx's line. *Bull Math Biol* 2013;75:1524–43.
- [412] Chen AL, Riley DE, King SA, Joshi AC, Serra A, Liao K, et al. The disturbance of gaze in progressive supranuclear palsy: implications for pathogenesis. *Front Neurol* 2010;1:147.
- [413] Richardson C, Smith T, Schaefer A, Turnbull D, Griffiths P. Ocular motility findings in chronic progressive external ophthalmoplegia. *Eye (Lond)* 2005;19:258–63.
- [414] Fells P. Management of dysthyroid eye disease. *Br J Ophthalmol* 1991;75:245–6.
- [415] Tanioka H, Yokoi N, Komuro A, Shimamoto T, Kawasaki S, Matsuda A, et al. Investation of the corneal filament in filamentary keratitis. *Invest Ophthalmol Vis Sci* 2009;50:3696–702.
- [416] Hamilton W, Wood TO. Filamentary keratitis. *Am J Ophthalmol* 1982;93:466–9.
- [417] Theodore FH. Superior limbic keratoconjunctivitis. *Eye Ear Nose Throat Mon* 1963;42:25–8.
- [418] Nelson JD. Superior limbic keratoconjunctivitis (SLK). *Eye (Lond)* 1989;3(Pt 2):180–9.
- [419] Tenzel RR. Comments on superior limbic filamentous keratitis: II. *Arch Ophthalmol* 1968;79:508.
- [420] Yokoi N. Tear dynamics and dry eye. *Nippon Ganka Gakkai Zasshi* 2004;108:275–6.
- [421] Yokoi N, Inatomi T, Kinoshita S. Surgery of the conjunctiva. *Dev Ophthalmol* 2008;41:138–58.
- [422] Yokoi N, Komuro A, Maruyama K, Tsuzuki M, Miyajima S, Kinoshita S. New surgical treatment for superior limbic keratoconjunctivitis and its association with conjunctivochalasis. *Am J Ophthalmol* 2003;135:303–8.
- [423] Stephens DN, McNamara NA. Altered Mucin and Glycoprotein Expression in Dry Eye Disease. *Optom Vis Sci* 2015;92:931–8.
- [424] Watanabe H, Maeda N, Kiritoshi A, Hamano T, Shimomura Y, Tano Y. Expression of a mucin-like glycoprotein produced by ocular surface epithelium in normal and keratinized cells. *Am J Ophthalmol* 1997;124:751–7.
- [425] Shimazaki-Den S, Dogru M, Higa K, Shimazaki J. Symptoms, visual function, and mucin expression of eyes with tear film instability. *Cornea* 2013;32:1211–8.
- [426] Jones DT, Monroy D, Ji Z, Pflugfelder SC. Alterations of ocular surface gene expression in Sjogren's syndrome. *Adv Exp Med Biol* 1998;438:533–6.
- [427] Corrales RM, de Paiva CS, Li DQ, Farley WJ, Henriksson JT, Bergmanson JP, et al. Entrapment of conjunctival goblet cells by desiccation-induced cornification. *Invest Ophthalmol Vis Sci* 2011;52:3492–9.
- [428] Hayashi Y, Kao WW, Kohno N, Nishihara-Hayashi M, Shiraishi A, Uno T, et al. Expression patterns of sialylated epitope recognized by KL-6 monoclonal antibody in ocular surface epithelium of normals and dry eye patients. *Invest Ophthalmol Vis Sci* 2004;45:2212–7.
- [429] Caffery B, Joyce E, Heynen ML, Jones L, Ritter 3rd R, Gamache DA, et al. MUC16 expression in Sjogren's syndrome, KCS, and control subjects. *Mol Vis* 2008;14:2547–55.
- [430] Gipson IK, Spurr-Michaud SJ, Senchyna M, Ritter 3rd R, Schaumberg D. Comparison of mucin levels at the ocular surface of postmenopausal women with and without a history of dry eye. *Cornea* 2011;30:1346–52.
- [431] Srinivasan S, Heynen ML, Martell E, Ritter 3rd R, Jones L, Senchyna M. Quantification of MUCIN 1, cell surface associated and MUCIN16, cell surface associated proteins in tears and conjunctival epithelial cells collected from postmenopausal women. *Mol Vis* 2013;19:970–9.
- [432] Garcher C, Bron A, Baudouin C, Bildstein L, Bara JCA. 19-9 ELISA test: a new method for studying mucus changes in tears. *Br J Ophthalmol* 1998;82:88–90.
- [433] Argueso P, Tisdale A, Mandel U, Letko E, Foster CS, Gipson IK. The cell-layer- and cell-type-specific distribution of GalNAC-transferases in the ocular surface epithelia is altered during keratinization. *Invest Ophthalmol Vis Sci* 2003;44:86–92.
- [434] Ralph RA. Conjunctival goblet cell density in normal subjects and in dry eye syndromes. *Invest Ophthalmol* 1975;14:299–302.
- [435] Kinoshita S, Kiorpes TC, Friend J, Thoft RA. Goblet cell density in ocular surface disease. A better indicator than tear mucin. *Arch Ophthalmol* 1983;101:1284–7.
- [436] Nelson JD, Wright JC. Conjunctival goblet cell densities in ocular surface disease. *Arch Ophthalmol* 1984;102:1049–51.
- [437] Blodi BA, Byrne KA, Tabbara KF. Goblet cell population among patients with inactive trachoma. *Int Ophthalmol* 1988;12:41–5.
- [438] Albietz J, Sanfilippo P, Troutbeck R, Lenton LM. Management of filamentary keratitis associated with aqueous-deficient dry eye. *Optom Vis Sci* 2003;80:420–30.
- [439] Murube J, Rivas L. Impression cytology on conjunctiva and cornea in dry eye patients establishes a correlation between squamous metaplasia and dry eye clinical severity. *Eur J Ophthalmol* 2003;13:115–27.
- [440] Zhang BG, Du T, Zang MD, Chang Q, Fan ZY, Li JF, et al. Androgen receptor promotes gastric cancer cell migration and invasion via AKT-phosphorylation dependent upregulation of matrix metalloproteinase 9. *Oncotarget* 2014;5:10584–95.
- [441] Pflugfelder SC, Stern ME. Mucosal environmental sensors in the pathogenesis of dry eye. *Expert Rev Clin Immunol* 2014;10:1137–40.
- [442] Uchino M, Uchino Y, Dogru M, Kawashima M, Yokoi N, Komuro A, et al. Dry eye disease and work productivity loss in visual display users: the Osaka study. *Am J Ophthalmol* 2014;157:294–300.
- [443] Versura P, Maltarello MC, Cellini M, Caramazza R, Laschi R. Detection of mucus glycoconjugates in human conjunctiva by using the lectin-colloidal

- gold technique in TEM. II. A quantitative study in dry-eye patients. *Acta Ophthalmol (Copenh)* 1986;64:451–5.
- [444] Tapasztó B, Veres A, Kosina-Hagyo K, Somfai GM, Nemeth J. OCT Imaging of lid-parallel conjunctival folds in soft contact lens wearers. *Optom Vis Sci* 2011;88:1206–13.
- [445] Nemeth J, Fodor E, Lang Z, Kosina-Hagyo K, Berta A, Komar T, et al. Lid-parallel conjunctival folds (LIPCOF) and dry eye: a multicentre study. *Br J Ophthalmol* 2012;96:1380–5.
- [446] Meller D, Tseng SC. Conjunctivochalasis: literature review and possible pathophysiology. *Surv Ophthalmol* 1998;43:225–32.
- [447] Watanabe A, Yokoi N, Kinoshita S, Hino Y, Tsuchihashi Y. Clinicopathologic study of conjunctivochalasis. *Cornea* 2004;23:294–8.
- [448] Murube J. Characteristics and etiology of conjunctivochalasis: historical perspective. *Ocul Surf* 2005;3:7–14.
- [449] Pult H, Riede-Pult BH. Impact of conjunctival folds on central tear meniscus height. *Invest Ophthalmol Vis Sci* 2015;56:1459–66.
- [450] Norn M. Meibomian orifices and Marx's line. Studied by triple vital staining. *Acta Ophthalmol (Copenh)* 1985;63:698–700.
- [451] Bron AJ, Yokoi N, Gaffney EA, Tiffany JM. A solute gradient in the tear meniscus. II. Implications for lid margin disease, including meibomian gland dysfunction. *Ocul Surf* 2011;9:92–7.
- [452] Korb DR, Blackie CA. Debridement-scaling: a new procedure that increases Meibomian gland function and reduces dry eye symptoms. *Cornea* 2013;32:1554–7.
- [453] Li S, Gallup M, Chen YT, McNamara NA. Molecular mechanism of proinflammatory cytokine-mediated squamous metaplasia in human corneal epithelial cells. *Invest Ophthalmol Vis Sci* 2010;51:2466–75.
- [454] Yamaguchi M, Kutsuna M, Uno T, Zheng X, Kodama T, Ohashi Y. Marx line: fluorescein staining line on the inner lid as indicator of meibomian gland function. *Am J Ophthalmol* 2006;141:669–75.
- [455] Rottach KG, Das VE, Wohlgemuth W, Zivotofsky AZ, Leigh RJ. Properties of horizontal saccades accompanied by blinks. *J Neurophysiol* 1998;79:2895–902.
- [456] de Paiva CS, Chotikavanich S, Pangelinan SB, Pitcher III JD, Fang B, Zheng X, et al. IL-17 disrupts corneal barrier following desiccating stress. *Mucosal Immunol* 2009;2:243–53.
- [457] Streilein JW. Ocular immune privilege: the eye takes a dim but practical view of immunity and inflammation. *J Leukoc Biol* 2003;74:179–85.
- [458] Lam H, Bleiden L, de Paiva CS, Farley W, Stern ME, Pflugfelder SC. Tear cytokine profiles in dysfunctional tear syndrome. *Am J Ophthalmol* 2009;147:198–205. e191.
- [459] Jensen OL, Gluud BS, Birgens HS. The concentration of lactoferrin in tears of normals and of diabetics. *Acta Ophthalmol(Copenh)* 1986;64:83–7.
- [460] Vinding T, Eriksen JS, Nielsen NV. The concentration of lysozyme and secretory IgA in tears from healthy persons with and without contact lens use. *Acta Ophthalmol(Copenh)* 1987;65:23–6.
- [461] Zhou L, Huang LQ, Beuerman RW, Grigg ME, Li SF, Chew FT, et al. Proteomic analysis of human tears: defensin expression after ocular surface surgery. *J Proteom Res* 2004;3:410–6.
- [462] Ueta M. Innate immunity of the ocular surface and ocular surface inflammatory disorders. *Cornea* 2008;27(Suppl 1):S31–40.
- [463] Simmons KT, Xiao Y, Pflugfelder SC, de Paiva CS. Inflammatory Response to Lipopolysaccharide on the Ocular Surface in a Murine Dry Eye Model. *Invest Ophthalmol Vis Sci* 2016;57:2443–51.
- [464] Springer TA. Adhesion receptors of the immune system. *Nature* 1990;346:425–34.
- [465] Narayanan S, Corrales RM, Farley W, McDermott AM, Pflugfelder SC. Interleukin-1 receptor-1-deficient mice show attenuated production of ocular surface inflammatory cytokines in experimental dry eye. *Cornea* 2008;27:811–7.
- [466] Yoon KC, Jeong IY, Park YG, Yang SY. Interleukin-6 and tumor necrosis factor- $\alpha$  levels in tears of patients with dry eye syndrome. *Cornea* 2007;26:431–7.
- [467] Yoon KC, Park CS, You IC, Choi HJ, Lee KH, Im SK, et al. Expression of CXCL9, -10, -11, and CXCR3 in the tear film and ocular surface of patients with dry eye syndrome. *Invest Ophthalmol Vis Sci* 2010;51:643–50.
- [468] Choi W, Li Z, Oh HJ, Im SK, Lee SH, Park SH, et al. Expression of CCR5 and its ligands CCL3, -4, and -5 in the tear film and ocular surface of patients with dry eye disease. *Curr Eye Res* 2012;37:12–7.
- [469] Carreno E, Enriquez-de-Salamanca A, Teson M, Garcia-Vazquez C, Stern ME, Whitcup SM, et al. Cytokine and chemokine levels in tears from healthy subjects. *Acta Ophthalmol* 2010;88:e250–258.
- [470] Zlotnick A, Mitchell RS, Brenner SL. recA protein filaments bind two molecules of single-stranded DNA with off rates regulated by nucleotide cofactor. *J Biol Chem* 1990;265:17050–4.
- [471] Pisella PJ, Brignole F, Debbasch C, Lozato PA, Creuzot-Garcher C, Bara J, et al. Flow cytometric analysis of conjunctival epithelium in ocular rosacea and keratoconjunctivitis sicca. *Ophthalmology* 2000;107:1841–9.
- [472] Perez VL, Pflugfelder SC, Zhang S, Shojaei A, Haque R. Lifitegrast, a novel integrin antagonist for treatment of dry eye disease. *Ocul Surf* 2016;14:207–15.
- [473] <https://www.fda.gov/NewsEvents/Newsroom/PressAnnouncements/ucm510720.htm>.
- [474] Gao Y, Min K, Zhang Y, Su J, Greenwood M, Gronert K. Female-specific downregulation of tissue polymorphonuclear neutrophils drives impaired regulatory T cell and amplified effector T cell responses in autoimmune dry eye disease. *J Immunol* 2015;195:3086–99.
- [475] Coursey TG, Bohat R, Barbosa FL, Pflugfelder SC, de Paiva CS. Desiccating stress-induced chemokine expression in the epithelium is dependent on upregulation of NKG2D/RAE-1 and release of IFN- $\gamma$  in experimental dry eye. *J Immunol* 2014;193:5264–72.
- [476] Zhang X, Volpe EA, Gandhi NB, Schaumburg CS, Siemasko KF, Pangelinan SB, et al. NK cells promote Th-17 mediated corneal barrier disruption in dry eye. *PLoS One* 2012;7. e36822.
- [477] Chen Q, Zhang X, Cui L, Huang Q, Chen W, Ma H, et al. Upper and lower tear menisci in Sjogren's syndrome dry eye. *Invest Ophthalmol Vis Sci* 2011;52:9373–8.
- [478] De Paiva CS, Villarreal AL, Corrales RM, Rahman HT, Chang VY, Farley WJ, et al. Dry eye-induced conjunctival epithelial squamous metaplasia is modulated by interferon- $\gamma$ . *Invest Ophthalmol Vis Sci* 2007;48:2553–60.
- [479] Schaumburg CS, Siemasko KF, De Paiva CS, Wheeler LA, Niederhorn JY, Pflugfelder SC, et al. Ocular surface APCs are necessary for autoreactive T cell-mediated experimental autoimmune lacrimal keratoconjunctivitis. *J Immunol* 2011;187:3653–62.
- [480] You IC, Coursey TG, Bian F, Barbosa FL, de Paiva CS, Pflugfelder SC. Macrophage phenotype in the ocular surface of experimental murine dry eye disease. *Arch Immunol Ther Exp Warsz* 2015;63:299–304.
- [481] Bialasiewicz AA, Schaudig U, Ma JX, Vieth S, Richard G. Alpha/beta- and gamma/delta-T-cell-receptor-positive lymphocytes in healthy and inflamed human conjunctiva. *Graefes Arch Clin Exp Ophthalmol* 1996;234:467–71.
- [482] Stern ME, Schaumburg CS, Siemasko KF, Gao J, Wheeler LA, Grupe DA, et al. Autoantibodies contribute to the immunopathogenesis of experimental dry eye disease. *Invest Ophthalmol Vis Sci* 2012;53:2062–75.
- [483] Kunert KS, Tisdale AS, Stern ME, Smith JA, Gipson IK. Analysis of topical cyclosporine treatment of patients with dry eye syndrome: effect on conjunctival lymphocytes. *Arch Ophthalmol* 2000;118:1489–96.
- [484] Bacman S, Berra A, Sterin-Borda L, Borda E. Muscarinic acetylcholine receptor antibodies as a new marker of dry eye Sjögren's syndrome. *Invest Ophthalmol Vis Sci* 2001;42:321–7.
- [485] Takada K, Takiguchi M, Konno A, Inaba M. Autoimmunity against a tissue kallikrein in IQI/jic Mice: a model for Sjogren's syndrome. *J Biol Chem* 2005;280:3982–8.
- [486] Jiang G, Ke Y, Sun D, Li H, Ihnen M, Jumbblatt MM, et al. A new model of experimental autoimmune keratoconjunctivitis sicca (KCS) induced in Lewis rat by the autoantigen Klk1b22. *Invest Ophthalmol Vis Sci* 2009;50:2245–54.
- [487] Niederhorn JY, Stern ME, Pflugfelder SC, De Paiva CS, Corrales RM, Gao J, et al. Desiccating stress induces T cell-mediated Sjogren's Syndrome-like lacrimal keratoconjunctivitis. *J Immunol* 2006;176:3950–7.
- [488] Stern ME, Gao J, Schwab TA, Ngo M, Tieu DD, Chan CC, et al. Conjunctival T-cell subpopulations in Sjogren's and non-Sjogren's patients with dry eye. *Invest Ophthalmol Vis Sci* 2002;43:2609–14.
- [489] Herretes S, Ross DB, Duffort S, Barreras H, Tan Y, Murillo JC, et al. Recruitment of Donor T Cells to the Eyes during Ocular GVHD in Recipients of MHC-Matched Allogeneic Hematopoietic Stem Cell Transplants. *Invest Ophthalmol Vis Sci* 2015, 2348–2357.
- [490] Siebelmann S, Gehlsen U, Huttmann G, Koop N, Bolke T, Gebert A, et al. Development, alteration and real time dynamics of conjunctiva-associated lymphoid tissue. *PLoS One* 2013;8. e82355.
- [491] Knop E, Knop N. Influence of the eye-associated lymphoid tissue (EALT) on inflammatory ocular surface disease. *Ocul Surf* 2005;3:S180–6.
- [492] Steven P, Rupp J, Huttmann G, Koop N, Lensing C, Laqua H, et al. Experimental induction and three-dimensional two-photon imaging of conjunctiva-associated lymphoid tissue. *Invest Ophthalmol Vis Sci* 2008;49:1512–7.
- [493] Steven P, Gebert A. Conjunctiva-associated lymphoid tissue - current knowledge, animal models and experimental prospects. *Ophthalmic Res* 2009;42:2–8.
- [494] Gutgesell VJ, Stern GA, Hood CI. Histopathology of meibomian gland dysfunction. *Am J Ophthalmol* 1982;94:383–7.
- [495] Obata H, Horiuchi H, Miyata K, Tsuru T, Machinami R. Histopathological study of the meibomian glands in 72 autopsy cases. *Nippon Ganka Gakkai Zasshi* 1994;98:765–71.
- [496] Sahin A, Kam WR, Rahimi Darabad R, Liu Y, Sullivan DA. Influence of lipopolysaccharide on proinflammatory gene expression in human corneal, conjunctival and meibomian gland epithelial cells. *Invest Ophthalmol Vis Sci* 2017. ARVO abstract #3946.
- [497] Meyaard L. The inhibitory collagen receptor LAIR-1 (CD305). *J Leukoc Biol* 2008;83:799–803.
- [498] Omiya R, Tsushima F, Narazaki H, Sakoda Y, Kuramasu A, Kim Y, et al. Leucocyte-associated immunoglobulin-like receptor-1 is an inhibitory regulator of contact hypersensitivity. *Immunology* 2009;128:543–55.
- [499] Qu XD, Lehrer RI. Secretory phospholipase A2 is the principal bactericide for staphylococci and other gram-positive bacteria in human tears. *Infect Immun* 1998;66:2791–7.
- [500] Hieshima K, Ohtani H, Shibano M, Izawa D, Nakayama T, Kawasaki Y, et al. CCL28 has dual roles in mucosal immunity as a chemokine with broad-spectrum antimicrobial activity. *J Immunol* 2003;170:1452–61.
- [501] Davis RSK, Sullivan DA, Liu Y. Inhibitory effect of human meibomian gland epithelial cells on the growth rate of *Pseudomonas aeruginosa*. (abstract).

- Invest Ophthalmol Vis Sci 2016. ARVO Abstract #5705.
- [502] Perera C, McNeil HP, Geczy CL. S100 Calgranulins in inflammatory arthritis. *Immunol Cell Biol* 2010;88:41–9.
- [503] Hsu K, Champaiboon C, Guenther BD, Sorenson BS, Khammanivong A, Ross KF, et al. Anti-infective protective properties of S100 calgranulins. *Antiinflamm Antiallergy Agents Med Chem* 2009;8:290–305.
- [504] Champaiboon C, Sappington KJ, Guenther BD, Ross KF, Herzberg MC. Calprotectin S100A9 calcium-binding loops I and II are essential for keratinocyte resistance to bacterial invasion. *J Biol Chem* 2009;284:7078–90.
- [505] Liu S, Richards SM, Lo K, Hatton M, Fay A, Sullivan DA. Changes in gene expression in human meibomian gland dysfunction. *Invest Ophthalmol Vis Sci* 2011;52:2727–40.
- [506] Nelson JD, Shimazaki J, Benitez-del-Castillo JM, et al. The international workshop on meibomian gland dysfunction: report of the definition and classification subcommittee. *Invest Ophthalmol Vis Sci* 2011;52:1930–7.
- [507] Schrader S, Mircheff AK, Geerling G. Animal models of dry eye. In: Geerling G, Brewitt H, editors. *Surgery for the Dry eye*. Freiburg: Karger; 2008. p. 298–312.
- [508] Dursun D, Wang M, Monroy D, Li DQ, Lokeshwar BL, Stern ME, et al. A mouse model of keratoconjunctivitis sicca. *Invest Ophthalmol Vis Sci* 2002;43:632–8.
- [509] Barabino S, Shen L, Chen L, Rashid S, Rolando M, Dana MR. The controlled-environment chamber: a new mouse model of dry eye. *Invest Ophthalmol Vis Sci* 2005;46:2766–71.
- [510] Chen W, Zhang X, Zhang J, Chen J, Wang S, Wang Q, et al. A murine model of dry eye induced by an intelligently controlled environmental system. *Invest Ophthalmol Vis Sci* 2008;49:1386–91.
- [511] Lee HS, Chauhan SK, Okanobo A, Nallasamy N, Dana R. Therapeutic efficacy of topical epigallocatechin gallate in murine dry eye. *Cornea* 2011;30:1465–72.
- [512] Goyal S, Chauhan SK, Dana R. Blockade of prolymphangiogenic vascular endothelial growth factor C in dry eye disease. *Arch Ophthalmol* 2012;130:84–9.
- [513] Sadrai Z, Stevenson W, Okanobo A, Chen Y, Dohlman TH, Hua J, et al. PDE4 inhibition suppresses IL-17-associated immunity in dry eye disease. *Invest Ophthalmol Vis Sci* 2012;53:3584–91.
- [514] de Paiva CS, Schwartz CE, Gjorstrup P, Pflugfelder SC. Resolvin E1 (RX-10001) reduces corneal epithelial barrier disruption and protects against goblet cell loss in a murine model of dry eye. *Cornea* 2012;31:1299–303.
- [515] Krauss AH, Corrales RM, Pelegrino FS, Tukler-Henriksson J, Pflugfelder SC, de Paiva CS. Improvement of Outcome Measures of Dry Eye by a Novel Integrin Antagonist in the Murine Desiccating Stress Model. *Invest Ophthalmol Vis Sci* 2015;56:5888–95.
- [516] De Paiva CS, Yoon KC, Pangelinan SB, Pham S, Puthenparambil LM, Chuang EY, et al. Cleavage of functional IL-2 receptor alpha chain (CD25) from murine corneal and conjunctival epithelia by MMP-9. *J Inflamm (Lond)* 2009;6:31.
- [517] Corrales RM, Stern ME, De Paiva CS, Welch J, Li DQ, Pflugfelder SC. Desiccating stress stimulates expression of matrix metalloproteinases by the corneal epithelium. *Invest Ophthalmol Vis Sci* 2006;47:3293–302.
- [518] Coursey TG, Tukler Henriksson J, Chen M, de Paiva CS, Pflugfelder SC. IFN- $\gamma$  induced unfolded Protein Response in Conjunctival Goblet Cells as Cause of Mucin Deficiency in Sjögren's Syndrome. *Am J Pathol* 2016;186:1547–58.
- [519] Pflugfelder SC, Farley W, Luo L, Chen LZ, de Paiva CS, Olmos LC, et al. Matrix metalloproteinase-9 knockout confers resistance to corneal epithelial barrier disruption in experimental dry eye. *Am J Pathol* 2005;166:61–71.
- [520] de Paiva CS, Pangelinan SB, Chang E, Yoon KC, Farley WJ, Li DQ, et al. Essential role for c-Jun N-terminal kinase 2 in corneal epithelial response to desiccating stress. *Arch Ophthalmol* 2009;127:1625–31.
- [521] Stevenson W, Chauhan SK, Dana R. Dry eye disease: an immune-mediated ocular surface disorder. *Arch Ophthalmol* 2012;130:90–100.
- [522] Chen Y, Chauhan SK, Saban DR, Sadrai Z, Okanobo A, Dana R. Interferon-gamma-secreting NK cells promote induction of dry eye disease. *J Leukoc Biol* 2011;89:965–72.
- [523] Chauhan SK, Jin Y, Goyal S, Lee HS, Fuchsluger TA, Lee HK, et al. A novel prolymphangiogenic function for Th17/IL-17. *Blood* 2011;118:4630–4.
- [524] Goyal S, Chauhan SK, El Annan J, Nallasamy N, Zhang Q, Dana R. Evidence of corneal lymphangiogenesis in dry eye disease: a potential link to adaptive immunity? *Arch Ophthalmol* 2010;128:819–24.
- [525] El Annan J, Chauhan SK, Ecoiffier T, Zhang Q, Saban DR, Dana R. Characterization of effector T cells in dry eye disease. *Invest Ophthalmol Vis Sci* 2009;50:3802–7.
- [526] Chauhan SK, Dana R. Role of Th17 cells in the immunopathogenesis of dry eye disease. *Mucosal Immunol* 2009;2:375–6.
- [527] Coursey TG, Gandhi NB, Volpe EA, Pflugfelder SC, de Paiva CS. Chemokine receptors CCR6 and CXCR3 are necessary for CD4(+) T cell mediated ocular surface disease in experimental dry eye disease. *PLoS One* 2013;8. e78508.
- [528] Dohlman TH, Chauhan SK, Kodati S, Hua J, Chen Y, Omoto M, et al. The CCR6/CCL20 axis mediates Th17 cell migration to the ocular surface in dry eye disease. *Invest Ophthalmol Vis Sci* 2013;54:4081–91.
- [529] Chauhan SK, El Aj, Ecoiffier T, Goyal S, Zhang Q, Saban DR, et al. Autoimmunity in dry eye is due to resistance of Th17 to Treg suppression. *J Immunol* 2009;182:1247–52.
- [530] Zhang X, Chen W, De Paiva CS, Corrales RM, Volpe EA, McClellan AJ, et al. Interferon-gamma exacerbates dry eye-induced apoptosis in conjunctiva through dual apoptotic pathways. *Invest Ophthalmol Vis Sci* 2011;52:6279–85.
- [531] Yoon KC, De Paiva CS, Qi H, Chen Z, Farley WJ, Li DQ, et al. Expression of Th-1 chemokines and chemokine receptors on the ocular surface of C57BL/6 mice: effects of desiccating stress. *Invest Ophthalmol Vis Sci* 2007;48:2561–9.
- [532] Pflugfelder SC, De Paiva CS, Moore QL, Volpe EA, Li DQ, Gumus K, et al. Aqueous tear deficiency increases conjunctival interferon-gamma (IFN-gamma) expression and goblet cell loss. *Invest Ophthalmol Vis Sci* 2015;56:7545–50.
- [533] Niederkorn JY, Stevens C, Mellon J, Mayhew E. CD4+ T-cell-independent rejection of corneal allografts. *Transplantation* 2006;81:1171–8.
- [534] Rodriguez-Pinto D, Moreno J. B cells can prime naive CD4+ T cells in vivo in the absence of other professional antigen-presenting cells in a CD154-CD40-dependent manner. *Eur J Immunol* 2005;35:1097–105.
- [535] Dursun D, Wang M, Monroy D, Li DQ, Lokeshwar BL, Stern M, et al. Experimentally induced dry eye produces ocular surface inflammation and epithelial disease. *Adv Exp Med Biol* 2002;506:647–55.
- [536] Pelegrino FS, Volpe EA, Gandhi NB, Li DQ, Pflugfelder SC, de Paiva CS. Deletion of interferon-gamma delays onset and severity of dacryoadenitis in CD25KO mice. *Arthritis Res Ther* 2012;14. R234.
- [537] Chen Y, Chauhan SK, Lee HS, Stevenson W, Schaumburg CS, Sadrai Z, et al. Effect of desiccating environmental stress versus systemic muscarinic AChR blockade on dry eye immunopathogenesis. *Invest Ophthalmol Vis Sci* 2013;54:2457–64.
- [538] Gallowitsch-Puerta M, Pavlov VA. Neuro-immune interactions via the cholinergic anti-inflammatory pathway. *Life Sci* 2007;80:2325–9.
- [539] Mitchellson F. Muscarinic receptor agonists and antagonists: effects on ocular function. *Handb Exp Pharmacol* 2012;263–98.
- [540] Toshida H, Beuerman RW. Effects of preganglionic parasympathetic denervation on the rabbit lacrimation. *Adv Exp Med Biol* 2002;506(Pt A):225–9.
- [541] Chen Y, Zhang X, Yang L, Li M, Li B, Wang W, et al. Decreased PPAR-gamma expression in the conjunctiva and increased expression of TNF-alpha and IL-1beta in the conjunctiva and tear fluid of dry eye mice. *Mol Med Rep* 2014;9:2015–23.
- [542] Chen Y, Chauhan SK, Lee HS, Saban DR, Dana R. Chronic dry eye disease is principally mediated by effector memory Th17 cells. *Mucosal Immunol* 2014;7:38–45.
- [543] Choi W, Lian C, Ying L, Kim GE, You IC, Park SH, et al. Expression of Lipid Peroxidation Markers in the Tear Film and Ocular Surface of Patients with Non-Sjogren Syndrome: Potential Biomarkers for Dry Eye Disease. *Curr Eye Res* 2016;1–7.
- [544] Blackie CA, Korb DR. A novel lid seal evaluation: the Korb-Blackie light test. *Eye Contact Lens* 2015;41:98–100.
- [545] McClellan AJ, Volpe EA, Zhang X, Darlington GJ, Li DQ, Pflugfelder SC, et al. Ocular surface disease and dacryoadenitis in aging C57BL/6 mice. *Am J Pathol* 2014;184:631–43.
- [546] Seok J, Warren HS, Cuenca AG, Mindrinos MN, Baker HV, Xu W, et al. Genomic responses in mouse models poorly mimic human inflammatory diseases. *Proc Natl Acad Sci U S A* 2013;110:3507–12.
- [547] Shoda LK, Young DL, Ramanujan S, Whiting CC, Atkinson MA, Bluestone JA, et al. A comprehensive review of interventions in the NOD mouse and implications for translation. *Immunity* 2005;23:115–26.
- [548] Takao K, Miyakawa T. Genomic responses in mouse models greatly mimic human inflammatory diseases. *Proc Natl Acad Sci U S A* 2015;112:1167–72.
- [549] Chao W, Belmonte C, Benitez Del Castillo JM, Bron AJ, Dua HS, Nichols KK, et al. Report of the Inaugural Meeting of the TFOS  $\mathcal{I}^2$  = initiating innovation Series: Targeting the Unmet Need for Dry Eye Treatment. *Ocul Surf* 2016;14:264–316.
- [550] Sosne G, Kim C, Kleinman HK. Thymosin beta4 significantly reduces the signs of dryness in a murine controlled adverse environment model of experimental dry eye. *Expert Opin Biol Ther* 2015;15(Suppl 1):S155–61.
- [551] Lekhanont K, Park CY, Smith JA, Combs JC, Preechawat P, Suwan-Apichon O, et al. Effects of topical anti-inflammatory agents in a botulinum toxin B-induced mouse model of keratoconjunctivitis sicca. *J Ocul Pharmacol Ther* 2007 Feb;23(1):27–34.
- [552] Shay T, Lederer JA, Benoist C. Genomic responses to inflammation in mouse models mimic humans: we concur, apples to oranges comparisons won't do. *Proc Natl Acad Sci U S A* 2015;112. E346.
- [553] Ariga H, Edwards J, Sullivan DA. Androgen control of autoimmune expression in lacrimal glands of MRL/Mp-lpr/lpr mice. *Clin Immunol Immunopathol* 1989;53:499–508.
- [554] Vendramini AC, Soo C, Sullivan DA. Testosterone-induced suppression of autoimmune disease in lacrimal tissue of a mouse model (NZB/NZW F1) of Sjogren's syndrome. *Invest Ophthalmol Vis Sci* 1991;32:3002–6.
- [555] Toda I, Wickham LA, Sullivan DA. Gender and androgen treatment influence the expression of proto-oncogenes and apoptotic factors in lacrimal and salivary tissues of MRL/lpr mice. *Clin Immunol Immunopathol* 1998;86:59–71.
- [556] Toda I, Sullivan BD, Rocha EM, Da Silveira LA, Wickham LA, Sullivan DA. Impact of gender on exocrine gland inflammation in mouse models of Sjogren's syndrome. *Exp Eye Res* 1999;69:355–66.
- [557] Schaumburg DA, Dana R, Buring JE, Sullivan DA. Prevalence of dry eye

- disease among US men: estimates from the Physicians' Health Studies. *Arch Ophthalmol* 2009;127:763–8.
- [558] Galor A, Feuer W, Lee DJ, Florez H, Carter D, Pouyeh B, et al. Prevalence and risk factors of dry eye syndrome in a United States veterans affairs population. *Am J Ophthalmol* 2011;152:377 e2–84 e2.
- [559] Guillon M, Maissa C. Tear film evaporation—effect of age and gender. *Cont Lens Anterior Eye* 2010;33:171–5.
- [560] Guo B, Lu P, Chen X, Zhang W, Chen R. Prevalence of dry eye disease in Mongolians at high altitude in China: the Henan eye study. *Ophthalmic Epidemiol* 2010;17:234–41.
- [561] Gupta N, Prasad I, Jain R, D'Souza P. Estimating the prevalence of dry eye among Indian patients attending a tertiary ophthalmology clinic. *Ann Trop Med Parasitol* 2010;104:247–55.
- [562] Bian F, Barbosa FL, Corrales RM, Pelegrino FS, Volpe EA, Pflugfelder SC, et al. Altered balance of interleukin-13/interferon-gamma contributes to lacrimal gland destruction and secretory dysfunction in CD25 knockout model of Sjogren's syndrome. *Arthritis Res Ther* 2015;17:53.
- [563] Turpie B, Yoshimura T, Gulati A, Rios JD, Dartt DA, Masli S. Sjogren's syndrome-like ocular surface disease in thrombospondin-1 deficient mice. *Am J Pathol* 2009;175:1136–47.
- [564] Coursey TG, Bian F, Pflugfelder SC, De Paiva CS. Spontaneous lacrimal keratoconjunctivitis in aged NOD.B10.H2b mice is accompanied by dysfunctional T regulatory cells. *Invest Ophthalmol Vis Sci* 2015;56:334.
- [565] Shiboski SC, Shiboski CH, Criswell L, Baer A, Challacombe S, Lanfranchi H, et al. American College of Rheumatology classification criteria for Sjogren's syndrome: a data-driven, expert consensus approach in the Sjogren's International Collaborative Clinical Alliance cohort. *Arthritis Care Res Hob* 2012;64:475–87.
- [566] Schamberg DA, Sullivan DA, Buring JE, Dana MR. Prevalence of dry eye syndrome among US women. *Am J Ophthalmol* 2003;136:318–26.
- [567] Uchino M, Dogru M, Uchino Y, Fukagawa K, Shimmura S, Takebayashi T, et al. Japan Ministry of Health study on prevalence of dry eye disease among Japanese high school students. *Am J Ophthalmol* 2008;146:925 e2–9 e2.
- [568] Hunger RE, Carnaud C, Vogt I, Mueller C. Male gonadal environment paradoxically promotes dacryoadenitis in nonobese diabetic mice. *J Clin Invest* 1998;101:1300–9.
- [569] Toda I, Sullivan BD, Wickham LA, Sullivan DA. Gender- and androgen-related influence on the expression of proto-oncogene and apoptotic factor mRNAs in lacrimal glands of autoimmune and non-autoimmune mice. *J Steroid Biochem Mol Biol* 1999;71:49–61.
- [570] Darabad RR, Richards SM, Sullivan DA. Sex and androgen effects on gene expression in autoimmune lacrimal glands. *Invest Ophthalmol Vis Sci* 2010. ARVO abstract #4177.
- [571] Brito-Zeron P, Theander E, Baldini C, Seror R, Retamozo S, Quartuccio L, et al. Early diagnosis of primary Sjogren's syndrome: EULAR-SS task force clinical recommendations. *Expert Rev Clin Immunol* 2016;12:137–56.
- [572] Jabbs DA, Lee B, Whittum-Hudson JA, Prendergast RA. Th1 versus Th2 immune responses in autoimmune lacrimal gland disease in MRL/Mp mice. *Invest Ophthalmol Vis Sci* 2000;41:826–31.
- [573] Van Bloklant SC, Versnel MA. Pathogenesis of Sjogren's syndrome: characteristics of different mouse models for autoimmune exocrinopathy. *Clin Immunol* 2002;103:111–24.
- [574] Jabbs DA, Prendergast RA. Autoimmune ocular disease in MRL/Mp-lpr/lpr mice is suppressed by anti-CD4 antibody. *Invest Ophthalmol Vis Sci* 1991;32:2718–22.
- [575] Jie G, Jiang Q, Rui Z, Yifei Y. Expression of interleukin-17 in autoimmune dacryoadenitis in MRL/lpr mice. *Curr Eye Res* 2010;35:865–71.
- [576] Diebold Y, Chen LL, Tepavcevic V, Ferdman D, Hodges RR, Dartt DA. Lymphocytic infiltration and goblet cell marker alteration in the conjunctiva of the MRL/MpJ-Fas(lpr) mouse model of Sjogren's syndrome. *Exp Eye Res* 2007;84:500–12.
- [577] Sun B, Rizzo LV, Sun SH, Chan CC, Wiggert B, Wilder RL, et al. Genetic susceptibility to experimental autoimmune uveitis involves more than a predisposition to generate a T helper-1-like or a T helper-2-like response. *J Immunol* 1997;159:1004–11.
- [578] Rios JD, Horikawa Y, Chen LL, Kublin CL, Hodges RR, Dartt DA, et al. Age-dependent alterations in mouse exorbital lacrimal gland structure, innervation and secretory response. *Exp Eye Res* 2005;80:477–91.
- [579] de Paiva CS, Rocha EM. Sjogren syndrome: what and where are we looking for? *Curr Opin Ophthalmol* 2015;26:517–25.
- [580] Zhou D, Chen YT, Chen F, Gallup M, Vijmasi T, Bahrami AF, et al. Critical involvement of macrophage infiltration in the development of Sjogren's syndrome-associated dry eye. *Am J Pathol* 2012;181:753–60.
- [581] de Paiva CS, Hwang CS, Pitcher III JD, Pangelinan SB, Rahimy E, Chen W, et al. Age-related T-cell cytokine profile parallels corneal disease severity in Sjogren's syndrome-like keratoconjunctivitis sicca in CD25KO mice. *Rheumatology* 2010;49:246–58.
- [582] Rahimy E, Pitcher 3rd JD, Pangelinan SB, Chen W, Farley WJ, Niederkorn JY, et al. Spontaneous autoimmune dacryoadenitis in aged CD25KO mice. *Am J Pathol* 2010;177:744–53.
- [583] Chistiakov DA, Voronova NV, Chistiakov PA. The crucial role of IL-2/IL-2RA-mediated immune regulation in the pathogenesis of type 1 diabetes, an evidence coming from genetic and animal model studies. *Immunol Lett* 2008;118:1–5.
- [584] Willerford DM, Ferry JA, Davidson L, Ma A, Alt FW. Interleukin-2 receptor alpha chain regulates the size and content of the peripheral lymphoid compartment. *Immunity* 1995;3:521–30.
- [585] Waldmann TA. The biology of interleukin-2 and interleukin-15: implications for cancer therapy and vaccine design. *Nat Rev Immunol* 2006;6:595–601.
- [586] Sharma R, Bagavant H, Jarjour WN, Sung SS, Ju ST. The role of Fas in the immune system biology of IL-2R alpha knockout mice: interplay among regulatory T cells, inflammation, hemopoiesis, and apoptosis. *J Immunol* 2005;175:1965–73.
- [587] Refaeli Y, Van PL, London CA, Tschopp J, Abbas AK. Biochemical mechanisms of IL-2-regulated Fas-mediated T cell apoptosis. *Immunity* 1998;8:615–23.
- [588] Vijmasi T, Chen FY, Chen YT, Gallup M, McNamara N. Topical administration of interleukin-1 receptor antagonist as a therapy for aqueous-deficient dry eye in autoimmune disease. *Mol Vis* 2013;19:1957–65.
- [589] Chen YT, Nikulina K, Lazarev S, Bahrami AF, Noble LB, Gallup M, et al. Interleukin-1 as a phenotypic immunomodulator in keratinizing squamous metaplasia of the ocular surface in Sjogren's syndrome. *Am J Pathol* 2010;177:1333–43.
- [590] Yeh S, de Paiva CS, Hwang CS, Trinca K, Lingappan A, Rafati JK, et al. Spontaneous T cell mediated keratoconjunctivitis in Aire-deficient mice. *Br J Ophthalmol* 2009;93:1260–4.
- [591] Nguyen CQ, Yin H, Lee BH, Chiorini JA, Peck AB. IL17: potential therapeutic target in Sjogren's syndrome using adenovirus-mediated gene transfer. *Lab Invest* 2011;91:54–62.
- [592] Caspi RR, Chan CC, Grubbs BG, Silver PB, Wiggert B, Parsa CF, et al. Endogenous systemic IFN-gamma has a protective role against ocular autoimmunity in mice. *J Immunol* 1994;152:890–9.
- [593] Cha S, Brayer J, Gao J, Brown V, Killedar S, Yasunari U, et al. A dual role for interferon-gamma in the pathogenesis of Sjogren's syndrome-like autoimmune exocrinopathy in the nonobese diabetic mouse. *Scand J Immunol* 2004;60:552–65.
- [594] Wan YY, Flavell RA. Regulatory T cells, transforming growth factor-beta, and immune suppression. *Proc Am Thorac Soc* 2007;4:271–6.
- [595] Bettelli E, Carrier Y, Gao W, Korn T, Strom TB, Oukka M, et al. Reciprocal developmental pathways for the generation of pathogenic effector TH17 and regulatory T cells. *Nature* 2006;441:235–8.
- [596] McCartney-Francis NL, Mizel DE, Frazier-Jessen M, Kulkarni AB, McCarthy JB, Wahl SM. Lacrimal gland inflammation is responsible for ocular pathology in TGF-beta 1 null mice. *Am J Pathol* 1997;151:1281–8.
- [597] McCartney-Francis NL, Mizel DE, Redman RS, Frazier-Jessen M, Panek RB, Kulkarni AB, et al. Autoimmune Sjogren's-like lesions in salivary glands of TGF-beta1-deficient mice are inhibited by adhesion-blocking peptides. *J Immunol* 1996;157:1306–12.
- [598] Shull MM, Doetschman T. Transforming growth factor- $\alpha$ 1 in reproduction and development. *Mol Reprod Dev* 1994;39:239–46.
- [599] Contreras-Ruiz L, Regenfuss B, Mir FA, Kearns J, Masli S. Conjunctival Inflammation in Thrombospondin-1 Deficient Mouse Model of Sjogren's Syndrome. *PLoS One* 2013;8. e75937.
- [600] Gandhi NB, Su Z, Zhang X, Volpe EA, Pelegrino FS, Rahman SA, et al. Dendritic cell-derived thrombospondin-1 is critical for the generation of the ocular surface Th17 response to desiccating stress. *J Leukoc Biol* 2013;94:1293–301.
- [601] Contreras-Ruiz L, Ryan DS, Sia RK, Bower KS, Dartt DA, Masli S. Polymorphism in THBS1 gene is associated with post-refractive surgery chronic ocular surface inflammation. *Ophthalmology* 2014;121:1389–97.
- [602] Okuma A, Hoshino K, Ohba T, Fukushima S, Aiba S, Akira S, et al. Enhanced apoptosis by disruption of the STAT3-IkappaB-zeta signaling pathway in epithelial cells induces Sjogren's syndrome-like autoimmune disease. *Immunity* 2013;38:450–60.
- [603] Wu AJ, Chen ZJ, Tsokos M, O'Connell BC, Ambudkar IS, Baum BJ. Interferon-gamma induced cell death in a cultured human salivary gland cell line. *J Cell Physiol* 1996;167:297–304.
- [604] Kamachi M, Kawakami A, Yamasaki S, Hida A, Nakashima T, Nakamura H, et al. Regulation of apoptotic cell death by cytokines in a human salivary gland cell line: distinct and synergistic mechanisms in apoptosis induced by tumor necrosis factor alpha and interferon gamma. *J Lab Clin Med* 2002;139:13–9.
- [605] Coursey TG, Tukler Henriksson J, Barbosa FL, de Paiva CS, Pflugfelder SC. Interferon-gamma-Induced Unfolded Protein Response in Conjunctival Goblet Cells as a Cause of Mucin Deficiency in Sjogren Syndrome. *Am J Pathol* 2016;186:1547–58.
- [606] Garcia-Posadas L, Hodges RR, Li D, Shatos MA, Storr-Paulsen T, Diebold Y, et al. Interaction of IFN-gamma with cholinergic agonists to modulate rat and human goblet cell function. *Mucosal Immunol* 2016;9:206–17.
- [607] Zulman J, Jaffe R, Talal N. Evidence that the malignant lymphoma of Sjogren's syndrome is a monoclonal B-cell neoplasm. *N Engl J Med* 1978;299:1215–20.
- [608] Voulgarelis M, Ziakas PD, Papageorgiou A, Baimpa E, Tzioufas AG, Moutsopoulos HM. Prognosis and outcome of non-Hodgkin lymphoma in primary Sjogren syndrome. *Med Baltim* 2012;91:1–9.
- [609] Kassin SS, Thomas TL, Moutsopoulos HM, Hoover R, Kimberly RP, Budman DR, et al. Increased risk of lymphoma in sicca syndrome. *Ann Intern*

- Med 1978;89:888–92.
- [610] Whitcher JP, Shiboski CH, Shiboski SC, Heidenreich AM, Kitagawa K, Zhang S, et al. A simplified quantitative method for assessing keratoconjunctivitis sicca from the Sjogren's Syndrome International Registry. *Am J Ophthalmol* 2010;149:405–15.
- [611] Groom J, Kalled SL, Cutler AH, Olson C, Woodcock SA, Schneider P, et al. Association of BAFF/BlyS overexpression and altered B cell differentiation with Sjogren's syndrome. *J Clin Invest* 2002;109:59–68.
- [612] Qian Y, Giltiay N, Xiao J, Wang Y, Tian J, Han S, et al. Deficiency of Act1, a critical modulator of B cell function, leads to development of Sjogren's syndrome. *Eur J Immunol* 2008;38:2219–28.
- [613] Brayer JB, Cha S, Nagashima H, Yasunari U, Lindberg A, Diggs S, et al. IL-4-dependent effector phase in autoimmune exocrinopathy as defined by the NOD.IL-4-gene knockout mouse model of Sjogren's syndrome. *Scand J Immunol* 2001;54:133–40.
- [614] Nguyen CQ, Gao JH, Kim H, Saban DR, Cornelius JC, Peck AB. IL-4-STAT6 signal transduction-dependent induction of the clinical phase of Sjogren's syndrome-like disease of the nonobese diabetic mouse. *J Immunol* 2007;179:382–90.
- [615] Iizuka M, Wakamatsu E, Tsuboi H, Nakamura Y, Hayashi T, Matsui M, et al. Pathogenic role of immune response to M3 muscarinic acetylcholine receptor in Sjogren's syndrome-like sialadenitis. *J Autoimmun* 2010;35:383–9.
- [616] Iizuka M, Tsuboi H, Matsuo N, Kondo Y, Asashima H, Matsui M, et al. The crucial role of IFN-gamma in the development of M3 muscarinic acetylcholine receptor induced Sjogren's syndrome-like sialadenitis. *Mod Rheumatol* 2013;23:614–6.
- [617] Iizuka M, Tsuboi H, Asashima H, Hirota T, Kondo Y, Matsui M, et al. M3 muscarinic acetylcholine receptor reactive IL-17 producing T cells promotes development of Sjogren's syndrome like sialadenitis. *Mod Rheumatol* 2015;25:158–60.
- [618] Yoon KC, de Paiva CS, Qi H, Chen Z, Farley WJ, Li DQ, et al. Desiccating environmental stress exacerbates autoimmune lacrimal keratoconjunctivitis in non-obese diabetic mice. *J Autoimmun* 2008;30:212–21.
- [619] Yoon KC, Ahn KY, Choi W, Li Z, Choi JS, Lee SH, et al. Tear production and ocular surface changes in experimental dry eye after elimination of desiccating stress. *Investig Ophthalmol Vis Sci* 2011;52:7267–73.
- [620] Knop E, Knop N. Meibomian glands : part IV. Functional interactions in the pathogenesis of meibomian gland dysfunction (MGD). *Ophthalmologie* 2009;106:980–7.
- [621] Knop E, Knop N, Brewitt H, Pleyer U, Rieck P, Seitz B, et al. Meibomian glands : part III. Dysfunction - argument for a discrete disease entity and as an important cause of dry eye. *Ophthalmologie* 2009;106:966–79.
- [622] Krenzer KL, Dana MR, Ullman MD, Cermak JM, Tolls DB, Evans JE, et al. Effect of androgen deficiency on the human meibomian gland and ocular surface. *J Clin Endocrinol Metab* 2000;85:4874–82.
- [623] Cermak JM, Krenzer KL, Sullivan RM, Dana MR, Sullivan DA. Is complete androgen insensitivity syndrome associated with alterations in the meibomian gland and ocular surface? *Cornea* 2003;22:516–21.
- [624] Obata H. Anatomy and histopathology of human meibomian gland. *Cornea* 2002;21:S70–4.
- [625] Jester JV, Nicolaidis N, Smith RE. Meibomian gland studies: histologic and ultrastructural investigations. *Investig Ophthalmol Vis Sci* 1981;20:537–47.
- [626] Mathers WD, Lane JA. Meibomian gland lipids, evaporation, and tear film stability. *Adv Exp Med Biol* 1998;438:349–60.
- [627] Sullivan BD, Evans JE, Dana MR, Sullivan DA. Influence of aging on the polar and neutral lipid profiles in human meibomian gland secretions. *Arch Ophthalmol* 2006;124:1286–92.
- [628] Sullivan DA, Yamagami H, Liu M, Steagall RJ, Schirra F, Suzuki T, et al. Sex steroids, the meibomian gland and evaporative dry eye. *Adv Exp Med Biol* 2002;506:389–99.
- [629] Driver PJ, Lemp MA. Meibomian gland dysfunction. *Surv Ophthalmol* 1996;40:343–67.
- [630] Lemp MA. Report of the National Eye Institute/Industry workshop on Clinical Trials in Dry Eyes. *CLAO J* 1995;21:221–32.
- [631] Julio G, Merindano MD, Canals M, Caum C, Rallo M. Indicators of progressive corneal exposure to dry eye conditions. *Optom Vis Sci* 2012;89:1042–9.
- [632] Tseng SC. Staging of conjunctival squamous metaplasia by impression cytology. *Ophthalmology* 1985;92:728–33.
- [633] Ohnishi Y, Kohno T. Polychlorinated biphenyls poisoning in monkey eye. *Investig Ophthalmol Vis Sci* 1979;18:981–4.
- [634] Lambert R, Smith RE. Hyperkeratinization in a rabbit model of meibomian gland dysfunction. *Am J Ophthalmol* 1988;105:703–5.
- [635] Jester JV, Rife L, Nii D, Luttrull JK, Wilson L, Smith RE. In vivo biomicroscopy and photography of meibomian glands in a rabbit model of meibomian gland dysfunction. *Investig Ophthalmol Vis Sci* 1982;22:660–7.
- [636] Nicolaidis N, Santos EC, Smith RE, Jester JV. Meibomian gland dysfunction. III. Meibomian gland lipids. *Investig Ophthalmol Vis Sci* 1989;30:946–51.
- [637] Miyake H, Oda T, Katsuta O, Seno M, Nakamura M. Meibomian Gland Dysfunction Model in Hairless Mice Fed a Special Diet With Limited Lipid Content. *Investig Ophthalmol Vis Sci* 2016;57:3268–75.
- [638] Liu Y, Ding J. The combined effect of azithromycin and insulin-like growth factor-1 on cultured human meibomian gland epithelial cells. *Investig Ophthalmol Vis Sci* 2014;55:5596–601.
- [639] Liu Y, Kam WR, Ding J, Sullivan DA. Effect of azithromycin on lipid accumulation in immortalized human meibomian gland epithelial cells. *JAMA Ophthalmol* 2014;132:226–8.
- [640] Liu Y, Kam WR, Ding J, Sullivan DA. One man's poison is another man's meat: using azithromycin-induced phospholipidosis to promote ocular surface health. *Toxicology* 2014;320:1–5.
- [641] Lemp MA, Nichols KK. Blepharitis in the United States 2009: A Survey-based Perspective on Prevalence and Treatment. *Ocul Surf* 2009;7:S1–14.
- [642] Ibrahim MAA, Elwan WM. Role of topical dehydroepiandrosterone in ameliorating isotretinoin-induced Meibomian gland dysfunction in adult male albino rat. *Ann Anat* 2017;211:78–87.
- [643] Perry MD, McEvoy GK. Isotretinoin: new therapy for severe acne. *Clin Pharm* 1983;2:12–9.
- [644] Fraunfelder FT, LaBraico JM, Meyer SM. Adverse ocular reactions possibly associated with isotretinoin. *Am J Ophthalmol* 1985;100:534–7.
- [645] Fraunfelder FT, Fraunfelder FW, Edwards R. Ocular side effects possibly associated with isotretinoin usage. *Am J Ophthalmol* 2001;132:299–305.
- [646] Caffery BE, Josephson JE. Ocular side effects of isotretinoin therapy. *J Am Optom Assoc* 1988;59:221–4.
- [647] Denis P, Nordmann JP, Saïag P, Liotet S, Laroche L, Saraux H. Chronic blepharoconjunctivitis during a treatment with acitretin (Soriatane). *J Fr Ophthalmol* 1993;16:191–4.
- [648] Mathers WD, Shields WJ, Sachdev MS, Petroll WM, Jester JV. Meibomian gland morphology and tear osmolarity: changes with Accutane therapy. *Cornea* 1991;10:286–90.
- [649] Bozkurt B, Irke M, Atakan N, Orhan M, Geyik P. Lacrimal function and ocular complications in patients treated with systemic isotretinoin. *Eur J Ophthalmol* 2002;12:173–6.
- [650] Gross EG, Helfgott MA. Retinoids and the eye. *Dermatol Clin* 1992;10:521–31.
- [651] Jaanus SD. Ocular side effects of selected systemic drugs. *Optom Clin* 1992;2:73–96.
- [652] Egger SF, Huber-Spitz V, Bohler K, Raff M, Scholda C, Barisani T, et al. Ocular side effects associated with 13-cis-retinoic acid therapy for acne vulgaris: clinical features, alterations of tearfilm and conjunctival flora. *Acta Ophthalmol Scand* 1995;73:355–7.
- [653] Schiffman RM, Bradford R, Bunnell B, Lai F, Bernstein P, Whitcup SW. A multi-center, double-masked, randomized, vehicle-controlled, parallel group study to evaluate the safety and efficacy of testosterone ophthalmic solution in patients with meibomian gland dysfunction (abstract) *Investig Ophthalmol Vis Sci* 2006. ARVO e-abstract 5608.
- [654] Jester JV, Parfitt GJ, Brown DJ. Meibomian gland dysfunction: hyperkeratinization or atrophy? *BMC Ophthalmol* 2015;15(Suppl 1):156.
- [655] Nien CJ, Paugh JR, Massei S, Wahlert AJ, Kao WW, Jester JV. Age-related changes in the meibomian gland. *Exp Eye Res* 2009;89:1021–7.
- [656] Suhailim JL, Parfitt GJ, Xie Y, De Paiva CS, Pflugfelder SC, Shah TN, et al. Effect of desiccating stress on mouse meibomian gland function. *Ocul Surf* 2014;12:59–68.
- [657] Obata H, Oka T, Yoshitomi F. Impression cytology of meibomian gland secretion. (abstract). *Investig Ophthalmol Vis Sci* 2002. ARVO poster E- 60.
- [658] Iwata S, Lemp MA, Holly FJ, Dohlman CH. Evaporation rate of water from the precorneal tear film and cornea in the rabbit. *Investig Ophthalmol* 1969;8:613–9.
- [659] Lee WB, Hamilton SM, Harris JP, Schwab IR. Ocular complications of hypovitaminosis a after bariatric surgery. *Ophthalmology* 2005;112:1031–4.
- [660] Yagyu H, Kitamine T, Osuga J, Tozawa R, Chen Z, Kaji Y, et al. Absence of ACAT-1 attenuates atherosclerosis but causes dry eye and cutaneous xanthomatosis in mice with congenital hyperlipidemia. *J Biol Chem* 2000;275:21324–30.
- [661] Nolan J. Evaluation of conjunctival and nasal bacterial cultures before intra-ocular operations. *Br J Ophthalmol* 1967;51:483–5.
- [662] Schabereiter-Gurtner C, Maca S, Rolleke S, Nigl K, Lukas J, Hirschl A, et al. 16S rDNA-based identification of bacteria from conjunctival swabs by PCR and DGGE fingerprinting. *Investig Ophthalmol Vis Sci* 2001;42:1164–71.
- [663] Haynes RJ, Tighe PJ, Dua HS. Antimicrobial defensin peptides of the human ocular surface. *Br J Ophthalmol* 1999;83:737–41.
- [664] Dong Q, Brulc JM, Iovieno A, Bates B, Garoutte A, Miller D, et al. Diversity of bacteria at healthy human conjunctiva. *Investig Ophthalmol Vis Sci* 2011;52:5408–13.
- [665] Huang Y, Yang B, Li W. Defining the normal "core microbiome" of conjunctival microbial communities. *Clin Microbiol Infect* 2016; 643e7-643e12.
- [666] Moeller CT, Branco BC, Yu MC, Farah ME, Santos MA, Hofling-Lima AL. Evaluation of normal ocular bacterial flora with two different culture media. *Can J Ophthalmol* 2005;40:448–53.
- [667] Willcox MDP. Characterization of the normal microbiota of the ocular surface. *Exp Eye Res* 2013;117:99–105.
- [668] de Paiva CS, Jones DB, Stern ME, Bian F, Moore QL, Corbiere S, et al. Altered Mucosal Microbiome Diversity and Disease Severity in Sjogren Syndrome. *Sci Rep* 2016;6:23561.

- [669] Graham JE, Moore JE, Jiru X, Moore JE, Goodall EA, Dooley JSG, et al. Ocular Pathogen or Commensal: A PCR-Based Study of Surface Bacterial Flora in Normal and Dry Eyes. *Investig Ophthalmol Vis Sci* 2007;48:5616–23.
- [670] Albietz JM, Lenton LM. Effect of Antibacterial Honey on the Ocular Flora in Tear Deficiency and Meibomian Gland Disease. *Cornea* 2006;25:1012–9.
- [671] Terzulli M, Ruiz LC, Kugadas A, Masli S, Gadjeva M. TSP-1 Deficiency Alters Ocular Microbiota: Implications for Sjogren's Syndrome Pathogenesis. *J Ocul Pharmacol Ther* 2015;31:413–8.
- [672] Wang CZM, Bian F, Britton RA, Pflugfelder SC, De Paiva CS. Sjogren-like Lacrimal Keratoconjunctivitis in Germ-Free Mice. ARVO Meeting. 2016.
- [673] Spöler F, Frentz M, Schrage NF. Towards a new in vitro model of dry eye: the Ex Vivo Eye Irritation Test. *Dev Ophthalmol* 2010;45:93–107.
- [674] Meloni M, De Servi B, Marasco D, Del Prete S. Molecular mechanism of ocular surface damage: application to an in vitro dry eye model on human corneal epithelium. *Mol Vis* 2011;17:113–26.
- [675] Barabino S, De Servi B, Aragona S, Manenti D, Meloni M. Efficacy of a New Ocular Surface Modulator in Restoring Epithelial Changes in an In Vitro Model of Dry Eye Syndrome. *Curr Eye Res* 2017;42:358–63.
- [676] Thompson N, Isenberg DA, Jury EC, Ciurtin C. Exploring BAFF: its expression, receptors and contribution to the immunopathogenesis of Sjogren's syndrome. *Rheumatol Oxf* 2016;55:1548–55.
- [677] Helmick CG, Felson DT, Lawrence RC, Gabriel S, Hirsch R, Kwoh CK, et al. Estimates of the prevalence of arthritis and other rheumatic conditions in the United States. Part I. *Arthritis Rheum* 2008;58:15–25.
- [678] Jacobson DL, Gange SJ, Rose NR, Graham NM. Epidemiology and estimated population burden of selected autoimmune diseases in the United States. *Clin Immunol Immunopathol* 1997;84:223–43.
- [679] Maciel G, Crowson CS, Matteson EL, Corne D. Incidence and Mortality of Physician-Diagnosed Primary Sjogren Syndrome: Time Trends Over a 40-Year Period in a Population-Based US Cohort. *Mayo Clin Proc* 92, 2017, 734–743.
- [680] Maciel G, Crowson CS, Matteson EL, Corne D. Prevalence of Primary Sjogren's Syndrome in a Population-Based Cohort in the United States. *Arthritis Care Res Hob* 2016 [Epub ahead of print].
- [681] Yen JC, Hsu CA, Li YC, Hsu MH. The Prevalence of Dry Eye Syndrome's and the Likelihood to Develop Sjogren's Syndrome in Taiwan: A Population-Based Study. *Int J Environ Res Public Health* 2015;12:7647–55.
- [682] Voulgarelis M, Tzioufas AG. Pathogenetic mechanisms in the initiation and perpetuation of Sjogren's syndrome. *Nat Rev Rheumatol* 2010;6:529–37.
- [683] Nocturne G, Mariette X. Advances in understanding the pathogenesis of primary Sjogren's syndrome. *Nat Rev Rheumatol* 2013;9:544–56.
- [684] Vitali C, Bombardieri S, Jonsson R, Moutsopoulos HM, Alexander EL, Carsons SE, et al. Classification criteria for Sjogren's syndrome: a revised version of the European criteria proposed by the American-European Consensus Group. *Ann Rheum Dis* 2002;61:554–8.
- [685] Aguilar AJ, Fonseca L, Croxatto JO. Sjogren's syndrome: a comparative study of impression cytology of the conjunctiva and buccal mucosa, and salivary gland biopsy. *Cornea* 1991;10:203–6.
- [686] Raphael M, Bellefqih S, Piette JC, Le Hoang P, Debre P, Chomette G. Conjunctival biopsy in Sjogren's syndrome: correlations between histological and immunohistochemical features. *Histopathology* 1988;13:191–202.
- [687] Pflugfelder SC, Jones D, Ji Z, Afonso A, Monroy D. Altered cytokine balance in the tear fluid and conjunctiva of patients with Sjogren's syndrome keratoconjunctivitis sicca. *Curr Eye Res* 1999;19:201–11.
- [688] Roberts DK. Keratoconjunctivitis sicca. *J Am Optom Assoc* 1991;62:187–99.
- [689] Uchino M, Nishiwaki Y, Michikawa T, Shirakawa K, Kuwahara E, Yamada M, et al. Prevalence and Risk Factors of Dry Eye Disease in Japan: Koumi Study. *Ophthalmology* 2011;118:2361–7.
- [690] Sullivan DA. Tearful relationships? Sex, hormones, the lacrimal gland, and aqueous-deficient dry eye. *Ocul Surf* 2004;2:92–123.
- [691] Darabad RR, Suzuki T, Richards SM, Jensen RV, Jakobić FA, Zakka FR, et al. Influence of aromatase absence on the gene expression and histology of the mouse meibomian gland. *Investig Ophthalmol Vis Sci* 2013;54:987–98.
- [692] Rahimi Darabad R, Suzuki T, Richards SM, Jakobić FA, Zakka FR, Barabino S, et al. Does estrogen deficiency cause lacrimal gland inflammation and aqueous-deficient dry eye in mice? *Exp Eye Res* 2014;127:153–60.
- [693] Li L, Kang Q, Wang S, Zheng X. Effects of androgen on ultrastructure of corneal epithelium and function of the tear film in BALB/c mice. *Cornea* 2015;34:334–41.
- [694] Lessard CJ, Li H, Adrianto I, Ice JA, Rasmussen A, Grundahl KM, et al. Variants at multiple loci implicated in both innate and adaptive immune responses are associated with Sjogren's syndrome. *Nat Genet* 2013;45:1284–92.
- [695] Burbelo PD, Ambatipudi K, Alevizos I. Genome-wide association studies in Sjogren's syndrome: What do the genes tell us about disease pathogenesis? *Autoimmun Rev* 2014;13:756–61.
- [696] Carragher DM, Rangel-Moreno J, Randall TD. Ectopic lymphoid tissues and local immunity. *Semin Immunol* 2008;20:26–42.
- [697] Moutsopoulos HM. Sjogren's syndrome: a forty-year scientific journey. *J Autoimmun* 2014;51:1–9.
- [698] Christodoulou MI, Kapsogeorgou EK, Moutsopoulos HM. Characteristics of the minor salivary gland infiltrates in Sjogren's syndrome. *J Autoimmun* 2010;34:400–7.
- [699] Kapsogeorgou EK, Christodoulou MI, Panagiotakos DB, Paikos S, Tassidou A, Tzioufas AG, et al. Minor salivary gland inflammatory lesions in Sjogren syndrome: do they evolve? *J Rheumatol* 2013;40:1566–71.
- [700] Bombardieri M, Barone F, Humby F, Kelly S, McGurk M, Morgan P, et al. Activation-induced cytidine deaminase expression in follicular dendritic cell networks and interfollicular large B cells supports functionality of ectopic lymphoid neogenesis in autoimmune sialoadenitis and MALT lymphoma in Sjogren's syndrome. *J Immunol* 2007;179:4929–38.
- [701] Theander E, Vasaitis L, Baecklund E, Nordmark G, Warfvinge G, Liedholm R, et al. Lymphoid organisation in labial salivary gland biopsies is a possible predictor for the development of malignant lymphoma in primary Sjogren's syndrome. *Ann Rheum Dis* 2011;70:1363–8.
- [702] Boehm N, Riechardt AI, Wiegand M, Pfeiffer N, Grus FH. Proinflammatory cytokine profiling of tears from dry eye patients by means of antibody microarrays. *Investig Ophthalmol Vis Sci* 2011;52:7725–30.
- [703] Kang EH, Lee YJ, Hyon JY, Yun PY, Song YW. Salivary cytokine profiles in primary Sjogren's syndrome differ from those in non-Sjogren sicca in terms of TNF-alpha levels and Th-1/Th-2 ratios. *Clin Exp Rheumatol* 2011;29:970–6.
- [704] Lin X, Rui K, Deng J, Tian J, Wang X, Wang S, et al. Th17 cells play a critical role in the development of experimental Sjogren's syndrome. *Ann Rheum Dis* 2015;74:1302–10.
- [705] Oh JY, Kim MK, Choi HJ, Ko JH, Kang EJ, Lee HJ, et al. Investigating the relationship between serum interleukin-17 levels and systemic immune-mediated disease in patients with dry eye syndrome. *Korean J Ophthalmol* 2011;25:73–6.
- [706] Katsifis GE, Rekka S, Moutsopoulos NM, Pillemer S, Wahl SM. Systemic and local interleukin-17 and linked cytokines associated with Sjogren's syndrome immunopathogenesis. *Am J Pathol* 2009;175:1167–77.
- [707] Nguyen CQ, Hu MH, Li Y, Stewart C, Peck AB. Salivary gland tissue expression of interleukin-23 and interleukin-17 in Sjogren's syndrome: findings in humans and mice. *Arthritis Rheum* 2008;58:734–43.
- [708] Nguyen CQ, Yin H, Lee BH, Carcamo WC, Chiorini JA, Peck AB. Pathogenic effect of interleukin-17A in induction of Sjogren's syndrome-like disease using adenovirus-mediated gene transfer. *Arthritis Res Ther* 2010;12:R220.
- [709] Triantafyllou A, Moutsopoulos HM. Autoimmunity and coxsackievirus infection in primary Sjogren's syndrome. *Ann N Y Acad Sci* 2005;1050:389–96.
- [710] Kapsogeorgou EK, Abu-Helu RF, Moutsopoulos HM, Manoussakis MN. Salivary gland epithelial cell exosomes: A source of autoantigenic ribonucleoproteins. *Arthritis Rheum* 2005;52:1517–21.
- [711] Casciola-Rosen L, Andrade F, Ulanet D, Wong WB, Rosen A. Cleavage by granzyme B is strongly predictive of autoantigen status: implications for initiation of autoimmunity. *J Exp Med* 1999;190:815–26.
- [712] Mitsias DI, Kapsogeorgou EK, Moutsopoulos HM. The role of epithelial cells in the initiation and perpetuation of autoimmune lesions: lessons from Sjogren's syndrome (autoimmune epithelitis). *Lupus* 2006;15:255–61.
- [713] Corne D, Devauchelle-Pensec V, Tobon GJ, Pers JO, Jousse-Joulin S, Saraux A. B cells in Sjogren's syndrome: from pathophysiology to diagnosis and treatment. *J Autoimmun* 2012;39:161–7.
- [714] Ishimaru N, Arakaki R, Watanabe M, Kobayashi M, Miyazaki K, Hayashi Y. Development of autoimmune exocrinopathy resembling Sjogren's syndrome in estrogen-deficient mice of healthy background. *Am J Pathol* 2003;163:1481–90.
- [715] Baudouin C, Brignole F, Pisella PJ, De Jean MS, Goguel A. Flow cytometric analysis of the inflammatory marker HLA DR in dry eye syndrome: results from 12 months of randomized treatment with topical cyclosporin A. *Adv Exp Med Biol* 2002;506:761–9.
- [716] Brignole F, Pisella PJ, De Saint Jean M, Goldschild M, Goguel A, Baudouin C. Flow cytometric analysis of inflammatory markers in KCS: 6-month treatment with topical cyclosporin A. *Investig Ophthalmol Vis Sci* 2001;42:90–5.
- [717] Tsubota K, Fukagawa KT, Shimmura S, Saito I, Saito K, et al. Regulation of human leukocyte antigen expression in human conjunctival epithelium. *Investig Ophthalmol Vis Sci* 1999;40:28–34.
- [718] Youinou P, Pers JO. Primary Sjogren's syndrome at a glance today. *Jt Bone Spine* 2015;82:75–6.
- [719] Gordon TP, Bolstad AI, Rischmueller M, Jonsson R, Waterman SA. Autoantibodies in primary Sjogren's syndrome: new insights into mechanisms of autoantibody diversification and disease pathogenesis. *Autoimmunity* 2001;34:123–32.
- [720] Dawson L, Tobin A, Smith P, Gordon T. Antimuscarinic antibodies in Sjogren's syndrome: where are we, and where are we going? *Arthritis Rheum* 2005;52:2984–95.
- [721] Bacman SR, Berra A, Sterin-Borda L, Borda ES. Human primary Sjogren's syndrome autoantibodies as mediators of nitric oxide release coupled to lacrimal gland muscarinic acetylcholine receptors. *Curr Eye Res* 1998;17:1135–42.
- [722] Bacman S, Perez Leiros C, Sterin-Borda L, Hubscher O, Arana R, Borda E. Autoantibodies against lacrimal gland M3 muscarinic acetylcholine receptors in patients with primary Sjogren's syndrome. *Investig Ophthalmol Vis Sci* 1998;39:151–6.
- [723] Nguyen KH, Brayer J, Cha S, Diggs S, Yasunari U, Hilal G, et al. Evidence for



- antimuscarinic acetylcholine receptor antibody-mediated secretory dysfunction in NOD mice. *Arthritis Rheum* 2000;43:2297–306.
- [724] Cavill D, Waterman SA, Gordon TP. Antibodies raised against the second extracellular loop of the human muscarinic M3 receptor mimic functional autoantibodies in Sjögren's syndrome. *Scand J Immunol* 2004;59:261–6.
- [725] Sullivan DA. Possible mechanisms involved in the reduced tear secretion in Sjögren's syndrome. In: Homma M, Sugai S, Tojo T, Miyasaka N, Akizuki M, editors. *Sjögren's Syndrome State of the Art*. Amsterdam: Kugler Press; 1994. p. 3–19.
- [726] Xu KP, Katagiri S, Takeuchi T, Tsubota K. Biopsy of labial salivary glands and lacrimal glands in the diagnosis of Sjögren's syndrome. *J Rheumatol* 1996;23:76–82.
- [727] Alpert S, Kang HI, Weissman I, Fox RI. Expression of granzyme A in salivary gland biopsies from patients with primary Sjögren's syndrome. *Arthritis Rheum* 1994;37:1046–54.
- [728] Tsubota K, Saito I, Miyasaka N. Granzyme A and perforin expressed in the lacrimal glands of patients with Sjögren's syndrome. *Am J Ophthalmol* 1994;117:120–1.
- [729] Tsubota K, Xu KP, Fujihara T, Katagiri S, Takeuchi T. Decreased reflex tearing is associated with lymphocytic infiltration in lacrimal glands. *J Rheumatol* 1996;23:313–20.
- [730] Knop E, Knop N. [Eye-associated lymphoid tissue (EALT) is continuously spread throughout the ocular surface from the lacrimal gland to the lacrimal drainage system]. *Ophthalmologie* 2003;100:929–42.
- [731] Gao J, Schwab TA, Addeo JV, Ghosn CR, Stern ME. The role of apoptosis in the pathogenesis of canine keratoconjunctivitis sicca: the effect of topical Cyclosporin A therapy. *Cornea* 1998;17:654–63.
- [732] Croft M, Dubey C. Accessory molecule and costimulation requirements for CD4 T cell response. *Crit Rev Immunol* 1997;17:89–118.
- [733] Villani E, Beretta S, De Capitani M, Galimberti D, Viola F, Ratiglia R. In vivo confocal microscopy of meibomian glands in Sjögren's syndrome. *Investig Ophthalmol Vis Sci* 2011;52:933–9.
- [734] Solomon D, Dursun D, Liu Z, Xie Y, Macri A, Pflugfelder SC. Pro- and anti-inflammatory forms of interleukin-1 in the tear fluid and conjunctiva of patients with dry-eye disease. *Investig Ophthalmol Vis Sci* 2001;42:2283–92.
- [735] Caffery BE, Joyce E, Heynen ML, Ritter 3rd R, Jones LA, Senchyna M. Quantification of conjunctival TNF-alpha in aqueous-deficient dry eye. *Optom Vis Sci* 2014;91:156–62.
- [736] Takahashi H, Asano K, Nakamura S, Ishida-Yamamoto A, Iizuka H. Interferon-gamma-dependent stimulation of human involucrin gene expression: STAT1 (signal transduction and activators of transcription 1) protein activates involucrin promoter activity. *Biochem J* 1999;344(Pt 3):797–802.
- [737] Li S, Nikulina K, DeVoss J, Wu AJ, Strauss EC, Anderson MS, et al. Small proline-rich protein 1B (SPRR1B) is a biomarker for squamous metaplasia in dry eye disease. *Investig Ophthalmol Vis Sci* 2008;49:34–41.
- [738] Kawasaki S, Kawamoto S, Yokoi N, Connon C, Minesaki Y, Kinoshita S, et al. Up-regulated gene expression in the conjunctival epithelium of patients with Sjögren's syndrome. *Exp Eye Res* 2003;77:17–26.
- [739] Hirai N, Kawasaki S, Tanioka H, Connon CJ, Yamasaki K, Yokoi N, et al. Pathological keratinisation in the conjunctival epithelium of Sjögren's syndrome. *Exp Eye Res* 2006;82:371–8.
- [740] Tong L, Corrales RM, Chen Z, Villarreal AL, De Paiva CS, Beuerman R, et al. Expression and regulation of cornified envelope proteins in human corneal epithelium. *Investig Ophthalmol Vis Sci* 2006;47:1938–46.
- [741] Vijmasi T, Chen FY, Balasubbu S, Gallup M, McKown RL, Laurie GW, et al. Topical administration of licritin is a novel therapy for aqueous-deficient dry eye disease. *Investig Ophthalmol Vis Sci* 2014;55:5401–9.
- [742] The definition and classification of dry eye disease: report of the Definition and Classification Subcommittee of the International Dry Eye Workshop. *Ocul Surf* 2007;2007(5):75–92.
- [743] Scherz W, Dohlman CH. Is the lacrimal gland dispensable? Keratoconjunctivitis sicca after lacrimal gland removal. *Arch Ophthalmol* 1975;93:281–3.
- [744] Hegab SM, Sheriff SM, el-Aasar ES, Lashin EA, Phillips CI. Congenital alacrima without associated manifestations (AD). An affected father and son. *Ophthalmic Paediatr Genet* 1991;12:161–3.
- [745] Kim SH, Hwang S, Kweon S, Kim TK, Oh J. Two cases of lacrimal gland agenesis in the same family—clinicrodiologic findings and management. *Can J Ophthalmol* 2005;40:502–5.
- [746] Athappilly GK, Braverman RS. Congenital alacrima in a patient with blepharophimosis syndrome. *Ophthalmic Genet* 2009;30:37–9.
- [747] Arya SK, Chaudhuri Z, Jain R, Nahar R, Sood S. Congenital alacrima in Pierre Robin sequence. *Cornea* 2004;23:632–4.
- [748] Brooks BP, Kleta R, Stuart C, Tuchman M, Jeong A, Stergiopoulos SG, et al. Genotypic heterogeneity and clinical phenotype in triple A syndrome: a review of the NIH experience 2000–2005. *Clin Genet* 2005;68:215–21.
- [749] Sarathi V, Shah NS. Triple-A syndrome. *Adv Exp Med Biol* 2010;685:1–8.
- [750] Krumbholz M, Koehler K, Huebner A. Cellular localization of 17 natural mutant variants of ALADIN protein in triple A syndrome - shedding light on an unexpected splice mutation. *Biochem Cell Biol* 2006;84:243–9.
- [751] Rocha EM, Alves M, Rios JD, Dartt DA. The Aging Lacrimal Gland: Changes in Structure and Function. *Ocul Surf* 2008;6:162–74.
- [752] Na KS, Mok JW, Kim JY, Joo CK. Proinflammatory gene polymorphisms are potentially associated with Korean non-Sjögren dry eye patients. *Mol Vis* 2011;17:2818–23.
- [753] Ren G, Shao T, Zhuang Y, Hu H, Zhang X, Huang J, et al. Association of killer cell immunoglobulin-like receptor and human leukocyte antigen-C genotype with dry eye disease in a Chinese Han population. *Genet Test Mol Biomark* 2012;16:910–4.
- [754] Van Haeringen NJ. Aging and the lacrimal system. *Br J Ophthalmol* 1997;81:824–6.
- [755] McGill JI, Liakos GM, Goulding N, Seal DV. Normal tear protein profiles and age-related changes. *Br J Ophthalmol* 1984;68:316–20.
- [756] Seal DV. The effect of ageing and disease on tear constituents. *Trans Ophthalmol Soc U. K* 1985;104(Pt 4):355–62.
- [757] Hamano T, Mitsunaga S, Kotani S, Hamano T, Hamano K, Hamano H, et al. Tear volume in relation to contact lens wear and age. *CLAO J* 1990;16:57–61.
- [758] Boberg-Ans J. On the corneal sensitivity. *Acta Ophthalmol (Copenh)* 1956;34:149–62.
- [759] Millodot M. The influence of age on the sensitivity of the cornea. *Investig Ophthalmol Vis Sci* 1977;16:240–2.
- [760] Acosta MC, Alfaro ML, Borrás F, Belmonte C, Gallar J. Influence of age, gender and iris color on mechanical and chemical sensitivity of the cornea and conjunctiva. *Exp Eye Res* 2006;83:932–8.
- [761] Pietsch RL, Pearlman ME. Human tear lysozyme variables. *Arch Ophthalmol* 1973;90:94–6.
- [762] Bonavida B, Sapse AT. Human tear lysozyme. II. Quantitative determination with standard Schirmer strips. *Am J Ophthalmol* 1968;66:70–6.
- [763] Mathers WD, Lane JA, Zimmerman MB. Tear film changes associated with normal aging. *Cornea* 1996;15:229–34.
- [764] Nasu M, Matsubara O, Yamamoto H. Post-mortem prevalence of lymphocytic infiltration of the lacrimal gland: a comparative study in autoimmune and non-autoimmune diseases. *J Pathol* 1984;143:11–5.
- [765] Damato BE, Allan D, Murray SB, Lee WR. Senile atrophy of the human lacrimal gland: the contribution of chronic inflammatory disease. *Br J Ophthalmol* 1984;68:674–80.
- [766] Obata H, Yamamoto S, Horiuchi H, Machinami R. Histopathologic study of human lacrimal gland. Statistical analysis with special reference to aging. *Ophthalmology* 1995;102:678–86.
- [767] Kojima T, Wakamatsu TH, Dogru M, Ogawa Y, Igarashi A, Ibrahim OM, et al. Age-related dysfunction of the lacrimal gland and oxidative stress: evidence from the Cu,Zn-superoxide dismutase-1 (Sod1) knockout mice. *Am J Pathol* 2012;180:1879–96.
- [768] Zoukhri D, Kublin CL. Impaired neurotransmitter release from lacrimal and salivary gland nerves of a murine model of Sjögren's syndrome. *Investig Ophthalmol Vis Sci* 2001;42:925–32.
- [769] Zoukhri D, Macari E, Kublin CL. A single injection of interleukin-1 induces reversible aqueous-tear deficiency, lacrimal gland inflammation, and acinar and ductal cell proliferation. *Exp Eye Res* 2007;84:894–904.
- [770] Uchino Y, Kawakita T, Miyazawa M, Ishii T, Onouchi H, Yasuda K, et al. Oxidative stress induced inflammation initiates functional decline of tear production. *PLoS One* 2012;7. e45805.
- [771] Halliwell B, Gutteridge JM. Oxygen toxicity, oxygen radicals, transition metals and disease. *Biochem J* 1984;219:1–14.
- [772] Wakamatsu TH, Dogru M, Tsubota K. Tearful relations: oxidative stress, inflammation and eye diseases. *Arq Bras Oftalmol* 2008;71:72–9.
- [773] Augustin AJ, Spitznas M, Kaviani N, Meller D, Koch FH, Grus F, et al. Oxidative reactions in the tear fluid of patients suffering from dry eyes. *Graefes Arch Clin Exp Ophthalmol* 1995;233:694–8.
- [774] Giebel J, Woenckhaus C, Fabian M, Tost F. Age-related differential expression of apoptosis-related genes in conjunctival epithelial cells. *Acta Ophthalmol Scand* 2005;83:471–6.
- [775] Zhu W, Hong J, Zheng T, Le Q, Xu J, Sun X. Age-related changes of human conjunctiva on in vivo confocal microscopy. *Br J Ophthalmol* 2010;94:1448–53.
- [776] Labbe A, Dupas B, Hamard P, Baudouin C. In vivo confocal microscopy study of blebs after filtering surgery. *Ophthalmology* 2005;112:1979.
- [777] Abdel-Khalek LM, Williamson J, Lee WR. Morphological changes in the human conjunctival epithelium. II. In keratoconjunctivitis sicca. *Br J Ophthalmol* 1978;62:800–6.
- [778] Massingale ML, Li X, Vallabhajosyula M, Chen D, Wei Y, Asbell PA. Analysis of inflammatory cytokines in the tears of dry eye patients. *Cornea* 2009;28:1023–7.
- [779] Bresnitz EA, Strom BL. Epidemiology of sarcoidosis. *Epidemiol Rev* 1983;5:124–56.
- [780] Baughman RP, Lower EE, du Bois RM. Sarcoidosis *Lancet* 2003;361:1111–8.
- [781] Jones NP. Sarcoidosis. *Curr Opin Ophthalmol* 2002;13:393–6.
- [782] Pasadhika S, Rosenbaum JT. Ocular Sarcoidosis. *Clin Chest Med* 2015;36:669–83.
- [783] Jones BR, Stevenson CJ. Keratoconjunctivitis sicca due to sarcoidosis. *Br J Ophthalmol* 1957;41:153–60.
- [784] Drosos AA, Constantopoulos SH, Psychos D, Stefanou D, Papadimitriou CS, Moutsopoulos HM. The forgotten cause of sicca complex; sarcoidosis. *J Rheumatol* 1989;16:1548–51.
- [785] Drosos AA, Voulgari PV, Psychos DN, Tsifetaki N, Bai M. Sicca syndrome in patients with sarcoidosis. *Rheumatol Int* 1999;18:177–80.

- [786] Agostini C, Meneghin A, Semenzato G. T-lymphocytes and cytokines in sarcoidosis. *Curr Opin Pulm Med* 2002;8:435–40.
- [787] Barnard J, Newman LS. Sarcoidosis: immunology, rheumatic involvement, and therapeutics. *Curr Opin Rheumatol* 2001;13:84–91.
- [788] Heath P. Ocular lymphomas. *Am J Ophthalmol* 1949;32:1213–23.
- [789] Cacoub P, Renou C, Rosenthal E, Cohen P, Loury I, Loustaud-Ratti V, et al. Extrahepatic manifestations associated with hepatitis C virus infection. A prospective multicenter study of 321 patients. The GERMIVIC. Groupe d'Etude et de Recherche en Medecine Interne et Maladies Infectieuses sur le Virus de l'Hepatite C. *Med Baltim* 2000;79:47–56.
- [790] Ramos-Casals M, Munoz S, Zeron PB. Hepatitis C virus and Sjogren's syndrome: trigger or mimic? *Rheum Dis Clin North Am* 2008;34:869–84. vii.
- [791] Ramos-Casals M, Munoz S, Medina F, Jara LJ, Rosas J, Calvo-Alen J, et al. Systemic autoimmune diseases in patients with hepatitis C virus infection: characterization of 1020 cases (The HISPAMEC Registry). *J Rheumatol* 2009;36:1442–8.
- [792] DeCarlo DK, Penner SL, Schamerloh RJ, Fullard RJ. Dry eye among males infected with the human immunodeficiency virus. *J Am Optom Assoc* 1995;66:533–8.
- [793] Chronister CL. Review of external ocular disease associated with aids and HIV infection. *Optom Vis Sci* 1996;73:225–30.
- [794] Itescu S, Brancato LJ, Buxbaum J, Gregersen PK, Rizk CC, Croxson TS, et al. A diffuse infiltrative CD8 lymphocytosis syndrome in human immunodeficiency virus (HIV) infection: a host immune response associated with HLA-DR5. *Ann Intern Med* 1990;112:3–10.
- [795] Durkin SR, Roos D, Higgs B, Casson RJ, Selva D. Ophthalmologic and adnexal complications of radiotherapy. *Acta Ophthalmol Scand* 2007;85:240–50.
- [796] Bhandare N, Moiseenko V, Song WY, Morris CG, Bhatti MT, Mendenhall WM. Severe dry eye syndrome after radiotherapy for head-and-neck tumors. *Int J Radiat Oncol Biol Phys* 2012;82:1501–8.
- [797] Bessell EM, Henk JM, Whitelocke RA, Wright JE. Ocular morbidity after radiotherapy of orbital and conjunctival lymphoma. *Eye (Lond)* 1987;1(Pt 1):90–6.
- [798] Stafford SL, Kozelsky TF, Garrity JA, Kurtin PJ, Leavitt JA, Martenson JA, et al. Orbital lymphoma: radiotherapy outcome and complications. *Radiother Oncol* 2001;59:139–44.
- [799] Gamus D, Weschler Z, Greenberg S, Romano A. Decreased tear secretion in Chernobyl children: external eye disorders in children subjected to long-term low-dose radiation. *Adv Exp Med Biol* 1994;350:513–6.
- [800] Gazda MJ, Schultheiss TE, Stephens LC, Ang KK, Peters LJ. The relationship between apoptosis and atrophy in the irradiated lacrimal gland. *Int J Radiat Oncol Biol Phys* 1992;24:693–7.
- [801] Hakim SG, Schroder C, Geerling G, Lauer I, Wedel T, Kosmehl H, et al. Early and late immunohistochemical and ultrastructural changes associated with functional impairment of the lachrymal gland following external beam radiation. *Int J Exp Pathol* 2006;87:65–71.
- [802] Stephens L, Schultheiss TE, Peters LJ, Ang K, Gray KN. Acute radiation injury of ocular adnexa. *Arch Ophthalmol* 1988;106:389–91.
- [803] Stephens LC, Schultheiss TE, Price RE, Ang KK, Peters LJ. Radiation apoptosis of serous acinar cells of salivary and lacrimal glands. *Cancer* 1991;67:1539–43.
- [804] Radford CF, Rauz S, Williams GP, Saw VP, Dart JK. Incidence, presenting features, and diagnosis of cicatrizing conjunctivitis in the United Kingdom. *Eye (Lond)* 2012;26:1199–208.
- [805] Saboo US, Amparo F, Abud TB, Schaumberg DA, Dana R. Vision-Related Quality of Life in Patients with Ocular Graft-versus-Host Disease. *Ophthalmology* 2015;122:1669–74.
- [806] Shikari H, Antin JH, Dana R. Ocular graft-versus-host disease: a review. *Surv Ophthalmol* 2013;58:233–51.
- [807] Nassar A, Tabbara KF, Aljurf M. Ocular manifestations of graft-versus-host disease. *Saudi J Ophthalmol* 2013;27:215–22.
- [808] Kim SK. Ocular graft vs. host disease. *Ocul Surf* 2005;3:S177–9.
- [809] Mencucci R, Rossi Ferrini C, Bosi A, Volpe R, Guidi S, Salvi G. Ophthalmological aspects in allogeneic bone marrow transplantation: Sjogren-like syndrome in graft-versus-host disease. *Eur J Ophthalmol* 1997;7:13–8.
- [810] Jack MK, Hicks JD. Ocular complications in high-dose chemoradiotherapy and marrow transplantation. *Ann Ophthalmol* 1981;13:709–11.
- [811] Vanathi M, Kashyap S, Khan R, Seth T, Mishra P, Mahapatra M, et al. Ocular surface evaluation in allogeneic hematopoietic stem cell transplantation patients. *Eur J Ophthalmol* 2014;24:655–66.
- [812] Alves M, Reinach PS, Paula JS, Vellasco e Cruz AA, Bachellet L, Faustino J, et al. Comparison of diagnostic tests in distinct well-defined conditions related to dry eye disease. *PLoS One* 2014;9: e97921.
- [813] Espana EM, Shah S, Santhiago MR, Singh AD. Graft versus host disease: clinical evaluation, diagnosis and management. *Graefes Arch Clin Exp Ophthalmol* 2013;251:1257–66.
- [814] Ogawa Y, Okamoto S, Wakui M, Watanabe R, Yamada M, Yoshino M, et al. Dry eye after haematopoietic stem cell transplantation. *Br J Ophthalmol* 1999;83:1125–30.
- [815] Ogawa Y, Morikawa S, Okano H, Mabuchi Y, Suzuki S, Yaguchi T, et al. MHC-compatible bone marrow stromal/stem cells trigger fibrosis by activating host T cells in a scleroderma mouse model. *eLife* 2016;4: e09394.
- [816] Uchino M, Ogawa Y, Uchino Y, Mori T, Okamoto S, Tsubota K. Comparison of stem cell sources in the severity of dry eye after allogeneic haematopoietic stem cell transplantation. *Br J Ophthalmol* 2012;96:34–7.
- [817] Kamoi M, Ogawa Y, Uchino M, Tatematsu Y, Mori T, Okamoto S, et al. Donor-recipient gender difference affects severity of dry eye after hematopoietic stem cell transplantation. *Eye (Lond)* 2011;25:860–5.
- [818] Jacobs R, Tran U, Chen H, Kassim A, Engelhardt BG, Greer JP, et al. Prevalence and risk factors associated with development of ocular GVHD defined by NIH consensus criteria. *Bone Marrow Transpl* 2012;47:1470–3.
- [819] Na KS, Yoo YS, Mok JW, Lee JW, Joo CK. Incidence and risk factors for ocular GVHD after allogeneic hematopoietic stem cell transplantation. *Bone Marrow Transpl* 2015;50:1459–64.
- [820] Yaguchi S, Ogawa Y, Kawakita T, Shimmura S, Tsubota K. Tissue Renin-Angiotensin System in Lacrimal Gland Fibrosis in a Murine Model of Chronic Graft-Versus-Host Disease. *Cornea* 2015;34(Suppl 11):S142–52.
- [821] Ogawa Y, Shimmura S, Kawakita T, Yoshida S, Kawakami Y, Tsubota K. Epithelial mesenchymal transition in human ocular chronic graft-versus-host disease. *Am J Pathol* 2009;175:2372–81.
- [822] Ogawa Y, Kodama H, Kameyama K, Yamazaki K, Yasuoka H, Okamoto S, et al. Donor fibroblast chimerism in the pathogenic fibrotic lesion of human chronic graft-versus-host disease. *Investig Ophthalmol Vis Sci* 2005;46:4519–27.
- [823] Ogawa Y, Yamazaki K, Kuwana M, Mashima Y, Nakamura Y, Ishida S, et al. A significant role of stromal fibroblasts in rapidly progressive dry eye in patients with chronic GVHD. *Investig Ophthalmol Vis Sci* 2001;42:111–9.
- [824] Jabs DA, Hirst LW, Green WR, Tutschka PJ, Santos GW, Beschoner WE. The eye in bone marrow transplantation. II. Histopathology. *Arch Ophthalmol* 1983;101:585–90.
- [825] Ban Y, Ogawa Y, Ibrahim OM, Tatematsu Y, Kamoi M, Uchino M, et al. Morphologic evaluation of meibomian glands in chronic graft-versus-host disease using *in vivo* laser confocal microscopy. *Mol Vis* 2011;17:2533–43.
- [826] Tatematsu Y, Ogawa Y, Shimmura S, Dogru M, Yaguchi S, Nagai T, et al. Mucosal microvilli in dry eye patients with chronic GVHD. *Bone Marrow Transpl* 2012;47:416–25.
- [827] Li P, Sun Y, Hariri S, Zhou Z, Inamoto Y, Lee SJ, et al. Anterior segment optical coherence tomography evaluation of ocular graft-versus-host disease: a case study. *Quant Imaging Med Surg* 2015;5:163–70.
- [828] Ogawa Y, Kuwana MK, Mashima Y, Yamada M, Mori T, et al. Periductal area as the primary site for T-cell activation in lacrimal gland chronic graft-versus-host disease. *Investig Ophthalmol Vis Sci* 2003;44:1888–96.
- [829] Yaguchi S, Ogawa Y, Shimmura S, Kawakita T, Hatou S, Satofuka S, et al. Angiotensin II type 1 receptor antagonist attenuates lacrimal gland, lung, and liver fibrosis in a murine model of chronic graft-versus-host disease. *PLoS One* 2013;8: e64724.
- [830] Engel LA, Wittig S, Bock F, Sauerbier L, Scheid C, Holtick U, et al. Meibography and meibomian gland measurements in ocular graft-versus-host disease. *Bone Marrow Transpl* 2015;50:961–7.
- [831] Rojas B, Cuhna R, Zafirakis P, Ramirez JM, Lizan-garcia M, Zhao T, et al. Cell populations and adhesion molecules expression in conjunctiva before and after bone marrow transplantation. *Exp Eye Res* 2005;81:313–25.
- [832] Robinson MR, Lee SS, Rubin BI, Wayne AS, Pavletic SZ, Bishop MR, et al. Topical corticosteroid therapy for cicatricial conjunctivitis associated with chronic graft-versus-host disease. *Bone Marrow Transpl* 2004;33:1031–5.
- [833] Westekemper H, Meller S, Citak S, Schulte C, Steuhl KP, Homey B, et al. Differential chemokine expression in chronic GVHD of the conjunctiva. *Bone Marrow Transpl* 2010;45:1340–6.
- [834] Suzuki M, Usui T, Kinoshita N, Yamagami S, Amano S. A case of sterile corneal perforation after bone marrow transplantation. *Eye (Lond)* 2007;21:114–6.
- [835] Inagaki E, Ogawa Y, Matsumoto Y, Kawakita T, Shimmura S, Tsubota K. Four cases of corneal perforation in patients with chronic graft-versus-host disease. *Mol Vis* 2011;17:598–606.
- [836] Ban Y, Ogawa Y, Goto E, Uchino M, Terauchi N, Seki M, et al. Tear function and lipid layer alterations in dry eye patients with chronic graft-vs-host disease. *Eye (Lond)* 2009;23:202–8.
- [837] Berchicci L, Iuliano L, Miserocchi E, Bandello F, Modorati G. Tear osmolarity in ocular graft-versus-host disease. *Cornea* 2014;33:1252–6.
- [838] Riemens A, Stoyanova E, Rothova A, Kuiper J. Cytokines in tear fluid of patients with ocular graft-versus-host disease after allogeneic stem cell transplantation. *Mol Vis* 2012;18:797–802.
- [839] Jung JW, Han SJ, Song MK, Kim TI, Kim EK, Min YH, et al. Tear Cytokines as Biomarkers for Chronic Graft-versus-Host Disease. *Biol Blood Marrow Transpl* 2015;21:2079–85.
- [840] Sakimoto T, Ohnishi T, Ishimori A. Significance of ectodomain shedding of TNF receptor 1 in ocular surface. *Investig Ophthalmol Vis Sci* 2014;55:2419–23.
- [841] Hassan AS, Clouthier SG, Ferrara JL, Stepan A, Mian SI, Ahmad AZ, et al. Lacrimal gland involvement in graft-versus-host disease: a murine model. *Investig Ophthalmol Vis Sci* 2005;46:2692–7.
- [842] Cocho L, Fernandez I, Calonge M, Martinez V, Gonzalez-Garcia MJ, Caballero D, et al. Gene Expression-Based Predictive Models of Graft Versus Host Disease-Associated Dry Eye. *Investig Ophthalmol Vis Sci* 2015;56:4570–81.
- [843] Sotozono C, Ueta M, Nakatani E, Kitami A, Watanabe H, Sueki H, et al. Predictive Factors Associated With Acute Ocular Involvement in Stevens-

- Johnson Syndrome and Toxic Epidermal Necrolysis. *Am J Ophthalmol* 2015;160:228–37.
- [844] Saeed H, Mantagos IS, Chodosh J. Complications of Stevens-Johnson syndrome beyond the eye and skin. *Burns* 2016;42:20–7.
- [845] Roujeau JC. The spectrum of Stevens-Johnson syndrome and toxic epidermal necrolysis: a clinical classification. *J Invest Dermatol* 1994;102:28S–30S.
- [846] Kohanim S, Palioura S, Saeed HN, Akpek EK, Amescua G, Basu S, et al. Stevens-Johnson Syndrome/Toxic Epidermal Necrolysis—A Comprehensive Review and Guide to Therapy. I. Systemic Disease. *Ocul Surf* 2016;14:2–19.
- [847] Hutchinson JK, Gurwood AS. Iatrogenically induced Stevens-Johnson syndrome after a car accident. *Optometry* 2011;82:9–14.
- [848] Jensen S. A case of Stevens-Johnson's syndrome following antiepileptic medication. *Acta Ophthalmol (Copenh)* 1967;45:576–81.
- [849] Chhipa SA, Masood S, Salarzai Y, Khan QA, Ahmad K, Sajid S. Ocular manifestation, complications and aetiological factors in Stevens-Johnson syndrome/toxic epidermal necrolysis. *J Pak Med Assoc* 2015;65:62–4.
- [850] Ueta M, Sawai H, Sotozono C, Hitomi Y, Kaniwa N, Kim MK, et al. IKZF1, a new susceptibility gene for cold medicine-related Stevens-Johnson syndrome/toxic epidermal necrolysis with severe mucosal involvement. *J Allergy Clin Immunol* 2015;135:1538–45. e1517.
- [851] Goldberg D, Panigrahi D, Barazi M, Abelson M, Butrus S. A case of rofecoxib-associated Stevens-Johnson syndrome with corneal and conjunctival changes. *Cornea* 2004;23:736–7.
- [852] Lau B, Mutyala D, Dhaliwal D. A case report of doxycycline-induced Stevens-Johnson syndrome. *Cornea* 2011;30:595–7.
- [853] Kumar RS, Tan DT, Yong-Ming P, Francis OT, Sek-Tien H, Anand P, et al. Stevens-Johnson Syndrome and Acetazolamide. *J Glaucoma* 2011 [Epub ahead of print].
- [854] Schulze Schwing M, Kayange P, van Oosterhout JJ, Spitzer MS. Severe eye complications from Stevens-Johnson syndrome in a human immunodeficiency virus-infected patient in Malawi. *Am J Trop Med Hyg* 2013;89:162–4.
- [855] Saka B, Barro-Traore F, Atadokpede FA, Kobangue L, Niamba PA, Adegbidi H, et al. Stevens-Johnson syndrome and toxic epidermal necrolysis in sub-Saharan Africa: a multicentric study in four countries. *Int J Dermatol* 2013;52:575–9.
- [856] Chung WH, Hung SI, Hong HS, Hsieh MS, Yang LC, Ho HC, et al. Medical genetics: a marker for Stevens-Johnson syndrome. *Nature* 2004;428:486.
- [857] Ueta M, Tokunaga K, Sotozono C, Sawai H, Tamiya G, Inatomi T, et al. HLA-A\*0206 with TLR3 polymorphisms exerts more than additive effects in Stevens-Johnson syndrome with severe ocular surface complications. *PLoS One* 2012;7. e43650.
- [858] Sotozono C, Inagaki K, Fujita A, Koizumi N, Sano Y, Inatomi T, et al. Methicillin-resistant *Staphylococcus aureus* and methicillin-resistant *Staphylococcus epidermidis* infections in the cornea. *Cornea* 2002;21:S94–101.
- [859] Ueta M, Tamiya G, Tokunaga K, Sotozono C, Ueki M, Sawai H, et al. Epistatic interaction between Toll-like receptor 3 (TLR3) and prostaglandin E receptor 3 (PTGER3) genes. *J Allergy Clin Immunol* 2012;129:1413 e11–6 e11.
- [860] Correia O, Delgado L, Ramos JP, Resende C, Torrinha JA. Cutaneous T-cell recruitment in toxic epidermal necrolysis. Further evidence of CD8+ lymphocyte involvement. *Arch Dermatol* 1993;129:466–8.
- [861] Wolkenstein P, Chosidow O, Flechet ML, Robbiola O, Paul M, Dume L, et al. Patch testing in severe cutaneous adverse drug reactions, including Stevens-Johnson syndrome and toxic epidermal necrolysis. *Contact Dermat* 1996;35:234–6.
- [862] Bolitho P, Voskoboinik I, Trapani JA, Smyth MJ. Apoptosis induced by the lymphocyte effector molecule perforin. *Curr Opin Immunol* 2007;19:339–47.
- [863] Tsubota K, Satake Y, Kaido M, Shinozaki N, Shimmura S, Bissen-Miyajima H, et al. Treatment of severe ocular-surface disorders with corneal epithelial stem-cell transplantation. *N Engl J Med* 1999;340:1697–703.
- [864] Kaido M, Dogru M, Yamada M, Sotozono C, Kinoshita S, Shimazaki J, et al. Functional visual acuity in Stevens-Johnson syndrome. *Am J Ophthalmol* 2006;142:917–22.
- [865] Kang MH, Kim MK, Lee HJ, Lee HI, Wee WR, Lee JH. Interleukin-17 in various ocular surface inflammatory diseases. *J Korean Med Sci* 2011;26:938–44.
- [866] Ohashi Y, Ishida R, Kojima T, Goto E, Matsumoto Y, Watanabe K, et al. Abnormal protein profiles in tears with dry eye syndrome. *Am J Ophthalmol* 2003;136:291–9.
- [867] Lopez-Garcia JS, Rivas Jara L, Garcia-Lozano CI, Conesa E, de Juan IE, Murube del Castillo J. Ocular features and histopathologic changes during follow-up of toxic epidermal necrolysis. *Ophthalmology* 2011;118:265–71.
- [868] Tanioka H, Kawasaki S, Sotozono C, Nakamura T, Inatomi T, Kinoshita S. The relationship between preoperative clinical scores and immunohistological evaluation of surgically resected tissues in chronic severe ocular surface diseases. *Jpn J Ophthalmol* 2010;54:66–73.
- [869] Nakamura T, Nishida K, Dota A, Matsuki M, Yamanishi K, Kinoshita S. Elevated expression of transglutaminase 1 and keratinization-related proteins in conjunctiva in severe ocular surface disease. *Investig Ophthalmol Vis Sci* 2001;42:549–56.
- [870] Nishida K, Yamanishi K, Yamada K, Dota A, Kawasaki S, Quantock AJ, et al. Epithelial hyperproliferation and transglutaminase 1 gene expression in Stevens-Johnson syndrome conjunctiva. *Am J Pathol* 1999;154:331–6.
- [871] Lund AS, Heegaard S, Prause JU, Toft PB, Skov L. Expression of filaggrin in normal and keratinized conjunctiva. *Open Ophthalmol J* 2012;6:137–40.
- [872] Woo SBGM. Ulcerative, vesicular, and bullous lesions. In: Greenberg msgms JA, editor. *Burket's Oral Medicine: Diagnosis and Treatment*. Hamilton: B.C. Decker Inc; 2008.
- [873] Xu HH, Werth VP, Parisi E, Sollecito TP. Mucous membrane pemphigoid. *Dent Clin North Am* 2013;57:611–30.
- [874] Chan LS. Mucous membrane pemphigoid. *Clin Dermatol* 2001;19:703–11.
- [875] Thorne JE, Anhalt GJ, Jabs DA. Mucous membrane pemphigoid and pseudo-pemphigoid. *Ophthalmology* 2004;111:45–52.
- [876] Bernard P, Vaillant L, Labeille B, Bedane C, Arbeille B, Denoex JP, et al. Incidence and distribution of subepidermal autoimmune bullous skin diseases in three French regions. *Bullous Diseases French Study Group. Arch Dermatol* 1995;131:48–52.
- [877] Bertram F, Brocker EB, Zillikens D, Schmidt E. Prospective analysis of the incidence of autoimmune bullous disorders in Lower Franconia, Germany. *J Dtsch Dermatol Ges* 2009;7:434–40.
- [878] Mondino BJ, Brown SI, Rabin BS. HLA antigens in ocular cicatricial pemphigoid. *Br J Ophthalmol* 1978;62:265–7.
- [879] Ahmed AR, Foster S, Zaltas M, Notani G, Awdeh Z, Alper CA, et al. Association of DQw7 (DQB1\*0301) with ocular cicatricial pemphigoid. *Proc Natl Acad Sci U. S. A* 1991;88:11579–82.
- [880] Olsen KE, Holland EJ. The association between ocular cicatricial pemphigoid and rheumatoid arthritis. *Cornea* 1998;17:504–7.
- [881] Miserocchi E, Waheed NK, Baltatzis S, Foster CS. Chronic cicatrizing conjunctivitis in a patient with ocular cicatricial pemphigoid and fatal Wegener granulomatosis. *Am J Ophthalmol* 2001;132:923–4.
- [882] Hatton MP, Raizman M, Foster CS. Exacerbation of undiagnosed ocular cicatricial pemphigoid after repair of involutional entropion. *Ophthalm Plast Reconstr Surg* 2008;24:165–6.
- [883] Lazarova Z, Yee C, Darling T, Briggaman RA, Yancey KB. Passive transfer of anti-laminin 5 antibodies induces subepidermal blisters in neonatal mice. *J Clin Invest* 1996;98:1509–18.
- [884] Bernauer W, Wright P, Dart JK, Leonard JN, Lightman S. Cytokines in the conjunctiva of acute and chronic mucous membrane pemphigoid: an immunohistochemical analysis. *Graefes Arch Clin Exp Ophthalmol* 1993;231:563–70.
- [885] Mondino BJ, Rao H, Brown SI. T and B lymphocytes in ocular cicatricial pemphigoid. *Am J Ophthalmol* 1981;92:536–42.
- [886] Bodaghi B, Bertin V, Paques M, Toubiane M, Dezutter-Dambuyant C, Hoang-Xuan T. Limbal conjunctival Langerhans cell density in ocular cicatricial pemphigoid: an indirect immunofluorescence study on Dispase-split conjunctiva. *Curr Eye Res* 1997;16:820–4.
- [887] Lambiasi A, Micera A, Mantelli F, Moretti C, Di Zazzo A, Perrella E, et al. T-helper 17 lymphocytes in ocular cicatricial pemphigoid. *Mol Vis* 2009;15:1449–55.
- [888] Tesavivul N, Dorfman D, Sangwan VS, Christen W, Panayotis Z, Rojas B, et al. Costimulatory molecules in ocular cicatricial pemphigoid. *Investig Ophthalmol Vis Sci* 1998;39:982–8.
- [889] Kiang E, Tesavivul N, Yee R, Kellaway J, Przepiorka D. The use of topical cyclosporin A in ocular graft-versus-host-disease. *Bone Marrow Transpl* 1998;22:147–51.
- [890] Hoang-Xuan T, Foster CS, Raizman MB, Greenwood B. Mast cells in conjunctiva affected by cicatricial pemphigoid. *Ophthalmology* 1989;96:1110–4.
- [891] Saito T, Nishida K, Sugiyama H, Yamato M, Maeda N, Okano T, et al. Abnormal keratocytes and stromal inflammation in chronic phase of severe ocular surface diseases with stem cell deficiency. *Br J Ophthalmol* 2008;92:404–10.
- [892] Razaque MS, Ahmed BS, Foster CS, Ahmed AR. Effects of IL-4 on conjunctival fibroblasts: possible role in ocular cicatricial pemphigoid. *Investig Ophthalmol Vis Sci* 2003;44:3417–23.
- [893] Razaque MS, Foster CS, Ahmed AR. Role of enhanced expression of m-CSF in conjunctiva affected by cicatricial pemphigoid. *Investig Ophthalmol Vis Sci* 2002;43:2977–83.
- [894] Razaque MS, Foster CS, Ahmed AR. Role of collagen-binding heat shock protein 47 and transforming growth factor-beta1 in conjunctival scarring in ocular cicatricial pemphigoid. *Investig Ophthalmol Vis Sci* 2003;44:1616–21.
- [895] Razaque MS, Foster CS, Ahmed AR. Role of connective tissue growth factor in the pathogenesis of conjunctival scarring in ocular cicatricial pemphigoid. *Investig Ophthalmol Vis Sci* 2003;44:1998–2003.
- [896] Chan MF, Sack R, Quigley DA, Sathe S, Vijmasi T, Li S, et al. Membrane array analysis of tear proteins in ocular cicatricial pemphigoid. *Optom Vis Sci* 2011;88:1005–9.
- [897] Letko E, Papaliadis DN, Papaliadis GN, Daoud YJ, Ahmed AR, Foster CS. Stevens-Johnson syndrome and toxic epidermal necrolysis: a review of the literature. *Ann Allergy Asthma Immunol* 2005;94:419–36. quiz 436–448, 456.
- [898] Tyagi S, Bhol K, Natarajan K, Livir-Rallatos C, Foster CS, Ahmed AR. Ocular cicatricial pemphigoid antigen: partial sequence and biochemical characterization. *Proc Natl Acad Sci U. S. A* 1996;93:14714–9.
- [899] Ahmed M, Zein G, Khawaja F, Foster CS. Ocular cicatricial pemphigoid: pathogenesis, diagnosis and treatment. *Prog Retin Eye Res* 2004;23:579–92.

- [900] Merchant S, Weinstein M. Pemphigus vulgaris: the eyes have it. *Pediatrics* 2003;112:183–5.
- [901] Amagai M. Autoimmunity against desmosomal cadherins in pemphigus. *J Dermatol Sci* 1999;20:92–102.
- [902] Scully C, Challacombe SJ. Pemphigus vulgaris: update on etiopathogenesis, oral manifestations, and management. *Crit Rev Oral Biol Med* 2002;13:397–408.
- [903] Hodak E, Kremer I, David M, Hazaz B, Rothem A, Feuerman P, et al. Conjunctival involvement in pemphigus vulgaris: a clinical, histopathological and immunofluorescence study. *Br J Dermatol* 1990;123:615–20.
- [904] Guzey M, Ozardali I, Basar E, Aslan G, Satici A, Karadede S. A survey of trachoma: the histopathology and the mechanism of progressive cicatrization of eyelid tissues. *Ophthalmologica* 2000;214:277–84.
- [905] al-Rajhi AA, Hidayat A, Nasr A, al-Faran M. The histopathology and the mechanism of entropion in patients with trachoma. *Ophthalmology* 1993;100:1293–6.
- [906] Hu VH, Holland MJ, Cree IA, Pullin J, Weiss HA, Massae P, et al. In vivo confocal microscopy and histopathology of the conjunctiva in trachomatous scarring and normal tissue: a systematic comparison. *Br J Ophthalmol* 2013;97:1333–7.
- [907] White ML, Chodosh J, Jang J, Dohlman C. Incidence of Stevens-Johnson Syndrome and Chemical Burns to the Eye. *Cornea* 2015;34:1527–33.
- [908] Roper-Hall MJ. A retrospective study of eye injuries. *Ophthalmologica* 1969;1–3:12–27.
- [909] Wagoner MD. Chemical injuries of the eye: current concepts in pathophysiology and therapy. *Surv Ophthalmol* 1997;41:275–313.
- [910] Dua HS, King AJ, Joseph A. A new classification of ocular surface burns. *Br J Ophthalmol* 2001;85:1379–83.
- [911] Bagley DM, Casterton PL, Dressler WE, Edelhauser HF, Kruszewski FH, McCulley JP, et al. Proposed new classification scheme for chemical injury to the human eye. *Regul Toxicol Pharmacol* 2006;45:206–13.
- [912] Gupta N, Kalaivani M, Tandon R. Comparison of prognostic value of Roper Hall and Dua classification systems in acute ocular burns. *Br J Ophthalmol* 2011;95:194–8.
- [913] Volkov VV, Brzheshkii VV, Gladkikh AF. The diagnosis and treatment of the dry eye syndrome of burn etiology. *Oftalmol Zh* 1990;328–30.
- [914] Beuerman RW, Schimmelpfennig B. Sensory denervation of the rabbit cornea affects epithelial properties. *Exp Neurol* 1980;69:196–201.
- [915] Blanco-Mezquita T, Martinez-Garcia C, Proenca R, Zieske JD, Bonini S, Lambiase A, et al. Nerve growth factor promotes corneal epithelial migration by enhancing expression of matrix metalloproteinase-9. *Investig Ophthalmol Vis Sci* 2013;54:3880–90.
- [916] Shaheen BS, Bakir M, Jain S. Corneal nerves in health and disease. *Surv Ophthalmol* 2014;59:263–85.
- [917] Patel M, Fraunfelder FW. Toxicity of topical ophthalmic anesthetics. *Expert Opin Drug Metab Toxicol* 2013;9:983–8.
- [918] Chao C, Golebiowski B, Stapleton F. The role of corneal innervation in LASIK-induced neuropathic dry eye. *Ocul Surf* 2014;12:32–45.
- [919] Benitez-del-Castillo JM, del Rio T, Iradier T, Hernandez JL, Castillo A, Garcia-Sanchez J. Decrease in tear secretion and corneal sensitivity after laser in situ keratomileusis. *Cornea* 2001;20:30–2.
- [920] Battat L, Macri A, Dursun D, Pflugfelder SC. Effects of laser in situ keratomileusis on tear production, clearance, and the ocular surface. *Ophthalmology* 2001;108:1230–5.
- [921] Muller LJ, Marfurt CF, Kruse F, Tervo TM. Corneal nerves: structure, contents and function. *Exp Eye Res* 2003;76:521–42.
- [922] Nettune GR, Pflugfelder SC. Post-LASIK tear dysfunction and dysesthesia. *Ocul Surf* 2010;8:135–45.
- [923] De Paiva CS, Chen Z, Koch DD, Hamill MB, Manuel FK, Hassan SS, et al. The incidence and risk factors for developing dry eye after myopic LASIK. *Am J Ophthalmol* 2006;141:438–45.
- [924] Raouf D, Pineda R. Dry eye after laser in-situ keratomileusis. *Semin Ophthalmol* 2014;29:358–62.
- [925] Lee JB, Ryu CH, Kim J, Kim EK, Kim HB. Comparison of tear secretion and tear film instability after photorefractive keratectomy and laser in situ keratomileusis. *J Cataract Refract Surg* 2000;26:1326–31.
- [926] Wilson SE. Laser in situ keratomileusis-induced (presumed) neurotrophic epitheliopathy. *Ophthalmology* 2001;108:1082–7.
- [927] Bonini S, Rama P, Olzi D, Lambiase A. Neurotrophic keratitis. *Eye (Lond)* 2003;17:989–95.
- [928] Harding SP, Lipton JR, Wells JC. Natural history of herpes zoster ophthalmicus: predictors of postherpetic neuralgia and ocular involvement. *Br J Ophthalmol* 1987;71:353–8.
- [929] Ljubimov AV, Saghizadeh M. Progress in corneal wound healing. *Prog Retin Eye Res* 2015;49:17–45.
- [930] Chikama T, Fukuda K, Morishige N, Nishida T. Treatment of neurotrophic keratopathy with substance-P-derived peptide (FGLM) and insulin-like growth factor I. *Lancet* 1998;351:1783–4.
- [931] Lambiase A, Rama P, Bonini S, Caprioglio G, Aloe L. Topical treatment with nerve growth factor for corneal neurotrophic ulcers. *N Engl J Med* 1998;338:1174–80.
- [932] Bonini S, Lambiase A, Rama P, Caprioglio G, Aloe L. Topical treatment with nerve growth factor for neurotrophic keratitis. *Ophthalmology* 2000;107:1347–51. discussion 1351–1342.
- [933] Nichols KK, Redfern RL, Jacob JT, Nelson JD, Fonn D, Forstot SL, et al. The TFOS International Workshop on Contact Lens Discomfort: report of the definition and classification subcommittee. *Investig Ophthalmol Vis Sci* 2013;54:TFOS14–19.
- [934] Tamura M, Murata N, Hayashi M, Regis J. Injury of the lacrimal component of the nervus intermedius function after radiosurgery versus microsurgery. *Neurochirurgie* 2004;50:338–44.
- [935] Ayberk G, Ozveren MF, Uzum N, Tosun O, Akcay EK. Cellular schwannoma of the greater superficial petrosal nerve presenting with abducens nerve palsy and xerophthalmia: case report. *Neurosurgery* 2008;63:E813–4. discussion E4.
- [936] Ichimura S, Yoshida K, Sutiono AB, Horiguchi T, Sasaki H, Kawase T. Greater petrosal nerve schwannomas-analysis of four cases and review of the literature. *Neurosurg Rev* 2010;33:477–82.
- [937] Wong J, Lan W, Ong LM, Tong L. Non-hormonal systemic medications and dry eye. *Ocul Surf* 2011;9:212–26.
- [938] Fraunfelder FT, Sciubba JJ, Mathers WD. The role of medications in causing dry eye. *J Ophthalmol* 2012;2012:285851.
- [939] Gu Q, Dillon CF, Burt VL. Prescription drug use continues to increase: U.S. prescription drug data for 2007–2008. In: Statistics NCHS, editor. NCHS data brief, no 42. Hyattsville, MD; 2010.
- [940] Moss SE, Klein R, Klein BE. Long-term incidence of dry eye in an older population. *Optom Vis Sci* 2008;85:668–74.
- [941] Gold-von Simson G, Axelrod FB. Familial dysautonomia: update and recent advances. *Curr Probl Pediatr Adolesc Health Care* 2006;36:218–37.
- [942] Grandas F, Elston J, Quinn N, Marsden CD. Blepharospasm: a review of 264 patients. *J Neurol Neurosurg Psychiatry* 1988;51:767–72.
- [943] Lu R, Huang R, Li K, Zhang X, Yang H, Quan Y, et al. The influence of benign essential blepharospasm on dry eye disease and ocular inflammation. *Am J Ophthalmol* 2014;157:591–7. e591–592.
- [944] Park DI, Shin HM, Lee SY, Lew H. Tear production and drainage after botulinum toxin A injection in patients with essential blepharospasm. *Acta Ophthalmol* 2013;91:e108–112.
- [945] Tsubota K, Fujihara T, Kaido M, Mori A, Mimura M, Kato M. Dry eye and Meige's syndrome. *Br J Ophthalmol* 1997;81:439–42.
- [946] Frueh BR, Musch DC, Bersani TA. Effects of eyelid protractor excision for the treatment of benign essential blepharospasm. *Am J Ophthalmol* 1992;113:681–6.
- [947] Arthurs B, Flanders M, Codere F, Gauthier S, Dresner S, Stone L. Treatment of blepharospasm with medication, surgery and type A botulinum toxin. *Can J Ophthalmol* 1987;22:24–8.
- [948] Gillum WN, Anderson RL. Blepharospasm surgery. An anatomical approach. *Arch Ophthalmol* 1981;99:1056–62.
- [949] Silveira-Moriyama L, Goncalves LR, Chien HF, Barbosa ER. Botulinum toxin A in the treatment of blepharospasm: a 10-year experience. *Arq Neuropsiquiatr* 2005;63:221–4.
- [950] Goebbels M. Tear secretion and tear film function in insulin dependent diabetics. *Br J Ophthalmol* 2000;84:19–21.
- [951] Lv S, Cheng J, Sun A, Li J, Wang W, Guan G, et al. Mesenchymal stem cells transplantation ameliorates glomerular injury in streptozotocin-induced diabetic nephropathy in rats via inhibiting oxidative stress. *Diabetes Res Clin Pract* 2014;104:143–54.
- [952] Dogru M, Katakami C, Inoue M. Tear function and ocular surface changes in noninsulin-dependent diabetes mellitus. *Ophthalmology* 2001;108:586–92.
- [953] Eagle Jr RC, Font RL, Fine BS. The basement membrane exfoliation syndrome. *Arch Ophthalmol* 1979;97:510–5.
- [954] Roh YB, Ishibashi T, Ito N, Inomata H. Alteration of microfibrils in the conjunctiva of patients with exfoliation syndrome. *Arch Ophthalmol* 1987;105:978–82.
- [955] Kozobolis VP, Detorakis ET, Tsopakis GM, Pallikaris IG. Evaluation of tear secretion and tear film stability in pseudoexfoliation syndrome. *Acta Ophthalmol Scand* 1999;77:406–9.
- [956] Kozobolis VP, Christodoulakis EV, Naoumidis II, Siganos CS, Detorakis ET, Pallikaris LG. Study of conjunctival goblet cell morphology and tear film stability in pseudoexfoliation syndrome. *Graefes Arch Clin Exp Ophthalmol* 2004;42:478–83.
- [957] Arita R, Itoh K, Inoue K, Kuchiba A, Yamaguchi T, Amano S. Contact lens wear is associated with decrease of meibomian glands. *Ophthalmology* 2009;116:379–84.
- [958] Den S, Shimizu K, Ikeda T, Tsubota K, Shimmura S, Shimazaki J. Association between meibomian gland changes and aging, sex, or tear function. *Cornea* 2006;25:651–5.
- [959] Arita R, Itoh K, Inoue K, Amano S. Noncontact infrared meibography to document age-related changes of the meibomian glands in a normal population. *Ophthalmology* 2008;115:911–5.
- [960] Nien CJ, Massei S, Lin G, Nabavi C, Tao J, Brown DJ, et al. Effects of age and dysfunction on human meibomian glands. *Arch Ophthalmol* 2011;129:842–9.
- [961] Sullivan DA, Sullivan BD, Ullman MD, Rocha EM, Krenzer KL, Cermak JM, et al. Androgen influence on the meibomian gland. *Investig Ophthalmol Vis Sci* 2000;41:3732–42.
- [962] Worda C, Nepp J, Huber JC, Sator MO. Treatment of keratoconjunctivitis sicca with topical androgen. *Maturitas* 2001;37:209–12.
- [963] Henriquez AS, Korb DR. Meibomian glands and contact lens wear. *Br J Ophthalmol* 1981;65:108–11.
- [964] Korb DR, Henriquez AS. Meibomian gland dysfunction and contact lens

- intolerance. *J Am Optom Assoc* 1980;51:243–51.
- [965] Mathers WD. Ocular evaporation in meibomian gland dysfunction and dry eye. *Ophthalmology* 1993;100:347–51.
- [966] McCulley JP, Dougherty JM, Deneau DG. Classification of chronic blepharitis. *Ophthalmology* 1982;89:1173–80.
- [967] Jung JW, Park SY, Kim JS, Kim EK, Seo KY, Kim TI. Analysis of Factors Associated With the Tear Film Lipid Layer Thickness in Normal Eyes and Patients With Dry Eye Syndrome. *Investig Ophthalmol Vis Sci* 2016;57:4076–83.
- [968] Bron AJ, Tiffany JM, Gouveia SM, Yokoi N, Voon LW. Functional aspects of the tear film lipid layer. *Exp Eye Res* 2004;78:347–60.
- [969] Heiligenhaus A, Koch JM, Kemper D, Kruse FE, Waubke TN. [Therapy of dry eye disorders]. *Klin Monbl Augenheilkd* 1994;204:162–8.
- [970] Nichols KK, Foulks GN, Bron AJ, et al. The international workshop on meibomian gland dysfunction: executive summary. *Investig Ophthalmol Vis Sci* 2011;52:1922–9.
- [971] Chhadva P, McClellan AL, Alabiad CR, Feuer WJ, Batawi H, Galor A. Impact of Eyelid Laxity on Symptoms and Signs of Dry Eye Disease. *Cornea* 2016;35:531–5.
- [972] McCulley JP, Sciallis GF. Meibomian keratoconjunctivitis. *Am J Ophthalmol* 1977;84:788–93.
- [973] Jester JV, Nicolaides N, Smith RE. Meibomian gland dysfunction. I. Keratin protein expression in normal human and rabbit meibomian glands. *Investig Ophthalmol Vis Sci* 1989;30:927–35.
- [974] Ong BL, Hodson SA, Wigham T, Miller F, Larke JR. Evidence for keratin proteins in normal and abnormal human meibomian fluids. *Curr Eye Res* 1991;10:1113–9.
- [975] Borchman D, Foulks GN, Yappert MC, et al. Human meibum lipid conformation and thermodynamic changes with meibomian-gland dysfunction. *Investig Ophthalmol Vis Sci* 2011;52:3805–17.
- [976] Straatsma BR. Cystic degeneration of the meibomian glands. *AMA Arch Ophthalmol* 1959;61:918–27.
- [977] Olami Y, Zajicek G, Cogan M, Gnessin H, Pe'er J. Turnover and migration of meibomian gland cells in rats' eyelids. *Ophthalmic Res* 2001;33:170–5.
- [978] Pult H, Riede-Pult BH, Nichols JJ. Relation between upper and lower lids' meibomian gland morphology, tear film, and dry eye. *Optom Vis Sci* 2012;89:E310–5.
- [979] Yin Y, Gong L. Uneven Meibomian Gland Dropout Over the Tarsal Plate and its Correlation With Meibomian Gland Dysfunction. *Cornea* 2015;34:1200–5.
- [980] Finis D, Ackermann P, Pischel N, et al. Evaluation of Meibomian Gland Dysfunction and Local Distribution of Meibomian Gland Atrophy by Non-contact Infrared Meibography. *Curr Eye Res* 2015;40:982–9.
- [981] Ban Y, Shimazaki-Den S, Tsubota K, Shimazaki J. Morphological evaluation of meibomian glands using noncontact infrared meibography. *Ocul Surf* 2013;11:47–53.
- [982] Eom Y, Lee JS, Kang SY, Kim HM, Song JS. Correlation between quantitative measurements of tear film lipid layer thickness and meibomian gland loss in patients with obstructive meibomian gland dysfunction and normal controls. *Am J Ophthalmol* 2013;155:1104–10. e1102.
- [983] Ji YW, Lee J, Lee H, Seo KY, Kim EK, Kim TI. Automated Measurement of Tear Film Dynamics and Lipid Layer Thickness for Assessment of Non-Sjogren Dry Eye Syndrome With Meibomian Gland Dysfunction. *Cornea* 2017;36:176–82.
- [984] Bron AJ, Benjamin L, Snibson GR. Meibomian gland disease. Classification and grading of lid changes. *Eye (Lond)* 1991;5(Pt 4):395–411.
- [985] Matsumoto Y, Shigeno Y, Sato EA, et al. The evaluation of the treatment response in obstructive meibomian gland disease by in vivo laser confocal microscopy. *Graefes Arch Clin Exp Ophthalmol* 2009;247:821–9.
- [986] Mathers WD, Shields WJ, Sachdev MS, Petroll WM, Jester JV. Meibomian gland dysfunction in chronic blepharitis. *Cornea* 1991;10:277–85.
- [987] Arita R, Itoh K, Maeda S, Maeda K, Tomidokoro A, Amano S. Efficacy of diagnostic criteria for the differential diagnosis between obstructive meibomian gland dysfunction and aqueous deficiency dry eye. *Jpn J Ophthalmol* 2010;54:387–91.
- [988] Yokoi N, Mossa F, Tiffany JM, Bron AJ. Assessment of meibomian gland function in dry eye using meibometry. *Arch Ophthalmol* 1999;117:723–9.
- [989] Yokoi N, Takehisa Y, Kinoshita S. Correlation of tear lipid layer interference patterns with the diagnosis and severity of dry eye. *Am J Ophthalmol* 1996;122:818–24.
- [990] Mathers WD, Daley TE. Tear flow and evaporation in patients with and without dry eye. *Ophthalmology* 1996;103:664–9.
- [991] Tomlinson A, Khanal S. Assessment of tear film dynamics: quantification approach. *Ocul Surf* 2005;3:81–95.
- [992] Liernert JP, Tarko L, Uchino M, Christen WG, Schaumberg DA. Long-term Natural History of Dry Eye Disease from the Patient's Perspective. *Ophthalmology* 2016;123:425–33.
- [993] Korb DR, Blackie CA. Meibomian gland diagnostic expressibility: correlation with dry eye symptoms and gland location. *Cornea* 2008;27:1142–7.
- [994] Blackie CA, Solomon JD, Greiner JV, Holmes M, Korb DR. Inner eyelid surface temperature as a function of warm compress methodology. *Optom Vis Sci* 2008;85:675–83.
- [995] Franck C. Fatty layer of the precorneal film in the 'office eye syndrome'. *Acta Ophthalmol (Copenh)* 1991;69:737–43.
- [996] Franck C, Palmvang IB. Break-up time and lissamine green epithelial damage in 'office eye syndrome'. Six-month and one-year follow-up investigations. *Acta Ophthalmol (Copenh)* 1993;71:62–4.
- [997] Fenga C, Aragona P, Di Nola C, Spinella R. Comparison of ocular surface disease index and tear osmolarity as markers of ocular surface dysfunction in video terminal display workers. *Am J Ophthalmol* 2014;158:41–8. e42.
- [998] Schlote T, Kadner G, Freudenthaler N. Marked reduction and distinct patterns of eye blinking in patients with moderately dry eyes during video display terminal use. *Graefes Arch Clin Exp Ophthalmol* 2004;242:306–12.
- [999] Tung CI, Perin AF, Gumus K, Pflugfelder SC. Tear meniscus dimensions in tear dysfunction and their correlation with clinical parameters. *Am J Ophthalmol* 2014;157:301–10. e301.
- [1000] Yokoi N, Komuro A. Non-invasive methods of assessing the tear film. *Exp Eye Res* 2004;78:399–407.
- [1001] Ibrahim OM, Dogru M, Takano Y, et al. Application of visante optical coherence tomography tear meniscus height measurement in the diagnosis of dry eye disease. *Ophthalmology* 2010;117:1923–9.
- [1002] Arita R, Morishige N, Shirakawa R, Sato Y, Amano S. Effects of Eyelid Warming Devices on Tear Film Parameters in Normal Subjects and Patients with Meibomian Gland Dysfunction. *Ocul Surf* 2015;13:321–30.
- [1003] Fu YA. Ocular manifestation of polychlorinated biphenyls intoxication. *Am J Ind Med* 1984;5:127–32.
- [1004] McCulley JP, Shine WE. Meibomian secretions in chronic blepharitis. *Adv Exp Med Biol* 1998;438:319–26.
- [1005] Auw-Haedrich C, Reinhard T. Chronic blepharitis. Pathogenesis, clinical features, and therapy. *Ophthalmology* 2007;104:817–26. quiz 827–818.
- [1006] Kaercher T, Brewitt H. Blepharitis. *Ophthalmologie* 2004;101:1135–47. quiz 1148.
- [1007] McCulley JP, Dougherty JM. Bacterial aspects of chronic blepharitis. *Trans Ophthalmol Soc U. K* 1986;105(Pt 3):314–8.
- [1008] Dougherty JM, McCulley JP. Analysis of the free fatty acid component of meibomian secretions in chronic blepharitis. *Investig Ophthalmol Vis Sci* 1986;27:52–6.
- [1009] Bron AJ, Tiffany JM. The meibomian glands and tear film lipids. Structure, function, and control. *Adv Exp Med Biol* 1998;438:281–95.
- [1010] Watters GA, Turnbull PR, Swift S, Petty A, Craig JP. Ocular surface microbiome in meibomian gland dysfunction in Auckland, New Zealand. *Clin Exp Ophthalmol* 2016;45:105–11.
- [1011] Suzuki T, Teramukai S, Kinoshita S. Meibomian glands and ocular surface inflammation. *Ocul Surf* 2015;13:133–49.
- [1012] Czepita D, Kuzna-Grygiel W, Czepita M, Grobelny A. Demodex folliculorum and Demodex brevis as a cause of chronic marginal blepharitis. *Ann Acad Med Stetin* 2007;53:63–7. discussion 67.
- [1013] Lacey N, Kavanagh K, Tseng SC. Under the lash: Demodex mites in human diseases. *Biochem (Lond)* 2009;31:2–6.
- [1014] Ng A, Bitton E, et al. Demodex infestation of the eyelash. *Contact Lens Spectr* 2014;29:36–41.
- [1015] Gao YY, Di Pascuale MA, Li W, et al. High prevalence of Demodex in eyelashes with cylindrical dandruff. *Investig Ophthalmol Vis Sci* 2005;46:3089–94.
- [1016] Randon M, Liang H, El Hamdaoui M, et al. In vivo confocal microscopy as a novel and reliable tool for the diagnosis of Demodex eyelid infestation. *Br J Ophthalmol* 2015;99:336–41.
- [1017] Geerling G, Tauber J, Baudouin C, et al. The international workshop on meibomian gland dysfunction: report of the subcommittee on management and treatment of meibomian gland dysfunction. *Investig Ophthalmol Vis Sci* 2011;52:2050–64.
- [1018] Cheng AM, Sheha H, Tseng SC. Recent advances on ocular Demodex infestation. *Curr Opin Ophthalmol* 2015;26:295–300.
- [1019] Bron AJ, Mengher LS. Congenital deficiency of meibomian glands. *Br J Ophthalmol* 1987;71:312–4.
- [1020] Erickson RP, Dagenais SL, Caulder MS, et al. Clinical heterogeneity in lymphoedema-distichiasis with FOXC2 truncating mutations. *J Med Genet* 2001;38:761–6.
- [1021] Narayanan S, Miller WL, McDermott AM. Expression of human beta-defensins in conjunctival epithelium: relevance to dry eye disease. *Investig Ophthalmol Vis Sci* 2003;44:3795–801.
- [1022] Di Iorio E, Kaye SB, Ponzin D, et al. Limbal stem cell deficiency and ocular phenotype in ectrodactyly-ectodermal dysplasia-clefting syndrome caused by p63 mutations. *Ophthalmology* 2012;119:74–83.
- [1023] Lin AN, Murphy F, Brodie SE, Carter DM. Review of ophthalmic findings in 204 patients with epidermolysis bullosa. *Am J Ophthalmol* 1994;118:384–90.
- [1024] Fine JD, Eady RA, Bauer EA, et al. The classification of inherited epidermolysis bullosa (EB): Report of the Third International Consensus Meeting on Diagnosis and Classification of EB. *J Am Acad Dermatol* 2008;58:931–50.
- [1025] McDonnell PJ, Schofield OM, Spalton DJ, Eady RA. Eye involvement in junctional epidermolysis bullosa. *Arch Ophthalmol* 1989;107:1635–7.
- [1026] McDonnell PJ, Schofield OM, Spalton DJ, Mayou BJ, Eady RA. The eye in dystrophic epidermolysis bullosa: clinical and immunopathological findings. *Eye (Lond)* 1989;3(Pt 1):79–83.
- [1027] McDonnell PJ, Spalton DJ. The ocular signs and complications of epidermolysis bullosa. *J R Soc Med* 1988;81:576–8.
- [1028] Zierhut M, Thiel HJ, Weidle EG, Steuhl KP, Sonnichsen K, Schaumberg-Lever G. Ocular involvement in epidermolysis bullosa acquisita. *Arch Ophthalmol* 1989;107:398–401.

- [1029] Tong L, Hodgkins PR, Denyer J, et al. The eye in epidermolysis bullosa. *Br J Ophthalmol* 1999;83:323–6.
- [1030] Jones SM, Smith KA, Jain M, Mellerio JE, Martinez A, Nischal KK. The Frequency of Signs of Meibomian Gland Dysfunction in Children with Epidermolysis Bullosa. *Ophthalmology* 2016;123:991–9.
- [1031] Kiritsi D, Has C, Bruckner-Tuderman L. Laminin 332 in junctional epidermolysis bullosa. *Cell Adh Migr* 2013;7:135–41.
- [1032] Adamis AP, Schein OD, Kenyon KR. Anterior corneal disease of epidermolysis bullosa simplex. *Arch Ophthalmol* 1993;111:499–502.
- [1033] Gans LA. Eye lesions of epidermolysis bullosa. Clinical features, management, and prognosis. *Arch Dermatol* 1988;124:762–4.
- [1034] Fine JD, Johnson LB, Weiner M, et al. Eye involvement in inherited epidermolysis bullosa: experience of the National Epidermolysis Bullosa Registry. *Am J Ophthalmol* 2004;138:254–62.
- [1035] Fong K, Takeichi T, Liu L, et al. Ichthyosis follicularis, atrichia, and photophobia syndrome associated with a new mutation in MBTPS2. *Clin Exp Dermatol* 2015;40:529–32.
- [1036] Eramo LR, Esterly NB, Zieserl EJ, Stock EL, Herrmann J. Ichthyosis follicularis with alopecia and photophobia. *Arch Dermatol* 1985;121:1167–74.
- [1037] Keyvani K, Paulus W, Traupe H, et al. Ichthyosis follicularis, alopecia, and photophobia (IFAP) syndrome: clinical and neuropathological observations in a 33-year-old man. *Am J Med Genet* 1998;78:371–7.
- [1038] Cursiefen C, Schlotzer-Schrehardt U, Holbach LM, Pfeiffer RA, Naumann GO. Ocular findings in ichthyosis follicularis, atrichia, and photophobia syndrome. *Arch Ophthalmol* 1999;117:681–4.
- [1039] Macleod J. Three cases of "ichthyosis follicularis" associated with baldness. *Br J Dermatol* 1909;21:165–89.
- [1040] Oeffner F, Martinez F, Schaffer J, et al. Intronic mutations affecting splicing of MBTPS2 cause ichthyosis follicularis, alopecia and photophobia (IFAP) syndrome. *Exp Dermatol* 2011;20:447–9.
- [1041] Oeffner F, Fischer G, Happle R, et al. IFAP syndrome is caused by deficiency in MBTPS2, an intramembrane zinc metalloprotease essential for cholesterol homeostasis and ER stress response. *Am J Hum Genet* 2009;84:459–67.
- [1042] Aten E, Brasz LC, Bornholdt D, et al. Keratosis Follicularis Spinulosa Decalvans is caused by mutations in MBTPS2. *Hum Mutat* 2010;31:1125–33.
- [1043] Kymionis GD, Klados NE, Kontadakis GA, Mikropoulos DG. Treatment of superior limbic keratoconjunctivitis with topical tacrolimus 0.03% ointment. *Cornea* 2013;32:1499–501.
- [1044] Kymionis GD, Plaka A, Kontadakis GA, Astyrakakis N. Treatment of corneal dellen with a large diameter soft contact lens. *Cont Lens Anterior Eye* 2011;34:290–2.
- [1045] Rees TD, Jelks GW. Blepharoplasty and the dry eye syndrome: guidelines for surgery? *Plast Reconstr Surg* 1981;68:249–52.
- [1046] Shah CT, Blount AL, Nguyen EV, Hassan AS. Cranial nerve seven palsy and its influence on meibomian gland function. *Ophthal Plast Reconstr Surg* 2012;28:166–8.
- [1047] Takahashi Y, Kakizaki H. Meibomian Gland Dysfunction in Cranial Nerve VII Palsy. *Ophthal Plast Reconstr Surg* 2015;31:179–81.
- [1048] Wan T, Jin X, Lin L, Xu Y, Zhao Y. Incomplete Blinking May Attribute to the Development of Meibomian Gland Dysfunction. *Curr Eye Res* 2016;41:179–85.
- [1049] Gilbard JP, Farris RL. Ocular surface drying and tear film osmolarity in thyroid eye disease. *Acta Ophthalmol (Copenh)* 1983;61:108–16.
- [1050] Kim YS, Kwak AY, Lee SY, Yoon JS, Jang SY. Meibomian gland dysfunction in Graves' orbitopathy. *Can J Ophthalmol* 2015;50:278–82.
- [1051] Jang SY, Lee SY, Yoon JS. Meibomian gland dysfunction in longstanding prosthetic eye wearers. *Br J Ophthalmol* 2013;97:398–402.
- [1052] Chang M, Lee H, Park MS, Baek S. The clinical characteristics and new classification of sticky eyelid syndrome in East Asian patients. *Acta Ophthalmol* 2014;92:e667–670.
- [1053] Reddy VC, Patel SV, Hodge DO, Leavitt JA. Corneal sensitivity, blink rate, and corneal nerve density in progressive supranuclear palsy and Parkinson disease. *Cornea* 2013;32:631–5.
- [1054] Magalhaes M, Wenning GK, Daniel SE, Quinn NP. Autonomic dysfunction in pathologically confirmed multiple system atrophy and idiopathic Parkinson's disease—a retrospective comparison. *Acta Neurol Scand* 1995;91:98–102.
- [1055] Okun MS, McDonald WM, DeLong MR. Refractory nonmotor symptoms in male patients with Parkinson disease due to testosterone deficiency: a common unrecognized comorbidity. *Arch Neurol* 2002;59:807–11.
- [1056] Mathers WD, Billborough M. Meibomian gland function and giant papillary conjunctivitis. *Am J Ophthalmol* 1992;114:188–92.
- [1057] Bonini S, Bonini S, Schiavone M, Centofanti M, Allansmith MR, Bucci MG. Conjunctival hyperresponsiveness to ocular histamine challenge in patients with vernal conjunctivitis. *J Allergy Clin Immunol* 1992;89:103–7.
- [1058] Ciprandi G, Buscaglia S, Pesce G, et al. Effects of conjunctival hyperosmolar challenge in allergic subjects and normal controls. *Int Arch Allergy Immunol* 1994;104:92–6.
- [1059] Leonardi A, Lanier B. Urban eye allergy syndrome: a new clinical entity? *Curr Med Res Opin* 2008;24:2295–302.
- [1060] Mourao EM, Rosario NA, Silva L, Shimakura SE. Ocular symptoms in nonspecific conjunctival hyperreactivity. *Ann Allergy Asthma Immunol* 2011;107:29–34.
- [1061] Rummenie VT, Matsumoto Y, Dogru M, et al. Tear cytokine and ocular surface alterations following brief passive cigarette smoke exposure. *Cytokine* 2008;43:200–8.
- [1062] Uchino Y, Kawakita T, Ishii T, Ishii N, Tsubota K. A new mouse model of dry eye disease: oxidative stress affects functional decline in the lacrimal gland. *Cornea* 2012;31(Suppl 1):S63–7.
- [1063] Zheng Q, Ren Y, Reinach PS, et al. Reactive oxygen species activated NLRP3 inflammasomes initiate inflammation in hyperosmolarity stressed human corneal epithelial cells and environment-induced dry eye patients. *Exp Eye Res* 2015;134:133–40.
- [1064] Aragona P, Romeo GF, Puzolo D, Micali A, Ferreri G. Impression cytology of the conjunctival epithelium in patients with vernal conjunctivitis. *Eye (Lond)* 1996;10(Pt 1):82–5.
- [1065] Bielory L. Ocular allergy and dry eye syndrome. *Curr Opin Allergy Clin Immunol* 2004;4:421–4.
- [1066] Lemp MA, Crews LA, Bron AJ, Foulks GN, Sullivan BD. Distribution of aqueous-deficient and evaporative dry eye in a clinic-based patient cohort: a retrospective study. *Cornea* 2012;31:472–8.
- [1067] Enriquez-de-Salamanca A, Bonini S, Calonge M. Molecular and cellular biomarkers in dry eye disease and ocular allergy. *Curr Opin Allergy Clin Immunol* 2012;12:523–33.
- [1068] Dogru M, Gunay M, Celik G, Aktas A. Evaluation of the tear film instability in children with allergic diseases. *Cutan Ocul Toxicol* 2016;35:49–52.
- [1069] Toda I, Shimazaki J, Tsubota K. Dry eye with only decreased tear break-up time is sometimes associated with allergic conjunctivitis. *Ophthalmology* 1995;102:302–9.
- [1070] Bonini S, Mantelli F, Moretti C, Lambiase A, Bonini S, Micera A. Itchy-dry eye associated with polycystic ovary syndrome. *Am J Ophthalmol* 2007;143:763–71.
- [1071] Fuchs E, Green H. Regulation of terminal differentiation of cultured human keratinocytes by vitamin A. *Cell* 1981;25:617–25.
- [1072] Checkley W, West Jr KP, Wise RA, et al. Maternal vitamin A supplementation and lung function in offspring. *N Engl J Med* 2010;362:1784–94.
- [1073] Semba RD, de Pee S, Panagides D, Poly O, Bloem MW. Risk factors for xerophthalmia among mothers and their children and for mother-child pairs with xerophthalmia in Cambodia. *Arch Ophthalmol* 2004;122:517–23.
- [1074] Demissie T, Ali A, Mekonen Y, Haider J, Umata M. Magnitude and distribution of vitamin A deficiency in Ethiopia. *Food Nutr Bull* 2010;31:234–41.
- [1075] Sommer A. Xerophthalmia and vitamin A status. *Prog Retin Eye Res* 1998;17:9–31.
- [1076] Hess AF, Kirby DB. The Incidence of Xerophthalmia and Night-Blindness in the United States-A Gauge of Vitamin A Deficiency. *Am J Public Health Nations Health* 1933;23:935–8.
- [1077] Sommer A, Green WR. Goblet cell response to vitamin A treatment for corneal xerophthalmia. *Am J Ophthalmol* 1982;94:213–5.
- [1078] Paton D, Mc LD. Bitot spots. *Am J Ophthalmol* 1960;50:568–74.
- [1079] Rodger FC, Saiduzzafar H, Grover AD, Fazal A. A reappraisal of the ocular lesion known as bitot's spot. *Br J Nutr* 1963;17:475–85.
- [1080] Ferrari G, Vigano M. Images in clinical medicine. Bitot's spot in vitamin A deficiency. *N Engl J Med* 2013;368. e29.
- [1081] Sommer A, Emran N, Tamba T. Vitamin A-responsive punctate keratopathy in xerophthalmia. *Am J Ophthalmol* 1979;87:330–3.
- [1082] Sommer A, Emran N. Tear production in vitamin A-responsive xerophthalmia. *Am J Ophthalmol* 1982;93:84–7.
- [1083] Hatchell DL, Sommer A. Detection of ocular surface abnormalities in experimental vitamin A deficiency. *Arch Ophthalmol* 1984;102:1389–93.
- [1084] Puangrichareon V, Tseng SC. Cytologic evidence of corneal diseases with limbal stem cell deficiency. *Ophthalmology* 1995;102:1476–85.
- [1085] Rao V, Friend J, Thoft RA, Underwood BA, Reddy PR. Conjunctival goblet cells and mitotic rate in children with retinol deficiency and measles. *Arch Ophthalmol* 1987;105:378–80.
- [1086] Kiorpes TC, Kim YC, Wolf G. Stimulation of the synthesis of specific glycoproteins in corneal epithelium by vitamin A. *Exp Eye Res* 1979;28:23–35.
- [1087] Hassell JR, Newsome DA. Vitamin A-induced alterations in corneal and conjunctival epithelial glycoprotein biosynthesis. *Ann N. Y Acad Sci* 1981;359:358–65.
- [1088] Tei M, Spurr-Michaud SJ, Tisdale AS, Gipson IK. Vitamin A deficiency alters the expression of mucin genes by the rat ocular surface epithelium. *Investig Ophthalmol Vis Sci* 2000;41:82–8.
- [1089] Hori Y, Spurr-Michaud SJ, Russo CL, Argueso P, Gipson IK. Effect of retinoic acid on gene expression in human conjunctival epithelium: secretory phospholipase A2 mediates retinoic acid induction of MUC16. *Investig Ophthalmol Vis Sci* 2005;46:4050–61.
- [1090] Kim SW, Seo KY, Rhim T, Kim EK. Effect of retinoic acid on epithelial differentiation and mucin expression in primary human corneal limbal epithelial cells. *Curr Eye Res* 2012;37:33–42.
- [1091] Yamamoto Y, Yokoi N, Higashihara H, et al. Clinical characteristics of short tear film breakup time (BUT) -type dry eye. *Nippon Ganka Gakkai Zasshi* 2012;116:1137–43.
- [1092] Uchino M, Yokoi N, Uchino Y, et al. Prevalence of dry eye disease and its risk factors in visual display terminal users: the Osaka study. *Am J Ophthalmol* 2013;156:759–66.
- [1093] Kawashima M, Uchino M, Yokoi N, et al. Associations between subjective happiness and dry eye disease: a new perspective from the Osaka study. *PLoS One* 2015;10. e0123299.

- [1094] Kawashima M, Uchino M, Yokoi N, et al. The Association between Dry Eye Disease and Physical Activity as well as Sedentary Behavior: Results from the Osaka Study. *J Ophthalmol* 2014;2014:943786.
- [1095] Uchino Y, Uchino M, Yokoi N, et al. Alteration of tear mucin 5AC in office workers using visual display terminals: The Osaka Study. *JAMA Ophthalmol* 2014;132:985–92.
- [1096] Shimazaki-Den S, Iseida H, Dogru M, Shimazaki J. Effects of diquafosol sodium eye drops on tear film stability in short BUT type of dry eye. *Cornea* 2013;32:1120–5.
- [1097] Koh S, Inoue Y, Sugimoto T, Maeda N, Nishida K. Effect of rebamipide ophthalmic suspension on optical quality in the short break-up time type of dry eye. *Cornea* 2013;32:1219–23.
- [1098] Koh S. Clinical utility of 3% diquafosol ophthalmic solution in the treatment of dry eyes. *Clin Ophthalmol* 2015;9:865–72.
- [1099] Munger KL, Levin LI, O'Reilly EJ, Falk KI, Ascherio A. Anti-Epstein-Barr virus antibodies as serological markers of multiple sclerosis: a prospective study among United States military personnel. *Mult Scler* 2011;17:1185–93.
- [1100] Simon KC, O'Reilly EJ, Munger KL, Finerty S, Morgan AJ, Ascherio A. Epstein-Barr virus neutralizing antibody levels and risk of multiple sclerosis. *Mult Scler* 2012;18:1185–7.
- [1101] Ascherio A, Munger KL. EBV and Autoimmunity. *Curr Top Microbiol Immunol* 2015;390:365–85.
- [1102] Pflugfelder SC, Beuerman R, Stern DA. Dry eye and ocular surface disorders. CRC Press; 2004.
- [1103] Kam WR, Liu Y, Ding J, Sullivan DA. Do Cyclosporine A, an IL-1 Receptor Antagonist, Uridine Triphosphate, Rebamipide, and/or Bimatoprost Regulate Human Meibomian Gland Epithelial Cells? *Investig Ophthalmol Vis Sci* 2016;57:4287–94.
- [1104] Sacks EH, Wieczorek R, Jakobiec FA, Knowles 2nd DM. Lymphocytic subpopulations in the normal human conjunctiva. A monoclonal antibody study. *Ophthalmology* 1986;93:1276–83.
- [1105] Sacks E, Rutgers J, Jakobiec FA, Bonetti F, Knowles DM. A comparison of conjunctival and nonocular dendritic cells utilizing new monoclonal antibodies. *Ophthalmology* 1986;93:1089–97.
- [1106] Brissette-Storkus CS, Reynolds SM, Lepisto AJ, Hendricks RL. Identification of a novel macrophage population in the normal mouse corneal stroma. *Investig Ophthalmol Vis Sci* 2002;43:2264–71.
- [1107] Hamrah P, Chen L, Zhang Q, Dana MR. Novel expression of vascular endothelial growth factor receptor (VEGFR)-3 and VEGF-C on corneal dendritic cells. *Am J Pathol* 2003;163:57–68.
- [1108] Hamrah P, Huq SO, Liu Y, Zhang Q, Dana MR. Corneal immunity is mediated by heterogeneous population of antigen-presenting cells. *J Leukoc Biol* 2003;74:172–8.
- [1109] Hamrah P, Liu Y, Zhang Q, Dana MR. Alterations in corneal stromal dendritic cell phenotype and distribution in inflammation. *Arch Ophthalmol* 2003;121:1132–40.
- [1110] Hamrah P, Liu Y, Zhang Q, Dana MR. The corneal stroma is endowed with a significant number of resident dendritic cells. *Investig Ophthalmol Vis Sci* 2003;44:581–9.
- [1111] Hattori T, Chauhan SK, Lee H, et al. Characterization of Langerin-expressing dendritic cell subsets in the normal cornea. *Investig Ophthalmol Vis Sci* 2011;52:4598–604.
- [1112] Shull MM, Ormsby I, Kier AB, et al. Targeted disruption of the mouse transforming growth factor-beta 1 gene results in multifocal inflammatory disease. *Nature* 1992;359:693–9.
- [1113] Brunkow ME, Jeffery EW, Hjerrild KA, et al. Disruption of a new forkhead/winged-helix protein, scurf1n, results in the fatal lymphoproliferative disorder of the scurfy mouse. *Nat Genet* 2001;27:68–73.
- [1114] Sharma R, Zheng L, Guo X, Fu SM, Ju ST, Jarjour WN. Novel animal models for Sjogren's syndrome: expression and transfer of salivary gland dysfunction from regulatory T cell-deficient mice. *J Autoimmun* 2006;27:289–96.
- [1115] Rahimy E, Pitcher III JD, Pangelinan SB, et al. Spontaneous autoimmune dacryoadenitis in aged CD25KO mice. *Am J Pathol* 2010;177:744–53. Epub 2010 Jun 2021.
- [1116] Jabs DA, Prendergast RA. Ocular inflammation in MRL/Mp-lpr/lpr mice. *Investig Ophthalmol Vis Sci* 1991;32:1944–7.
- [1117] Li S, Nikulina K, DeVoss J, et al. Small proline-rich protein 1B (SPRR1B) is a biomarker for squamous metaplasia in dry eye disease. *Investig Ophthalmol Vis Sci* 2008;49:34–41.
- [1118] Vosters JL, Landek-Salgado MA, Yin H, et al. Interleukin-12 induces salivary gland dysfunction in transgenic mice, providing a new model of Sjogren's syndrome. *Arthritis Rheum* 2009;60:3633–41.
- [1119] Cha S, Nagashima H, Brown VB, Peck AB, Humphreys-Beher MG. Two NOD ldd-associated intervals contribute synergistically to the development of autoimmune exocrinopathy (Sjogren's syndrome) on a healthy murine background. *Arthritis Rheum* 2002;46:1390–8.
- [1120] Robinson CP, Yamachika S, Bounous DI, et al. A novel NOD-derived murine model of primary Sjogren's syndrome. *Arthritis Rheum* 1998;41:150–6.
- [1121] You IC, Bian F, Volpe EA, de Paiva CS, Pflugfelder SC. Age-related conjunctival disease in the C57BL/6.NOD-Aec1Aec2 Mouse Model of Sjogren Syndrome develops independent of lacrimal dysfunction. *Investig Ophthalmol Vis Sci* 2015 Mar 10;2015. pii: IOVS-14-15668.
- [1122] Bulosan M, Pauley KM, Yo K, et al. Inflammatory caspases are critical for enhanced cell death in the target tissue of Sjogren's syndrome before disease onset. *Immunol Cell Biol* 2008;87:81–90.
- [1123] Gandhi NB, Su Z, Zhang X, et al. Dendritic cell-derived thombospondin-1 is critical for the generation of the ocular surface Th17 response to desiccating stress. *J Leukoc Biol* 2013;94:1293–301.
- [1124] Tsubota K, Fujita H, Tadano K, et al. Improvement of lacrimal function by topical application of CyA in murine models of Sjogren's syndrome. *Investig Ophthalmol Vis Sci* 2001;42:101–10.
- [1125] Lieberman SM, Kreiger PA, Koretzky GA. Reversible lacrimal gland-protective regulatory T cell dysfunction underlies male-specific autoimmune dacryoadenitis in the nonobese diabetic mouse model of Sjogren syndrome. *Immunology* 2015;145:232–41.
- [1126] da Costa SR, Wu K, Veigh MM, et al. Male NOD mouse external lacrimal glands exhibit profound changes in the exocytotic pathway early in postnatal development. *Exp Eye Res* 2006;82:33–45.
- [1127] D'Alise AM, Auyeung V, Feuerer M, et al. The defect in T-cell regulation in NOD mice is an effect on the T-cell effectors. *Proc Natl Acad Sci USA* 2008;105:19857–62.
- [1128] Skarstein K, Wahren M, Zaura E, Hattori M, Jonsson R. Characterization of T cell receptor repertoire and anti-Ro/SSA autoantibodies in relation to sialadenitis of NOD mice. *Autoimmunity* 1995;22:9–16.
- [1129] Xu H, Zhao Y, Li J, et al. Loss of NHE8 expression impairs ocular surface function in mice. *Am J Physiol Cell Physiol* 2015;308:C79–87.
- [1130] de Paiva CS, Volpe EA, Gandhi NB, et al. Disruption of TGF-beta Signaling Improves Ocular Surface Epithelial Disease in Experimental Autoimmune Keratoconjunctivitis Sicca. *PLoS One* 2011;6. e29017. Epub 2011 Dec 29014.
- [1131] Yamachika S, Nanni JM, Nguyen KH, et al. Excessive synthesis of matrix metalloproteinases in exocrine tissues of NOD mouse models for Sjogren's syndrome. *J Rheumatol* 1998;25:2371–80.
- [1132] Husain-Krautter S, Kramer JM, Li W, Guo B, Rothstein TL. The osteopontin transgenic mouse is a new model for Sjogren's syndrome. *Clin Immunol* 2015;157:30–42.
- [1133] Song XJ, Li DQ, Farley W, et al. Neurturin-deficient mice develop dry eye and keratoconjunctivitis Sicca. *Investig Ophthalmol Vis Sci* 2003;44:4223–9.
- [1134] Kotzin BL, Palmer E. Genetic contributions to lupus-like disease in NZB/NZW mice. *Am J Med* 1988;85:29–31.
- [1135] Gilbard JP, Hanninen LA, Rothman RC, Kenyon KR. Lacrimal gland, cornea, and tear film in the NZB/NZW F1 hybrid mouse. *Curr Eye Res* 1987;6:1237–48.
- [1136] Iwasa A, Arakaki R, Honma N, et al. Aromatase controls Sjogren syndrome-like lesions through monocyte chemotactic protein-1 in target organ and adipose tissue-associated macrophages. *Am J Pathol* 2015;185:151–61.
- [1137] McClellan AJ, Volpe EA, Zhang X, et al. Ocular Surface Disease and Dacryoadenitis in Aging C57BL/6 Mice. *Am J Pathol* 2014;184:631–43.
- [1138] Kojima T, Wakamatsu TH, Dogru M, et al. Age-related dysfunction of the lacrimal gland and oxidative stress: evidence from the Cu,Zn-superoxide dismutase-1 (Sod1) knockout mice. *Am J Pathol* 2012;180:1879–96.
- [1139] Ibrahim OM, Dogru M, Matsumoto Y, et al. Oxidative stress induced age dependent meibomian gland dysfunction in Cu,Zn-superoxide dismutase-1 (Sod1) knockout mice. *PLoS One* 2014;9. e99328.
- [1140] Shim GJ, Warner M, Kim HJ, et al. Aromatase-deficient mice spontaneously develop a lymphoproliferative autoimmune disease resembling Sjogren's syndrome. *Proc Natl Acad Sci U S A* 2004;101:12628–33.
- [1141] Tsau C, Ito M, Gromova A, Hoffman MP, Meech R, Makarenkova HP. Barx2 and Fgf10 regulate ocular glands branching morphogenesis by controlling extracellular matrix remodeling. *Development* 2011;138:3307–17.
- [1142] Horsley V, O'Carroll D, Tooze R, et al. Blimp1 defines a progenitor population that governs cellular input to the sebaceous gland. *Cell* 2006;126:597–609.
- [1143] House JS, Zhu S, Ranjan R, Linder K, Smart RC. C/EBPalpha and C/EBPbeta are required for Sebocyte differentiation and stratified squamous differentiation in adult mouse skin. *PLoS One* 2010;5. e9337.
- [1144] Mauris J, Dieckow J, Schob S, et al. Loss of CD147 results in impaired epithelial cell differentiation and malformation of the meibomian gland. *Cell Death Dis* 2015;6. e1726.
- [1145] Cui CY, Smith JA, Schlessinger D, Chan CC. X-linked anhidrotic ectodermal dysplasia disruption yields a mouse model for ocular surface disease and resultant blindness. *Am J Pathol* 2005;167:89–95.
- [1146] Kuramoto T, Yokoe M, Hashimoto R, Hiai H, Serikawa T. A rat model of hypohidrotic ectodermal dysplasia carries a missense mutation in the Edaradd gene. *BMC Genet* 2011;12:91.
- [1147] Naito A, Yoshida H, Nishioka E, et al. TRAF6-deficient mice display hypohidrotic ectodermal dysplasia. *Proc Natl Acad Sci U S A* 2002;99:8766–71.
- [1148] Kenchegowda D, Swamynathan S, Gupta D, Wan H, Whitsett J, Swamynathan SK. Conditional disruption of mouse Klf5 results in defective eyelids with malformed meibomian glands, abnormal cornea and loss of conjunctival goblet cells. *Dev Biol* 2011;356:5–18.
- [1149] Meng Q, Mongan M, Carreira V, et al. Eyelid closure in embryogenesis is required for ocular adnexa development. *Investig Ophthalmol Vis Sci* 2014;55:7652–61.
- [1150] Thiboutot D, Sivarajah A, Gilliland K, Cong Z, Clawson G. The melanocortin 5 receptor is expressed in human sebaceous glands and rat preputial cells. *J Invest Dermatol* 2000;115:614–9.
- [1151] Huang J, Dattilo LK, Rajagopal R, et al. FGF-regulated BMP signaling is

- required for eyelid closure and to specify conjunctival epithelial cell fate. *Development* 2009;136:1741–50.
- [1152] Miyazaki M, Man WC, Ntambi JM. Targeted disruption of stearoyl-CoA desaturase1 gene in mice causes atrophy of sebaceous and meibomian glands and depletion of wax esters in the eyelid. *J Nutr* 2001;131:2260–8.
- [1153] Dahlhoff M, Camera E, Schafer M, et al. Sebaceous lipids are essential for water repulsion, protection against UVB-induced apoptosis and ocular integrity in mice. *Development* 2016;143:1823–31.
- [1154] Hayashi Y, Liu CY, Jester JJ, et al. Excess biglycan causes eyelid malformation by perturbing muscle development and TGF-alpha signaling. *Dev Biol* 2005;277:222–34.
- [1155] Zouboulis CC, Boschnakow A. Chronological ageing and photoageing of the human sebaceous gland. *Clin Exp Dermatol* 2001;26:600–7.
- [1156] Chang SH, Jobling S, Brennan K, Headon DJ. Enhanced Edar signalling has pleiotropic effects on craniofacial and cutaneous glands. *PLoS One* 2009;4:e7591.
- [1157] Cui CY, Durmowicz M, Ottolenghi C, et al. Inducible mEDA-A1 transgene mediates sebaceous gland hyperplasia and differential formation of two types of mouse hair follicles. *Hum Mol Genet* 2003;12:2931–40.
- [1158] Jong MC, Gijbels MJ, Dahlmans VE, et al. Hyperlipidemia and cutaneous abnormalities in transgenic mice overexpressing human apolipoprotein C1. *J Clin Invest* 1998;101:145–52.
- [1159] Plikus M, Wang WP, Liu J, Wang X, Jiang TX, Chuong CM. Morpho-regulation of ectodermal organs: integument pathology and phenotypic variations in K14-Noggin engineered mice through modulation of bone morphogenic protein pathway. *Am J Pathol* 2004;164:1099–114.
- [1160] Dong F, Liu CY, Yuan Y, et al. Perturbed meibomian gland and tarsal plate morphogenesis by excess TGAlpha in eyelid stroma. *Dev Biol* 2015;406:147–57.
- [1161] Cascallana JL, Bravo A, Donet E, et al. Ectoderm-targeted overexpression of the glucocorticoid receptor induces hypohidrotic ectodermal dysplasia. *Endocrinology* 2005;146:2629–38.
- [1162] Kiguchi K, Bol D, Carbajal S, et al. Constitutive expression of erbB2 in epidermis of transgenic mice results in epidermal hyperproliferation and spontaneous skin tumor development. *Oncogene* 2000;19:4243–54.
- [1163] Lin MH, Hsu FF, Miner JH. Requirement of fatty acid transport protein 4 for development, maturation, and function of sebaceous glands in a mouse model of ichthyosis prematurity syndrome. *J Biol Chem* 2013;288:3964–76.
- [1164] Jester JV, Rajagopalan S, Rodrigues M. Meibomian gland changes in the rhino (hrrhhrrh) mouse. *Investig Ophthalmol Vis Sci* 1988;29:1190–4.
- [1165] Park YG, Hayasaka S, Takagishi Y, Inouye M, Okumoto M, Oda S. Histological characteristics of the pelage skin of rough fur mice (C3H/HeJ- ruf/ruf). *Exp Anim* 2001;50:179–82.
- [1166] Hassemel EL, Endres B, Toonen JA, Ronchetti A, Dubielzig R, Sidjanin DJ. ADAM17 transactivates EGFR signaling during embryonic eyelid closure. *Investig Ophthalmol Vis Sci* 2013;54:132–40.
- [1167] Majumder K, Shawlot W, Schuster G, Harrison W, Elder FF, Overbeek PA. YAC rescue of downless locus mutations in mice. *Mamm Genome* 1998;9:863–8.
- [1168] McMahon A, Lu H, Butovich IA. A role for ELOVL4 in the mouse meibomian gland and sebocyte cell biology. *Investig Ophthalmol Vis Sci* 2014;55:2832–40.
- [1169] Toonen J, Liang L, Sidjanin DJ. Waved with open eyelids 2 (woe2) is a novel spontaneous mouse mutation in the protein phosphatase 1, regulatory (inhibitor) subunit 13 like (Ppp1r13l) gene. *BMC Genet* 2012;13:76.
- [1170] Lu Q, Xin Y, Ye F, Foulks G, Li Q. 14-3-3sigma controls corneal epithelium homeostasis and wound healing. *Investig Ophthalmol Vis Sci* 2011;52:2389–96.
- [1171] Chan CC, Gery I, Kohn LD, Nussenblatt RB, Mozes E, Singer DS. Periocular inflammation in mice with experimental systemic lupus erythematosus. A new experimental blepharitis and its modulation. *J Immunol* 1995;154:4830–5.
- [1172] Parfitt GJ, Xie Y, Geyfman M, Brown DJ, Jester JV. Absence of ductal hyperkeratinization in mouse age-related meibomian gland dysfunction (ARMGD). *Ageing (Albany NY)* 2013;5:825–34.
- [1173] Tanaka H, Harauma A, Takimoto M, Moriguchi T. Association between very long chain fatty acids in the meibomian gland and dry eye resulting from n-3 fatty acid deficiency. *Prostagl Leukot Essent Fat Acids* 2015;97:1–6.
- [1174] Zhang X, Schaumburg CS, Coursey TG, et al. CD8(+) cells regulate the T helper-17 response in an experimental murine model of Sjogren syndrome. *Mucosal Immunol* 2014;7:417–27.
- [1175] Kawasaki S, Kawamoto S, Yokoi N, et al. Up-regulated gene expression in the conjunctival epithelium of patients with Sjogren's syndrome. *Exp Eye Res* 2003;77:17–26.
- [1176] Jones DT, Monroy D, Ji Z, Pflugfelder SC. Alterations of ocular surface gene expression in Sjogren's syndrome. *Adv Exp Med Biol* 1998;438:533–6.
- [1177] Jones DT, Monroy D, Ji Z, Atherton SS, Pflugfelder SC. Sjogren's syndrome: cytokine and Epstein-Barr viral gene expression within the conjunctival epithelium. *Investig Ophthalmol Vis Sci* 1994;35:3493–504.
- [1178] Zhang C, Xi L, Zhao S, et al. Interleukin-1beta and tumour necrosis factor-alpha levels in conjunctiva of diabetic patients with symptomatic moderate dry eye: case-control study. *BMJ Open* 2016;6:e010979.
- [1179] Narayanan S, Miller WL, McDermott AM. Conjunctival cytokine expression in symptomatic moderate dry eye subjects. *Investig Ophthalmol Vis Sci* 2006;47:2445–50.
- [1180] Pflugfelder SC, Jones D, Ji Z, Afonso A, Monroy D. Altered cytokine balance in the tear fluid and conjunctiva of patients with Sjogren's syndrome keratoconjunctivitis sicca. *Curr Eye Res* 1999;19:201–11.
- [1181] Epstein SP, Galaria-Rathod N, Wei Y, Maguire MG, Asbell PA. HLA-DR expression as a biomarker of inflammation for multicenter clinical trials of ocular surface disease. *Exp Eye Res* 2013;111:95–104.
- [1182] Baudouin C, Brignole F, Pisella PJ, De Jean MS, Goguel A. Flow cytometric analysis of the inflammatory marker HLA DR in dry eye syndrome: results from 12 months of randomized treatment with topical cyclosporin A. *Adv Exp Med Biol* 2002;506:761–9.
- [1183] Brignole F, Pisella PJ, De Saint JM, Goldschild M, Goguel A, Baudouin C. Flow cytometric analysis of inflammatory markers in KCS: 6-month treatment with topical cyclosporin A. *Investig Ophthalmol Vis Sci* 2001;42:90–5.
- [1184] Brignole F, Pisella PJ, Goldschild M, De Saint JM, Goguel A, Baudouin C. Flow cytometric analysis of inflammatory markers in conjunctival epithelial cells of patients with dry eyes. *Investig Ophthalmol Vis Sci* 2000;41:1356–63.
- [1185] Sheppard Jr JD, Singh R, McClellan AJ, et al. Long-term Supplementation With n-6 and n-3 PUFAs Improves Moderate-to-Severe Keratoconjunctivitis Sicca: A Randomized Double-Blind Clinical Trial. *Cornea* 2013;32:1297–304.
- [1186] Tsubota K, Fukagawa K, Fujihara T, et al. Regulation of human leukocyte antigen expression in human conjunctival epithelium. *Investig Ophthalmol Vis Sci* 1999;40:28–34.
- [1187] Tsubota K, Fujihara T, Saito K, Takeuchi T. Conjunctival epithelium expression of HLA-DR in dry eye patients. *Ophthalmologica* 1999;213:16–9.
- [1188] Rolando M, Barabino S, Mingari C, Moretti S, Giuffrida S, Calabria G. Distribution of Conjunctival HLA-DR Expression and the Pathogenesis of Damage in Early Dry Eyes. *Cornea* 2005;24:951–4.
- [1189] Kunert KS, Tisdale AS, Stern ME, Smith JA, Gipson IK. Analysis of topical cyclosporine treatment of patients with dry eye syndrome: effect on conjunctival lymphocytes. *Arch Ophthalmol* 2000;118:1489–96.
- [1190] Baudouin C, Liang H, Bremond-Gignac D, et al. CCR 4 and CCR 5 expression in conjunctival specimens as differential markers of T(H)1/T(H)2 in ocular surface disorders. *J Allergy Clin Immunol* 2005;116:614–9.
- [1191] Versura P, Profazio V, Schiavi C, Campos EC. Hyperosmolar stress upregulates HLA-DR expression in human conjunctival epithelium in dry eye patients and in vitro models. *Investig Ophthalmol Vis Sci* 2011;52:5488–96.
- [1192] Yoon KC, Park CS, You IC, et al. Expression of CXCL9, -10, -11, and CXCR3 in the tear film and ocular surface of patients with dry eye syndrome. *Investig Ophthalmol Vis Sci* 2010;51:643–50.
- [1193] Gurdal C, Genc I, Sarac O, Gonul I, Takmaz T, Can I. Topical cyclosporine in thyroid orbitopathy-related dry eye: clinical findings, conjunctival epithelial apoptosis, and MMP-9 expression. *Curr Eye Res* 2010;35:771–7.
- [1194] Aragona P, Aguennouz M, Rania L, et al. Matrix metalloproteinase 9 and transglutaminase 2 expression at the ocular surface in patients with different forms of dry eye disease. *Ophthalmology* 2015;122:62–71.
- [1195] Wakamatsu TH, Dogru M, Matsumoto Y, et al. Evaluation of lipid oxidative stress status in Sjogren syndrome patients. *Investig Ophthalmol Vis Sci* 2013;54:201–10.
- [1196] Choi W, Lian C, Ying L, et al. Expression of Lipid Peroxidation Markers in the Tear Film and Ocular Surface of Patients with Non-Sjogren Syndrome: Potential Biomarkers for Dry Eye Disease. *Curr Eye Res* 2016;41:1143–9.
- [1197] Cejkova J, Ardan T, Jirsova K, et al. The role of conjunctival epithelial cell xanthine oxidoreductase/xanthine oxidase in oxidative reactions on the ocular surface of dry eye patients with Sjogren's syndrome. *Histol Histopathol* 2007;22:997–1003.
- [1198] Cejkova J, Ardan T, Simonova Z, et al. Decreased expression of antioxidant enzymes in the conjunctival epithelium of dry eye (Sjogren's syndrome) and its possible contribution to the development of ocular surface oxidative injuries. *Histol Histopathol* 2008;23:1477–83.
- [1199] Coursey TG, Henriksson JT, Barbosa FL, de Paiva CS, Pflugfelder SC. Interferon-gamma-induced unfolded protein response in conjunctival goblet cells as a cause of mucin deficiency in sjogren syndrome. *Am J Pathol* 2016. S0002-9440:30005-30000.
- [1200] Narayanan S, Miller WL, McDermott AM. Expression of human beta-defensins in conjunctival epithelium: relevance to dry eye disease. *Investig Ophthalmol Vis Sci* 2003;44:3795–801.
- [1201] Krenzer KL, Cermak JM, Tolls DB, Papas AS, Dana MR, Sullivan DA. Comparative signs and symptoms of dry eye in primary and secondary Sjogren's syndrome and meibomian gland disease. *Investig Ophthalmol Vis Sci* 2000;40. S2864 (Abstract).
- [1202] <http://www.genecards.org/>.
- [1203] Tejera P, O'Mahony DS, Owen CA, Wei Y, Wang Z, Gupta K, et al. Functional characterization of polymorphisms in the peptidase inhibitor 3 (elafin) gene and validation of their contribution to risk of acute respiratory distress syndrome. *Am J Respir Cell Mol Biol* 2014;51(2):262–72.
- [1204] Warren HS, Tompkins RG, Moldawer LL, Seok J, Xu W, Mindrinos MN, et al. Mice are not men. *Proc Natl Acad Sci U S A* 2015;112. E345.
- [1205] Sato EH, Ariga H, Sullivan DA. Impact of androgen therapy in Sjogren's



syndrome: hormonal influence on lymphocyte populations and Ia expression in lacrimal glands of MRL/Mp-lpr/lpr mice. *Investig Ophthalmol Vis Sci* 1992;33(8):2537–45.

[1206] Tomlinson A, Bron AJ, Korb DR, Amano S, Paugh JR, Pearce EI, et al. The international workshop on meibomian gland dysfunction: report of the diagnosis subcommittee. *Investig Ophthalmol Vis Sci* 2011;52:2006–49.

[1207] Sullivan DA, Hammitt KM, Schaumberg DA, Sullivan BD, Begley CG, Gjorstrup P, et al. Report of the TFOS/ARVO Symposium on global treatments for dry eye disease: An unmet need. *Ocul Surf* 2012;10:108–16.

[1208] Lambert RW, Smith RE. Pathogenesis of blepharoconjunctivitis complicating 13-cis-retinoic acid (isotretinoin) therapy in a laboratory model. *Investig Ophthalmol Vis Sci* 1988;29:1559–64.

[1209] <http://ir.elevenbio.com/releasedetail.cfm?releaseid=913561>.

[1210] <http://www.pemphigus.org/living-with-pemphigus-pemphigoid/understanding-pemphigus-pemphigoid/>.

[1211] Horwath-Winter J, Berghold A, Schmut O, Floegel I, Solhdju V, Bodner E, et al. Evaluation of the clinical course of dry eye syndrome. *Arch Ophthalmol* 2003;121:1364–8.

[1212] Schaumberg DA, Nichols JJ, Papas EB, Tong L, Uchino M, Nichols KK. The international workshop on meibomian gland dysfunction: report of the subcommittee on the epidemiology of, and associated risk factors for, MGD. *Investig Ophthalmol Vis Sci* 2011;52:1994–2005.

[1213] Choi W, Lee JB, Cui L, Li Y, Li Z, Choi JS, et al. Therapeutic efficacy of topically applied antioxidant medicinal plant extracts in a mouse model of experimental dry eye. *Oxid Med Cell Longev* 2016;2016:4727415.

[1214] She Y, Li J, Xiao B, Lu H, Liu H, Simmons PA, et al. Evaluation of a novel artificial tear in the prevention and treatment of dry eye in an animal model. *J Ocul Pharmacol Ther* 2015 Nov;31(9):525–30.

[1215] Wang YC, Li S, Chen X, Ma B, He H, Liu T, et al. Meibomian gland absence related dry eye in ectodysplasin a mutant mice. *Am J Pathol* 2016 Jan;186(1):32–42.

[1216] Ding J, Sullivan DA. Aging and dry eye disease. *Exp Gerontol* 2012;47:483–90.

[1217] Lim SY, Raftery M, Cai H, Hsu K, Yan WX, Hseih HL, et al. S-nitrosylated S100A8: novel anti-inflammatory properties. *J Immunol* 2008;181:5627–36.

[1218] Okanobo A, Chauhan SK, Dastjerdi MH, Kodati S, Dana R. Efficacy of topical blockade of interleukin-1 in experimental dry eye disease. *Am J Ophthalmol* 2012 Jul;154(1):63–71.

[1219] Pflugfelder SC, Tseng SC, Sanabria O, et al. Evaluation of subjective assessments and objective diagnostic tests for diagnosing tear-film disorders known to cause ocular irritation. *Cornea* 1998;17:38–56.

[1220] Sternberg EM. Neural regulation of innate immunity: a coordinated nonspecific host response to pathogens. *Nat Rev Immunol* 2006 Apr;6(4):318–28.

**TFOS DEWS II Pathophysiology report glossary:**

The glossary has been created by adding new terms to the TFOS DEWS 2007 glossary

**ACR50, ACR70:** indices of physical and joint function developed by the American College of Rheumatology to assess functional performance and limitation due to rheumatic disease

**Ach:** Acetyl choline

**Act-1:** A negative regulator of BAFF and CD40<sup>+</sup>

**ADDE: Aqueous deficient dry eye:** dry eye that is due to decreased secretion of tear fluid from the lacrimal glands

**AIDS:** the immunodeficiency disease produced by the HIV virus that is associated with low levels of immunocompetent lymphocytes, and intercurrent infections

**AIRE:** Autoimmune regulator

**AKC:** atopic keratoconjunctivitis, an allergic condition associated with atopic disease productive of inflammation of the ocular surface

**APC:** Antigen-presenting cell

**ARDE:** Age Related Dry Eye

**APRIL::** Proliferation inducing ligand

**ATD:** Aqueous Tear Deficiency

**ATS:** Artificial Tear Substitute

**BAFF:** B-cell activating factor

**Basal Tears:** Open eye tears secreted under conditions of minimal ocular surface stimulation

**BUT:** Fluorescein break-Up Test

**CALT:** Conjunctiva-associated lymphoid tissue

**CGRP:** Calcitonin gene related peptide (CGRP)

**Challenge clinical trial:** a clinical trial that observes the effect of a treatment or intervention under environmental or activity conditions that stress or challenge a particular physical or mental condition

**CC:** Chemokine prefix

**CIC:** Conjunctival Impression Cytology

**CLEK:** Collaborative Longitudinal Study of Keratoconus

**CAE: Controlled adverse environment:** an environment designed and constructed to provide an environmental challenge to aggravate a clinical condition under study

Cell Type	Marker for-
CD3 <sup>+</sup>	Pan T cell marker
CD45Ro <sup>+</sup>	Memory T cells
CD4 <sup>+</sup>	Helper-inducer T cells
CD8 <sup>+</sup>	Suppressor-cytotoxic T cells
CD20 <sup>+</sup>	B cells
CD25	IL-2 receptor
CD57 <sup>+</sup>	NK - Natural killer cells
CD68 <sup>+</sup>	Macrophages, monocytes
CD <sup>+</sup> 147	EMMPRIN
<i>Cell Phenotype:</i>	
TCRγδ	T cell receptor γδ
HML-1 (Ber-ACT8)	Human mucosal lymphocyte antigen-1
NK	Natural killer cell
NPE	Neutrophils (elastase)
AA-1	Mast cells
EG-1	Eosinophils (cationic protein)

**CCLR:** Centre for Contact Lens Research, University of Waterloo, Ontario

**CPT:** Conjunctival Provocation Test

**CRT:** Carbohydrate recognition domains

**CVS:** computer vision syndrome: the symptoms and signs produced by prolonged use of a videodisplay terminal and computer that results in decreased blink, increased tear instability and symptoms of discomfort and fluctuation in vision

**CPT code:** current procedure terminology that assigns a unique numerical code to procedures performed for conditions listed in the ICD-9 codified disease list

**CXC:** Chemokine prefix

**Declaration of Helsinki:** guidelines promulgated by international agreement that define the ethical conduct of clinical trials and appropriate protection of human subjects

**DEQ:** The Dry Eye Questionnaire.

**DES:** Desiccating stress, animal model of dry eye disease

**DEWS: International Dry Eye Workshop:** the international group conference that collated evidence based information describing the clinical condition of dry eye disease, including clinical, basic and clinical research, epidemiology and management of the condition

**Dsc3:** Desmoglein 3

**DTS: Dysfunctional tear syndrome:** the term recommended by the International Delphi Panel to describe abnormalities of the tear film and the consequences to the ocular surface

**EALT:** Eye-Associated Lymphoid Tissues

**EA-R:** An Epstein Barr early antigen

**EBNA-1:** Passive, latent phase EBV marker

**EBV:** Epstein Barr virus

**EDA:** Ectodermal dysplasia

**EDE:** Evaporative dry eye; also experimental dry eye

**ECP:** Eosinophil Cationic Protein

**EMMPRIN:** Extracellular matrix metalloproteinase inducer

**EMT:** Epithelial-mesenchymal transition

**Environmental clinical trial:** a clinical trial that observes the effect of a treatment or intervention under the ambient environmental conditions present

**EQ-5D:** This is standardized questionnaire for use as a measure of health outcomes

- Equipoise (in clinical research)*: a state of uncertainty regarding whether alternative health care interventions will confer more favorable outcomes, including balance of benefits and harms. Under the principle of equipoise, a patient should be enrolled in a randomized controlled trial only if there is substantial uncertainty, (an expectation for equal likelihood) about which intervention will benefit the patient most
- EDE: Evaporative dry eye**: dry eye that is due to increased evaporation of the tear fluid from the surface of the eye
- ELS**: Ectopic lymphoid structures
- EMMPRIN**: Extracellular matrix metalloproteinase inducer. A membrane-spanning molecule also termed CD<sup>+</sup>147
- EMT**: Epithelial mesenchymal transition
- ERK**: Extracellular signal regulated kinases
- FBUT**: Fluorescein Break-Up Test
- FCT**: Fluorescein Clearance Test. A test of tear turnover; see TCR
- FVA**: Functional Visual Acuity (FVA): a measure of visual acuity during a tightly controlled period of time or environmental circumstance that assesses visual acuity without the subject able to compensate by blinking or adjustment to a visual challenge
- GalNAc**: N-acetyl galactosamine.
- GCP: Good Clinical Practice**: those features of conducting a clinical trial that are accepted as proper methods for conducting a clinical trial
- GVHD: Graft versus Host Disease**: inflammation caused by engrafted immunocompetent cells that recognize as foreign and attack cells of the host
- HCV**: Hepatitis C virus
- HIV**: human immunodeficiency virus, the infective viral agent responsible for producing immunodeficient lymphocytes
- HADS**: Hospital Anxiety and depression Scale: a scale developed to evaluate anxiety and depression
- HSCT**: Allogeneic hematopoietic stem cell transplantation
- HLA**: Human Leukocyte Antigen
- HMG-CoA**: 3-hydroxy-3-methylglutaryl-CoA
- HRT**: hormone replacement therapy: systemic replacement of female sex hormones as a treatment for post-menopausal lack of estrogen and/or other hormones
- HZO**: Herpes Zoster Ophthalmicus
- ICAM-1**: Intercellular adhesion molecule that enables cell-to-cell adhesion. It is often a marker of inflammation
- ICD-9**: International classification of disease that assigns a unique numerical code to each disease
- IDEEL**: impact of dry eye on everyday life: a set of questions framed to determine the level of interference in activities of daily living produced by dry eye disease
- IFAP syndrome**: A disease exhibiting the combination of follicular ichthyosis, alopecia and photophobia
- IFN**: Interferon
- Ig**: Immunoglobulin, eg IgA, IgD, IgG, IgM
- IGF**: Insulin-like growth factor
- IL-**: Interleukin
- Incidence**: the frequency of occurrence of a condition per total unit of population per period of time (eg, x/100,000/yr)
- IRB: Institutional Review Board**: institutional committee of a defined composition that is responsible for the review of the ethical construction and conduct of a clinical trial in compliance with accepted ethical guidelines
- ITT: Intention to treat population**: all subjects randomized in a clinical trial based on the original treatment to which they were assigned, regardless of the treatment they actually received or their adherence to the study protocol
- International Conference on Harmonization**: conference that defined guidelines for ethical conduct of human clinical trials
- J-piece**: A linker protein between the two IgA molecules of dimeric, secretory IgA – (sIgA)
- JNK**: c-Jun N-terminal kinases
- KCS: Keratoconjunctivitis sicca**: the condition of dry eye and inflammation of the ocular surface described by Henrik Sjögren, MD. Now commonly used interchangeably with dry eye syndrome or aqueous-deficient dry eye (ADDE)
- KFSD**: Keratosis Follicularis Spinulosa Decalvans disease
- KIK**: Kallikrein
- La (SSB)**: a specific antigen expressed on cells that is a target for antibodies developed by the immune response in Sjögren's Syndrome
- LEPs**: In relation to keratinization – late envelope proteins
- LFA-1**: Leukocyte functional antigen 1
- LFU**: Lacrimal Functional Unit (LFU): the integrated functional unit comprising the lacrimal system, the ocular surface and its accessory glands and their neural interconnections that is responsible for the maintenance of the tear film and protection of the transparency of the cornea and health of the ocular surface
- LASIK**: laser assisted in-situ keratectomy: the removal of corneal tissue by laser beneath an anterior flap of cornea performed to correct refractive error
- LINE: LASIK Induced Neuro Epitheliopathy**: a term used to describe the symptom complex of ocular irritation and ocular surface abnormalities following LASIK surgery
- LOCF: Last Observation Carried Forward (LOCF)**: a statistical technique to correct for missing information at a data collection point by carrying forward the last clinical observation made prior to the missing data
- Likert score**: A method of grading a subjective symptom or objective sign of disease by use of a categorical scale
- LIPCOF**: Lid Parallel Conjunctival Folds – a form of conjunctivochalasis. Associated with dry eye
- LWE**: Lid wiper epitheliopathy
- M3**: Muscarinic receptor, type 3
- MAP kinase**: Mitogen-Activated Protein kinase
- MALT**: Mucosa-associated lymphoid tissue
- MBI**: Maximum Blink Interval
- MBTBS1/2**: Membrane binding transcription factor proteases, site-1 and 2
- MCJ**: Mucocutaneous junction
- Meibum**: Product expressed from the meibomian glands by pressure applied to the glands through the lids. This is a clear oil in healthy lids and becomes increasingly viscous and opaque in MGD
- MGD**: Meibomian Gland Dysfunction
- MFI**: Multi-dimensional fatigue inventory: a questionnaire that catalogues multiple aspects of symptoms contributing to or associated with fatigue
- MHC**: Major histocompatibility antigens expressed on cells and determining immune recognition in transplantation allograft reaction
- MMP**: Matrix metalloproteinase proteolytic enzymes formed by tissues and inflammatory cells
- MMP**: Also used to refer to Mucous Membrane Pemphigoid
- Mod ITT**: Modified Intent to treat population (Mod ITT): all subjects randomized to a clinical trial who received at least one dose of medication or assigned intervention
- mOsm**: Milliosmoles
- Mucins**: glycoproteins expressed on the ocular surface or secreted into the tear film
- MUC**: Mucins, such as the membrane spanning mucins, MUC1, MUC4 and MUC-16
- MUC5AC**: the gel-forming mucin secreted by the goblet cells of the conjunctiva
- MBTPs**: Membrane binding transcription factor proteases, sites-1 and 2
- MyD88**: Myeloid differentiation primary response 88 gene
- NEI-VFQ: NEI Visual Function Questionnaire**: Questionnaire developed by the National Eye Institute to evaluate vision function in activities of daily life.
- NETs**: Neutrophil Extracellular Traps
- NETosis**: Formation of NETs
- NFKB**: Nuclear factor κB
- NGF**: Nerve growth factor
- NIBUT**: Non-Invasive Break-Up Time or Test
- NK**: Neurotrophic keratitis
- Nocebo**: a treatment or intervention that has no negative direct effect on a condition under treatment
- NOD mouse**: Non obese diabetic mouse
- NPY**: Neuropeptide Y
- NSDE: Non-Sjögren Syndrome-associated Dry Eye**. ADDE that occurs in the absence of Sjögren's Syndrome
- NSATD**: Non-Sjögren's Aqueous tear Deficiency
- OAHFA**: O-acyl-ω-hydroxy-fatty acid (OAHFA)
- OCP**: Ocular cicatricial pemphigoid
- OPI**: Ocular Protection Index, the breakup time divided by the blink interval
- OR**: odds ratio
- OSDI**: Ocular Surface Disease Index: a set of questions assessing the level of discomfort and interference with activities of daily living produced by ocular surface disease. (Developed by Allergan, Inc for evaluation of dry eye disease)
- OSS: Ocular Surface System**: the contiguous epithelia of the ocular surface which are derived embryologically from the same surface epithelia and which are continuous, through ductal epithelia, with the acinar epithelia of the main and accessory lacrimal glands, the meibomian glands and the nasolacrimal system
- OTC**: Over-the-counter
- PCR**: Polymerase chain reaction
- PED**: Persistent epithelial defect
- PG4**: Proteoglycan 4 – Lubricin
- Phenol red thread test**: measurement of tear volume or change in tear volume with time by observation of the amount of wetting of a phenol red dye impregnated cotton thread placed over the inferior eyelid
- PHS: Physicians' Health Study**: a large, prospective, long-term epidemiologic study of a cohort of male physicians in the United States
- Placebo**: a treatment or intervention that has no positive direct effect on a condition under treatment
- PP: Per protocol population**: all subjects randomized to an assigned treatment or intervention who completed the treatment according to protocol
- Predictive value**: the likelihood that a test will reliably predict the presence of a given abnormality in a population
- Prevalence**: the frequency of occurrence of a condition or disease in a cross sectional population sample (eg, x% of an evaluated population)
- PRK**: photorefractive keratectomy: the removal of anterior corneal tissue by laser performed to correct refractive error
- pSS**: Primary Sjögren syndrome
- PTGER**: Prostaglandin E receptor
- QOL**: quality of life: the features of patient comfort and activity that can be influenced by illness or injury
- RAS**: Renin-angiotensin system
- RCT**: randomized clinical trial: a clinical study of two or more treatments or interventions that assigns subjects at random to each of the treatment options
- Regression to the mean**: a statistical finding that with sequential observations, subject scores tend towards the mean of the original sample
- RK**: radial keratotomy: incisions made in a radial pattern about the mid-peripheral cornea to correct myopic refractive error
- Ro (SSA)**: a specific antigen expressed on cells that is a target for antibodies developed by the immune response present in Sjögren's Syndrome

- ROS:** Reactive oxygen species
- SBUDE:** Short breakup time dry eye
- SBUT:** Symptomatic Tear Film Break-Up Time.
- Schirmer test:** a test to measure change in tear volume (production) by the observed wetting of a standardized paper strip placed over the inferior eyelid over a given period of time.
- Schirmer test without anesthetic:** the test is performed without prior instillation of topical anesthesia to the ocular surface
- Schirmer test with anesthetic:** the test is performed after prior instillation of a topical anesthetic to the ocular surface
- SCP:** Scopolamine
- Secretagogue:** an agent that stimulates glandular
- Sensitivity:** the likelihood that a clinical test will detect the presence of a given abnormality in a population
- SF-36:** The 36 item Medical Outcome Study Short-Form: a set of 36 questions that evaluate the level of interference with activities of daily living by a disease
- SGEC:** Salivary gland epithelial cells
- siRNA:** Small interfering RNA
- SJS/TEN:** Stevens-Johnson Syndrome (SJS)/toxic epidermal necrosis
- SLE:** Systemic Lupus Erythematosus
- SLK:** Superior limbic keratoconjunctivitis
- SOD:** Superoxide dysmutase
- SP:** Substance –P
- Specificity:** The likelihood that a clinical test will identify only the given abnormality in a population
- SPRR:** Small proline-rich proteins associated with keratinization
- SREBPs:** Sterol regulatory element binding proteins 1 and 2
- SS:** Sjögren syndrome
- SSATD:** Sjögren Syndrome Aqueous Tear Deficient Dry Eye
- SSDE:** Sjögren Syndrome Aqueous Tear Deficient Dry Eye
- S-TBUD:** Staring Tear Breakup Dynamics
- Surrogate marker:** a marker or parameter of measurement that reflects or correlates with a different parameter of disease or tissue alteration. Surrogate markers may be direct or correlative. Direct surrogate markers are those that derive from the same physical or chemical properties as the primary marker. Correlative surrogate markers are those that correlate with the primary marker but can be produced by other mechanisms as well
- T4 cells:** cytotoxic/suppressor T lymphocytes
- T8 cells:** T helper lymphocytes
- TBUT:** Tear or tear film breakup time. Also, BUT, FBUT and TFBUT. The time to initial breakup of the tear film following a blink
- TCR:** **Tear clearance rate:** the rate at which the precocular tear film or an instilled marker of the tear is removed from the tear film by dilution or drainage from the tear volume
- TFL:** **Tear film lipid layer:** the most anterior layer of the tear film, composed of meibomian lipids that limit evaporation and stabilize the tear film
- TFI:** A test of tear dynamics whose value is obtained by dividing the value of the Schirmer test with anesthesia by the tear clearance rate
- TFI:** Tear Ferning Test-detection of dry eye on the basis of tear ferning patterns
- TGF:** Transforming growth factor
- TIMP:** Tissue inhibitor of metalloproteinases
- TLS:** Tertiary or ectopic lymphoid structures
- TNF:** Tumor necrosis factor
- TLR:** Toll-Like Receptor
- TSAS:** Tear Stability Analyses System
- TSB:** Thrombospondin
- TTR:** Tear turnover rate. Lacrimal flow per minute as a percentage of tear volume. [Bron]
- VDT:** Visual display terminals
- VFQ-25:** NEI-devised Visual Functioning Questionnaire.
- VAS:** **Visual analog scale:** a method of grading a subjective symptom or objective sign of disease by use of a measured linear scale
- VEGF:** Vascular endothelial growth factor
- VKC:** vernal keratoconjunctivitis, an allergic condition manifested by chronic and episodic inflammation of the ocular surface and papillary reaction of the conjunctiva
- VIP:** Vasoactive intestinal peptide
- VT-HRQ:** Vision-Targeted Health-Related Quality of Life: a questionnaire that evaluates QOL activities related to or dependent upon vision
- VNTR:** Variable number of tandem repeats
- WWHS:** Women's Health Study (WHS): a large, prospective, long-term epidemiologic study of a cohort of women in the United States
- XC:** Chemokine prefix
- Xerophthalmia:** A bilateral ocular disease caused by Vitamin A deficiency, characterized by night blindness, xerosis of the ocular surface and keratomalacia