

INSERT TO

# RT

Retina Today

APRIL 2020 VOL. 18, NO. 3

SPONSORED BY



# TOPCON EURETINA 2019

## New Insights and Clinical Applications of Swept-Source OCT and Angiography

This supplement summarizes highlights from a symposium held during the 2019 EURETINA Congress in Paris. Thought leaders in ophthalmology shared their insights on how these imaging technologies are shaping the understanding of retinal disease and proving their utility in clinical practice.

# Use of SS-OCT in CNV Secondary to CSC

Our new view below the RPE is revealing another cause of neovascularization.

BY PEARSE A. KEANE, MD, MSC, FRCOPHTH, MRCSI



With swept-source OCT (SS-OCT), we have amazing visualization of the choroid. We can look beneath the dark carpet of retinal pigment epithelium (RPE) under the retina to see the choroidal scleral junction, structures such as the posterior ciliary arteries, and features of highly myopic eyes such as the orbital fat around the optic nerve. With access to this information, it becomes incumbent upon us as retina specialists to determine the significance of everything we see. As we decipher the data, I think choroidal neovascularization (CNV) secondary to central serous retinopathy is one of the most interesting and challenging topics that we face as medical retina specialists.

## SPECTRUM OF PACHYCHOROID CONDITIONS

In my practice, one of the most common conditions is central serous chorioretinopathy (CSC), which is better viewed as a spectrum of conditions related to pachychoroid. Pachychoroid is a thickened choroid with overlying RPE changes. The spectrum of pachychoroid conditions includes large, dilated, “pachyvesels” that occupy almost the full thickness of the choroid.<sup>1</sup> There is thinning of the overlying inner choroid and overlying RPE changes. Indocyanine green on these patients shows choroidal hyperpermeability.

The range of pachychoroid conditions includes pachychoroid pigment epitheliopathy, CSC, polypoidal choroidal vasculopathy, focal choroidal excavation, and choroidal caverns. In addition, there is pachychoroid neovasculopathy (PNV), which is type 1 sub-RPE neovascularization overlying a localized area of choroidal thickening and dilated choroidal vessels.<sup>1</sup> Patients with this condition often show no signs of drusen or other degenerative changes to suggest age-related macular degeneration (AMD). This may be some form of CNV or macular neovascularization, but it also may be quite different than AMD in how it reacts to intravitreal therapy. Many of these patients are in their 50s, 60s, or early 70s—a bit younger than the typical age for wet AMD.

In the last few years, a colleague and I have been looking at every patient at our hospital who has CNV secondary to CSC. We’re trying to describe the different features we see in that condition and determine how we can better define or diagnose those cases. Although it’s easy to diagnose the problem in patients with a history of the condition, we need guidelines to help doctors make a new diagnosis.

## SIGNS OF EARLY PNV

One early feature of PNV is choroidal thickening. There is type 1 neovascularization overlaid by a fuzzy, hyper-reflective subretinal material. On OCT angiography (OCTA), we typically don’t see neovascularization through this. Five years ago, I would have thought that OCTA would show a classic membrane. Instead, we see fibrinous exudation with subretinal fluid around it in the sub-RPE space.

In a typical case, a 70-year-old man with 20/20 vision in both eyes and an incidental finding of macular changes had a thickened choroid. There was a small RPE detachment, where we suspected a type 1 neovascularization existed, but it was not visible through the hyper-reflective subretinal material (Figure 1). We watched this patient for a few visits. When his vision dropped down to 6/9, we started anti-VEGF treatment, but after five injections, he still had subretinal fluid and the thickened choroid.

In another case, a 69-year-old man decided to have an eye check after his brother was diagnosed with an ocular melanoma. His vision was 6/6. His primary physician referred him to us after noting that he had some subretinal fluid on the 3D OCT. A fluorescein angiogram showed stippled hyperfluorescence, and indocyanine green angiography showed dilated choroidal vessels underneath it (Figure 2). OCT showed an RPE bump with an area of fibrinous exudation in a perifoveal location. After initial close observation, the patient began a short course of intravitreal anti-VEGF therapy.

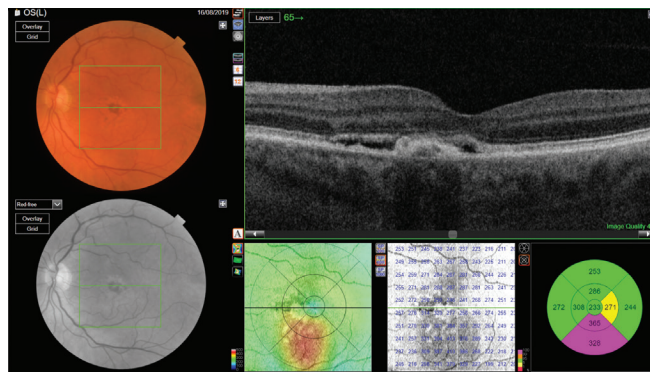


Figure 1. In this typical appearance of early PNV, there is a small RPE detachment, which may be where type 1 neovascularization exists. The neovascularization is covered with fuzzy, hyper-reflective subretinal material.

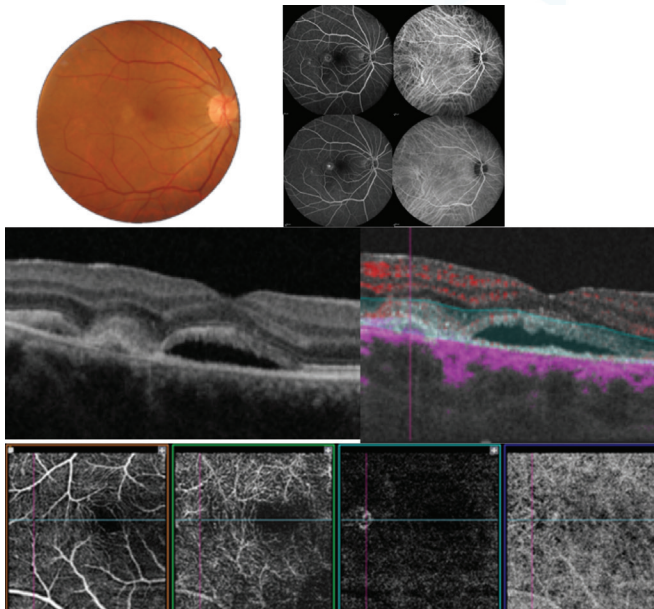


Figure 2. This 69-year-old man's fluorescein angiography shows stippled hyperfluorescence, and on indocyanine green, dilated choroidal vessels can be seen underneath it. OCT shows an RPE bump and an area of fibrinous exudation.

Sometimes, it's a challenge to determine if we should treat a patient who exhibits these signs but has clear vision and no symptoms. If we suspect wet AMD, then the progressive nature of the disease is a strong argument for treatment. If not, we might watch the patient and start treatment if we see any progression. While we suspect that there may be something more in these patients, we don't yet have definitive answers.

### "DOUBLE-LAYER" SIGN

In more advanced cases of PNV, patients often develop something called a "double-layer" sign, a shallow, irregular detachment of the RPE. A type 1 membrane is also typically easy to see on OCTA in these more established cases.

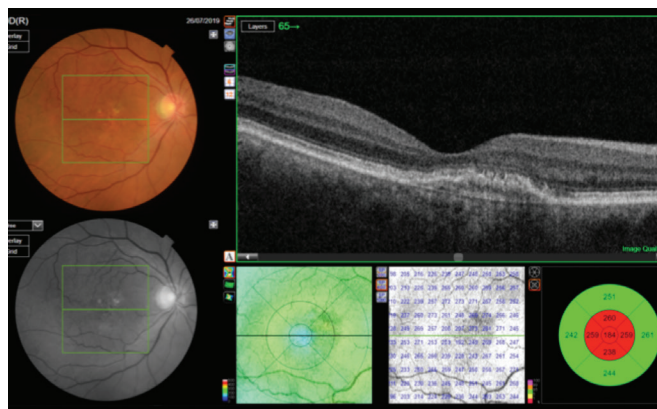


Figure 3. This 74-year-old woman with previously diagnosed CSC has a visible double-layer sign, as well as some subretinal fluid.

We had a case where a 74-year-old woman was diagnosed with CSC nearly 20 years ago, making the new diagnosis relatively easy. She had received multiple steroid injections for osteoarthritis over the past 10 or 15 years, causing eye problems. She was sent to see me when her vision did not improve after cataract surgery. Her vision was 6/12. The double layer sign was evident, as was some subretinal fluid (Figure 3). The type 1 membrane could be seen on OCTA.

We gave the patient a course of anti-VEGF injections, after which her vision was still 6/12. She didn't notice an improvement. We continued to monitor her closely. There is a question of whether the type 1 membrane in patients like this may offer a protective effect against geographic atrophy, but we have to be quite cautious about how we interpret our findings because we don't yet have certain evidence.

It's worth noting that steroid use was clear in this case, but many times we only know about steroid use by taking a proper steroid history. It's useless to ask a patient, "Are you on any steroids?" They always say, "No." We have to ask if they use a nasal inhaler, asthma inhaler, or prescription skin cream, or if they get injections for their joints. Unless we ask in a careful way, we'll miss the history, and we won't treat these patients appropriately.

Another of our patients with known CSC had hypermetropia and 6/5 vision. In 2015, at 64 years old, she had a typical CSC appearance (Figure 4). But at some point after cataract surgery, her primary physician noted the double-layer sign. We did an OCTA and, as we expected, she had a type 1 membrane. She also had an RPE bump and subretinal, fibrinous exudation in a perifoveal location, making the case a mixed picture.

When a patient like this one has had the double-layer sign for some time, she often develops polyps. In one of our cases, a 75-year-old Asian woman with CSC had 6/12 vision in her left eye. She had the double-layer sign and a thick

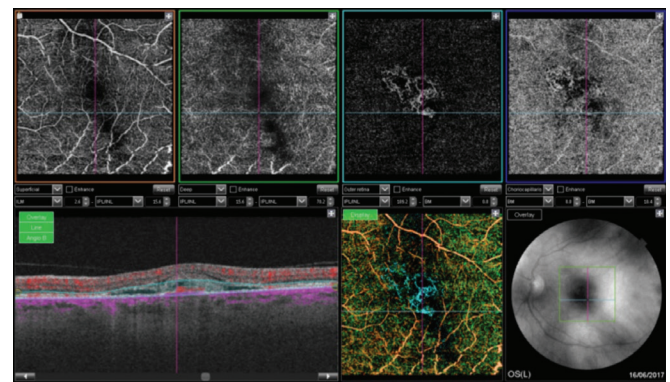


Figure 4. This 64-year-old patient has a typical CSC appearance, as well as the double-layer sign, a type 1 membrane, an RPE bump, and a subretinal, fibrinous exudation in a perifoveal location.

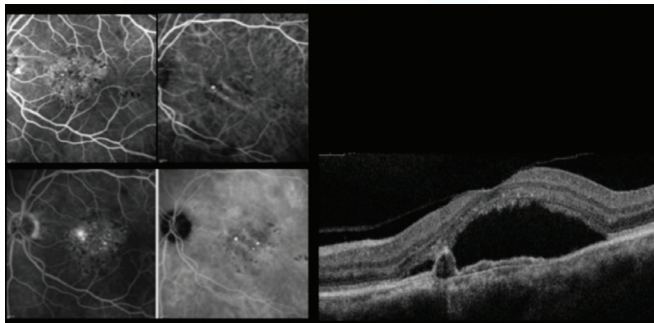


Figure 5. After having the double-layer sign for some time, this patient with chronic CSC developed polyps.

choroid (Figure 5). There was the appearance of subretinal fluid that's suggestive of CSC. We also noted a polyp and the choroidal hyperpermeability consistent with this pachychoroid phenotype.

### PACHYDRUSEN IN CHRONIC CASES

What do we do when we see CSC patients with little RPE detachments that look like drusen? Are they polyps? Are they type 1 neovascularization? What's going on? As it turns out, what we're seeing matches the description of pachydrusen.<sup>2</sup> Pachydrusen typically appears with a distribution that's clustered on the fovea—quite different from what we usually see with AMD.

For example, a 62-year-old Indian man had chronic CSC. His vision was 6/6 left and 6/9 right. At a routine eye exam, his doctor noted shallow RPE detachments. We did an OCTA and saw an established membrane that likely had been there a long time. Perhaps it could remain there without necessarily causing any problems. When the overlying RPE is intact, then in many of these cases we can presume that the photoreceptors are protected to a certain degree. The patient also had a bit of intraretinal fluid. We also saw a lot of small, yellowish, well-demarcated drusen common to pachychoroid phenotypes, which we call pachydrusen (Figure 6).

### AN EVOLVING UNDERSTANDING

With SS-OCT now allowing us to unlock the area under the RPE, we're gaining new information, some of which will

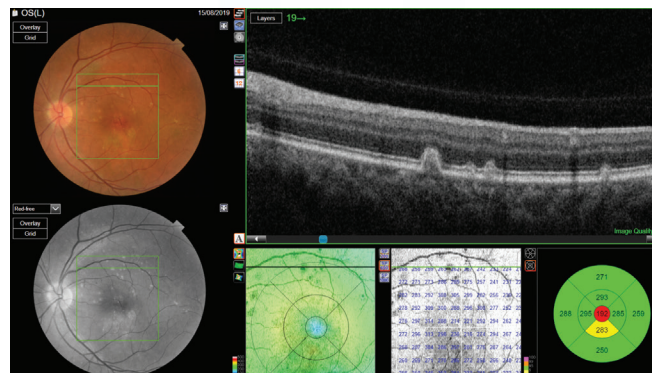


Figure 6. This patient with chronic CSC has a lot of small, yellowish, well-demarcated drusen common to pachychoroid phenotypes, which we call pachydrusen.

no doubt be clinically meaningful. If a patient has CNV secondary to CSC, for example, the case is likely to differ quite significantly in its natural history from CNV due to wet AMD. With new insights from SS-OCT, we are learning the difference and how it should influence treatment, such as an adjunctive therapy to control subretinal fluid.

This is what's exciting about being a medical retina specialist. We're picking up these new variants, seeing that not all CNV is caused by wet AMD. If a patient over 70 has subretinal fluid, it doesn't necessarily mean wet AMD. I recently had a patient from another country who had 70 anti-VEGF injections. She had CSC and not wet AMD. She was thrilled when I told her that we could pause the treatment and begin close observation. It's all part of the evolution of our knowledge. There is overlap between the CSC, the pachychoroid spectrum, and polypoidal choroidal vasculopathy. It will continue to be very interesting for us to disentangle those relationships. ■

### PEARSE A. KEANE, MD, MSc, FRCOPHTH, MRCSI

■ Moorfields Eye Hospital and University College London Institute of Ophthalmology, London

■ pearse.keane1@nhs.net

■ Financial disclosure: Consultant (DeepMind, Novartis, Roche), Speaker (Allergan, Bayer, Heidelberg Engineering, Novartis, Roche, Topcon)

1. Pang CE, Freund KB. Pachychoroid neovascularopathy. *Retina*. 2015;35(1):1-9.

2. Spaide RF. Disease expression in nonexudative age-related macular degeneration varies with choroidal thickness. *Retina*. 2018;38(4):708-716.

# The Future of Differentiating Microaneurysms With OCTA

The relative clinical concern of six types of microaneurysms is evaluated using OCTA, FA, and a retinal thickness map.

BY CAREL B. HOYNG, PHD



In 2014, a researcher studied high-magnification images of diabetic retinopathy (DR) microaneurysms and classified them into six morphological forms: focal bulge, saccular, fusiform, mixed, pedunculated, and irregular.<sup>1</sup> While the shapes were clear, the study did not extend to determining the clinical meaning of the morphology. To delve deeper into potential correlations between morphology and pathology in a retrospective study, my colleagues and I analyzed multimodal fluorescein angiography (FA) and OCT angiography (OCTA) imaging of microaneurysms.

A multimodal approach is important when detecting microaneurysms because there is a discrepancy between FA and OCTA. For example, in a patient with microaneurysms, FA might show the leakage and some of the microaneurysms, while OCTA shows leakage, fluid accumulation, and the thickened retina. Analyzing both imaging techniques together, we were able to learn more about microaneurysm morphology and what it may mean for our patients.

## EVALUATING MICROANEURYSM MORPHOLOGY

To learn more about these newly identified types of microaneurysms, my colleagues and I first analyzed their topographical and morphological appearance on OCTA. Once we established those characteristics, we compared them to other clinical properties, including leakage and retinal thickening.

For the study, we looked at 31 eyes of 24 subjects (14 male, 10 female) with DR and diabetic macular edema (DME). The mean age was 57. Eight subjects had type 1 diabetes and 16 had type 2. In terms of disease type and stage, five eyes had mild nonproliferative DR (NPDR), 16 had moderate NPDR, five had severe NPDR, and five had proliferative DR. Cystoid edema affected 25 eyes, while six eyes had diffuse edema. Because this was a retrospective study, most of the patients had already been treated with anti-VEGF injections, corticosteroid injections, and/or photocoagulation therapy.

Using optical OCT and the Topcon DRI OCT Triton with swept source, 3 x 3 mm scans, and eye tracking, we manually

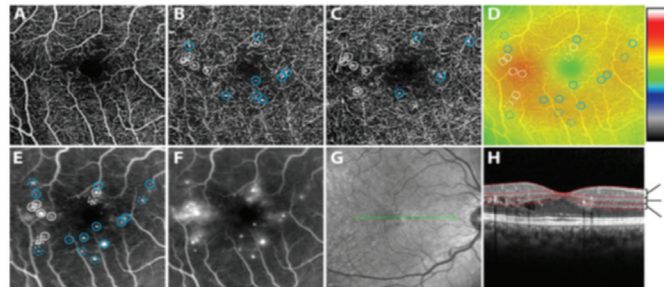
hypersegmented the eyes into the vascular plexus, superficial plexus, intermediate plexus, and deep plexus. We developed a tool that allowed us to annotate the microaneurysms and examine the same locations on each scan. We also superimposed the retinal thickness map, so we could see the flow and leakage in areas with microaneurysms. We noted which areas had high flow or low flow, with or without focal leakage.

## CORRELATING SHAPE TO PATHOLOGY

With our multimodal arrangement, we could see the different types of microaneurysms and their clinical characteristics in one image (Figure 1). We detected a mean 16.6 microaneurysms per eye, with most located in the intermediate or outer plexus (11.5 and 12.3 respectively, compared to 6.2 in the inner plexus).<sup>2</sup> A mean of 19.8 microaneurysms were early phase and 10.5 were late phase.

Overall, OCTA was able to locate 57% of the microaneurysms visible on FA, including all six of the shapes. Saccular microaneurysms were the most common type, followed by fusiform and focal bulging. The microaneurysms were distributed among the different layers of the retina. For example, saccular microaneurysms were most prevalent in the intermediate layer.

When we evaluated the pathology associated with each shape, irregular, fusiform, and mixed microaneurysms had the highest likelihood to leak. The same types were seen more in areas of retinal thickening.



Schreur V et al., Br J Ophthalmol 2018

Figure 1. Multimodal imaging shows OCTA and FA images of microaneurysms with a superimposed retinal thickness map to help correlate microaneurysm shape, location, flow, leakage, and thickness.

## IMAGING IN THE FUTURE

With only 57% of all microaneurysms detected by FA and visible on OCTA, OCTA is not yet suitable as a stand-alone imaging technique in diabetic maculopathy. However, it's very helpful for patients when used in combination with FA. In this study, OCTA proved an important research tool for improved understanding of diabetic vasculopathy of the retina. The technology was suited to defining the morphological and topographical characteristics of microaneurysms, and I think it will be an important tool in the future. Using OCTA and FA together, we were able to find that irregular, fusiform, and mixed microaneurysms were more closely associated with focal leakage and thickening compared to other types. ■

### CAREL B. HOYNG, PHD

- Radboud University Medical Center, Nijmegen, The Netherlands
- Carel.Hoyng@radboudumc.nl
- Financial disclosure: Consultant (Bayer, Horama, Sandoz, Topcon)

1. Dubow M, Pinhas A, Shah N, et al. Classification of human retinal microaneurysms using adaptive optics scanning light ophthalmoscope fluorescein angiography. *Invest Ophthalmol Vis Sci.* 2014;55(3):1299-309.  
2. Schreur V, Domanian A, Liefers B, et al. Morphological and topographical appearance of microaneurysms on optical coherence tomography angiography. *Br J Ophthalmol.* 2018.

# Diagnostic Insights Into DR and Maculopathy With SS-OCT and OCTA

The modalities make common signs easy to see, while also allowing early detection through new capabilities.

BY VASILIOS P. PAPAIOANNOU, MD, PHD, ASIS FRPS, MRCOPHTH



Diabetes is a universal problem. It's a very considerable challenge in the United Kingdom, where a recent national audit in 2016 indicated that 4.6 million people have diabetes and 12.3 million are at increased risk of type 2 diabetes.<sup>1</sup> These numbers show how vigilant we need

to be with diabetic eye screening to ensure people receive an early diagnosis. In London, there is an elaborate diabetic retinopathy (DR) screening network for the early detection of diabetic eye disease.

Swept-source OCT (SS-OCT) and OCT angiography (OCTA) technologies can enhance our screening capabilities. SS-OCT's complex light source sweeps through a range of wavelengths to visualize the vitreous and choroid. The longer wavelength (1.050 nm) increases penetration and analysis. The technology also visualizes the vitreous and choroid simultaneously. The SS-OCT platform (Topcon) includes cross-sectional OCTs, *en face* OCTs, and the OCTA format used by the swept-source DRI OCT Triton (Topcon). The latter can also obtain images of a much wider field—about 12 x 12 mm. This adds to the capacity of fundus photography, autofluorescence scans, and the acquisition of fluorescein angiograms (FAs), resulting in a platform for multimodal imaging that assists in the early detection of diabetic eye disease.

## PRINCIPAL SIGNS OF DIABETIC EYE DISEASE

In order to understand some of the principal signs of diabetic eye disease, everyone needs to be aware of the histological damage that takes place in the microvasculature of patients with diabetes. Normal vasculature has smooth muscle cells and endothelial cells. Gradually, there is capillary basement membrane thickening, loss of vascular smooth muscle cells, and, as the end result, an atrophic capillary. Essentially, this damage is associated with capillary dysfunction and the development of microaneurysms, which can attain various morphologies.

Signs of DR and maculopathy can be clearly visualized in SS-OCT and OCTA. On typical SS-OCT, we can visualize microaneurysms very clearly, along with associated intraretinal fluid (Figure 1). In OCTA, we can visualize microaneurysms at the superficial and deep capillary plexi (Figure 2). Microaneurysms tend to be localized at the deep capillary plexus, even in the mildest of forms of diabetic eye disease. The overlying superficial capillary plexus tends to be associated with increased intercapillary distance and localized reduced vascular density.

In the Triton platform's comparison with *en face* OCT, we gain additional insight into the localization of exudates, additional vascular damage, and other anatomic changes. We've traditionally assessed the amount of maculopathy by determining retinal thickening on a color-coded retinal thickness

map of the macula. When we add *en face* OCT at the outer segment, we can clearly visualize the extent of the macular edema and the exact localization of exudate—something that’s not clearly defined by the clinical image. We can also see the amount of microaneurysm and vascular damage and disorganization in the deep vascular plexus, in conjunction with the *en face* OCTA, and the changes that have taken place in that area (Figure 3). These features of diabetic eye disease would not be visible on standard FA (Figure 4).

A recent study found that some microaneurysms maintain the same internal reflectivity for about 1 year, while only 42.9% of them are associated with leakage and require treatment after 1 year.<sup>2</sup> This fits what I’ve seen in practice, but it does tend to contradict our observation that the number of microaneurysms tends to decline over time in patients with DR. It’s this decline that can be attributed to what we call microaneurysm turnover with gradual reduction in the amount of microaneurysms. This is indicative of the dynamic state of the diabetic fundus. The amount of microaneurysms constantly changes regardless of the course of the disease. A decrease in microaneurysms could indicate improvement of vascular control or could indicate worsening of the disease because of the development of associated ischemia.

## IDENTIFYING OTHER SIGNS OF DISEASE

Other common signs of diabetic eye disease are visible on SS-OCT and OCTA, if you know how to identify them. One sign is the “cotton wool spot.” Cotton wool spots, the result of increasing closure of capillaries, are seen as infarcts in the nerve fiber layer. In the cross-sectional OCT, these can be clearly visualized as hyperreflective lesions located at the level of the retinal nerve fiber layer (RNFL). This aids in the differential with exudates, especially in poorly visualized fundi as we see in patients with hazy media. With the OCTA platform, we can see the associated ischemia around a cotton wool spot and the differential impact of disease in the superficial or deep vascular plexi. We can project this image onto the fundus image to see any direct anatomic correlations.

Intraretinal microvascular abnormalities (IRMA) also can

be assessed with OCTA. These abnormalities, the result of increasing retinal ischemia, represent an effort to revascularize the hypoxic retina with microvascular channels. We can see IRMA causing disorganization of the inner retinal layers on cross-sectional OCT, as well as higher flow and bridging vessels within a point of ischemia. Due to the aforementioned disorganization, the presentation of IRMA is not strictly defined by the segmentation of the superficial or the deep capillary plexus, so we need to co-evaluate both images in order to determine the accurate extent of the IRMA.

In proliferative DR (PDR), the entire fundus is affected though primarily the mid-periphery. Therefore, there are inherent restrictions in assessing some aspects of the disease with OCTA, but the 12 x 12 mm scan can certainly provide information about some of the localized areas of neovascularization. Bear in mind that a flat or slightly raised retinal neovascularization can be fully visualized by elevating the image slab above the inner limiting membrane. This can be done manually. OCTA can easily detect the full extent of macular neovascularization in the context of PDR. This is, again, usually associated with breakup of the superficial capillary plexus, reduced capillary density, and signal voids in the choriocapillaris.

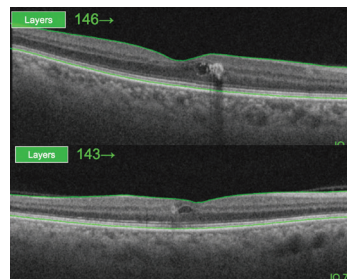


Figure 1. SS-OCT visualizes microaneurysms and some extra-cellular fluid.

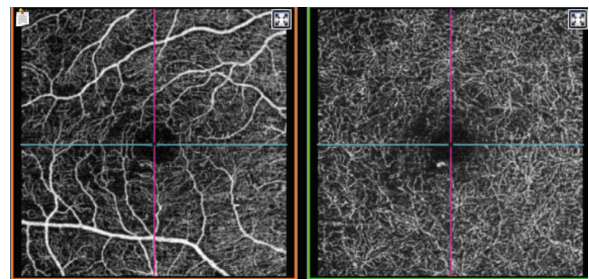


Figure 2. OCTA shows microaneurysms at the deep capillary plexus with reduced vascular density in the overlying superficial capillary plexus.

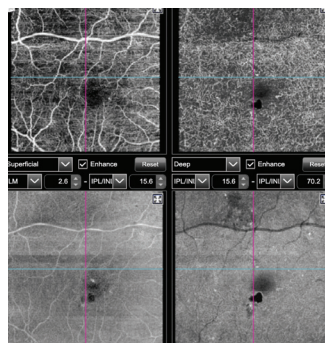


Figure 3. The Triton platform's comparison with *en face* OCT allows us to clearly visualize the extent of the macular edema and the exact localization of exudate.

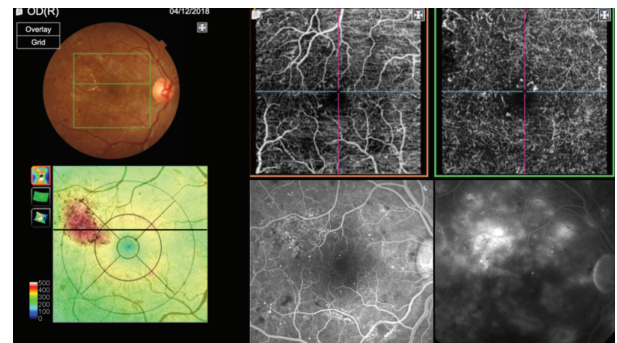


Figure 4. A side-by-side view with FA shows how SS-OCT and OCTA reveal more microaneurysms at the deep vascular plexus.

Another thing to bear in mind in PDR is that there is proven correlation of the ischemia in the mid-periphery with the extent of the breakup of the foveal avascular zone (FAZ).<sup>3</sup> In addition, panretinal photocoagulation has a proven positive effect in the macular flow indicating that this correlation is also amendable with treatment.<sup>4</sup> Interestingly, this effect has not been proven for anti-VEGF treatment.<sup>5</sup>

### DETECTING PRECLINICAL DIABETIC EYE DISEASE

The capacity of OCTA to visualize in full detail the microvascular plexi of the fundus has allowed the detection of diabetic changes before the clinical, macroscopic detection as part of a conventional screening process with fundus photography. This is termed *preclinical diabetic eye disease*. Retinal, neural, or choroidal events associated with preclinical DR can be detected with multimodal imaging.

At the retinal level, the principal sign of diabetic changes is an increase in the area of the FAZ. In this case, the normally encountered asymmetry (i.e. a deep capillary plexus larger than the superficial) is usually violated, and the area extent of the FAZ is similar.

Preclinical DR also can be detected at the neurovascular unit at the level of the RNFL. This involves the close anatomic correlation of a) the radial peripapillary capillary plexus and the RNFL and b) the superficial capillary plexus and the ganglion cell layer. This concept has been under investigation over the past 50 years. The results on the effect of diabetes have been ambivalent on both the temporal sequence of events and the final effect. Overall, two studies support that microvascular events precede neural impairment, and optic nerve head perfusion precedes or is associated with a reduction in the peripapillary RNFL thickness, but they haven't found any correlation between DR severity and RNFL thickness.<sup>6,7</sup>

With regard to the association of the superficial capillary plexus and ganglion cell layer, the latter has been reported to be thinner and preceding microvascular damage, but it's also significantly thicker in type 1 patients compared to type 2.<sup>8,9</sup> In practice, this correlation can potentially be determined in the clinical setting with Topcon's TREND function graphically correlating the temporal change in retinal thickness against RNFL or ganglion cell layer thickness. This would require serial acquisition of macular cross-sectional OCT and peripapillary cross-sectional OCTs.

SS-OCT and OCTA can be used to detect signs of diabetic eye disease in the choroid in the preclinical stage of the disease, as well as in later stages. Reduced choroidal thickness and vascular density are seen in patients with type 2 diabetes. Reduced choriocapillaris flow (signal void) can be visualized with OCTA at the choriocapillaris frame with evident voids of signal against the "white noise" appearance of healthy controls. Signal voids are seen more frequently in type 1 patients compared to type 2

patients, in patients with no clinically detected retinopathy, and in patients with varying levels of clinically evident PDR and non-proliferative DR. Evaluation of choriocapillaris flow impairment needs to take into account all the frames of OCTA in order to exclude the presence of projection artefacts from overlying exudates or hemorrhages.

For the assessment of medium and large choroidal vessels in the context of differential flow patterns, there are two things to bear in mind: 1) the assessment must be done by manually moving the choriocapillaris slab to varying levels in the choroid to determine the Haller and Sattlers layers, and 2) OCTA might not demonstrate these layers in full due to differing flow conditions. In this case, *en face* OCT with or without inversion of the signal will demonstrate them more clearly. The abnormalities of these vessels involve gradual tortuosity, reduced density, and disorganization. Finally, in severe cases, choroidal neovascularization can also develop as part of choroidal eye disease, and this can be depicted in OCTA.

### HELPING YOUR DIABETIC PATIENTS

How can SS-OCT and OCTA help you and your diabetic patients? Apart from all the classic signs and symptoms of DR and maculopathy, we can gain a new insight from information on retinal neovascularization. We can delve deeper into the microaneurysms, see IRMAs with the particular features, and detect microvascular disease in patients with no clinical signs. We can see choriocapillaris flow impairment, even in undiagnosed or early stage diabetes. We can visualize medium and large choroidal vessels with or without inverted *en face* OCT and in rare circumstances see choroidal neovascularization. These imaging modalities give us a new level of visualization to detect diabetic eye disease at the earliest point possible. ■

---

#### VASILIOS P. PAPAȘTEFANOU, MD, PHD, ASIS FRPS, MRCOPHTH

- Royal London Hospital and Barts Health NHS Trust, London
- vasilios.papastefanou@gmail.com
- Financial disclosure: None acknowledged

1. NHS. National diabetes audit report 1: findings and recommendations 2016-17. March 14, 2018. Available at: <https://digital.nhs.uk/data-and-information/publications/statistical/national-diabetes-audit/national-diabetes-audit-report-1-findings-and-recommendations-2016-17>. Accessed November 26, 2019.

2. Paravano M, De Geronimo D, Scarnici F, et al. Progression of diabetic microaneurysms according to the internal Reflectivity on structural optical coherence tomography and visibility on optical coherence tomography angiography. *Am J Ophthalmol*. 2019;198:8-16.

3. Rabiolo A, Cicinelli MV, Corbelli E, et al. Correlation analysis between foveal avascular zone and peripheral ischemic index in diabetic retinopathy: A pilot study. *Ophthalmol Retina*. 2018;2(1):46-52.

4. Fawzi AA, Fayed AE, Linsenmeier RA, et al. Improved macular capillary flow on optical coherence tomography angiography after panretinal photocoagulation for proliferative diabetic retinopathy. *Am J Ophthalmol*. 2019.

5. Couturier A, Rey PA, Erginay A, et al. Widefield OCT-angiography and fluorescein angiography assessments of nonperfusion in diabetic retinopathy and edema treated with anti-vascular endothelial growth factor. *Ophthalmology*. 2019;126(12):1685-1694.

6. Cao D, Yang D, Yu H, et al. Optic nerve head perfusion changes preceding peripapillary retinal nerve fiber layer thinning in preclinical diabetic retinopathy. *Clin Exp Ophthalmol*. 2019;47(2):219-225.

7. Liu L, Wang Y, Liu HX, Gao J. Peripapillary region perfusion and retinal nerve fiber layer thickness abnormalities in diabetic retinopathy assessed by OCT angiography. *Transl Vis Sci Technol*. 2019;8(4):14.

8. Kim K, Kim ES, Kim DG, Yu SY. Progressive retinal neurodegeneration and microvascular change in diabetic retinopathy: longitudinal study using OCT angiography. *Acta Diabetol*. 2019;56(12):1275-1282.

9. Vujosevic S, Muraca A, Alkables M, et al. Early microvascular and neural changes in patients with type 1 and type 2 diabetes mellitus without clinical signs of diabetic retinopathy. *Retina*. 2019;39(3):435-445.