

## REVIEW ARTICLE

## Esophageal hypertensive peristaltic disorders

S. ROMAN\* &amp; R. TUTUIAN†

\*Digestive Physiology, Hopsices Civils de Lyon, Hospital E Herriot, and Lyon I University, Lyon, France

†Division of Gastroenterology, University Clinic for Visceral Surgery and Medicine, Bern University Hospital, Inselspital, Bern, Switzerland

**Abstract**

**Background** Esophageal motility abnormalities include a series of manometric findings that differ to a significant degree from findings in normal, asymptomatic volunteers.

**Methods** Current review summarizes conventional and high-resolution esophageal manometry criteria used to define and characterize esophageal hypertensive motility abnormalities.

**Key Results** In the conventional esophageal manometry classification scheme hypertensive esophageal motility abnormalities include nutcracker esophagus (average distal contraction amplitude >180mmHg), hypertensive lower esophageal sphincter (average resting LES pressure >45mmHg) and poorly relaxing lower esophageal sphincter (average LES residual pressure >8mmHg). The new, high resolution esophageal manometry scheme includes in the group of hypertensive peristaltic disorders hypertensive peristalsis (“nutcracker esophagus”: mean DCI >5000 mmHg\*sec\*cm) and hypercontractile esophagus (“jackhammer esophagus”: at least one contraction with DCI > 8,000 mmHg\*sec\*cm) and defines a separate group for disorders with impaired esophageal-gastric junction relaxation (mean integrated residual (LES) pressure >15mmHg).

**Conclusions & Inferences** Hypertensive motility disorders represent a heterogeneous condition subdivided into hypercontractile esophagus and hypertensive

peristalsis. Further studies are required to determine the clinical relevance of this new classification.

**Keywords** high-resolution manometry, hypercontractile, nutcracker esophagus.

## INTRODUCTION

Esophageal motility abnormalities are, with the exception of achalasia and scleroderma esophagus, esophageal manometry findings that differ to a significant degree from findings in normal individuals. Hypertensive esophageal peristalsis also known as ‘nutcracker esophagus’ has been reported in association with dysphagia, non-cardiac chest pain,<sup>1</sup> and heartburn.<sup>2</sup> Their physiopathology remains unclear and different hypotheses have been suggested. A primary neuromuscular disorder was suspected. Contrary to esophageal spasm which is associated with impaired deglutitive inhibition,<sup>3</sup> central, and inhibitory mechanisms induced by repetitive swallows are preserved in nutcracker esophagus.<sup>4</sup> Vigorous esophageal contractions may be related to excessive excitation or myocyte hypertrophy.<sup>5</sup> Using concomitant esophageal manometry and high frequency intraluminal ultrasound examination, increased esophageal muscle thickness was observed in patients with hypertensive contractions. Asynchrony between the circular and longitudinal muscularis propria contractions was also observed in these patients.<sup>6</sup> Finally this asynchrony might be reversed by atropine.<sup>7</sup> Therefore, these findings support the concept that excessive cholinergic drive could be an important pathophysiological component of hypertensive motility disorders. However, these disorders might also be a reactive process. Gastro-esophageal reflux disease was associated with chest pain and hypertensive esophageal contractions.<sup>8</sup> Hypertensive

*Address for Correspondence*

Sabine Roman MD, PhD, Digestive Physiology, Hôpital E Herriot, Pavillon H, 5 place d’Arsonval, 69437 Lyon Cedex 03, France.

Tel: +33 4 72 11 01 36; fax: +33 4 72 11 01 46;

e-mail: roman.sabine@gmail.com

Received: 18 September 2011

Accepted for publication: 10 October 2011

contractions were observed in case of esophago-gastric junction (EGJ) obstruction. Thus, experimental EGJ obstruction led to esophageal muscle hypertrophy and hyper-excitability in cats.<sup>9</sup> In humans hypertensive contractions were noticed in presence of mechanical obstruction induced by fundoplication or gastric lap band.<sup>10</sup> Anderson *et al.*<sup>11</sup> documented a statistically significant increase in esophageal contraction amplitudes in both healthy volunteers and patients with non-cardiac chest pain while being exposed to acute stressors (intermittent bursts of white noise and difficult cognitive tasks).

The initial description of hypertensive motility disorders was realized with conventional manometry.<sup>12</sup> The term 'nutcracker esophagus' was coined to illustrate the vigor of the contractions and the fluoroscopic pattern. However, the clinical relevance of these hypertensive disorders was debated as hypertensive contractions were encountered in asymptomatic patients.<sup>13</sup> Moreover, hypertensive contractions might persist although patients' symptoms were alleviated. Thus, the relationship between observed hypercontractility and symptoms is not clear. Evaluating bolus transit in patients with various esophageal motility abnormalities Tutuian *et al.*<sup>14</sup> found that 97% of patients with nutcracker esophagus had a complete bolus transit assessed by impedance. These data raised the question of an overestimation of hypertensive motility disorders. Therefore, a revision of criteria for diagnosis of hypertensive peristalsis was suggested to improve clinical relevance.<sup>1</sup>

In the era of high-resolution manometry, a new metric (Distal Contractile Integral, DCI) is used to assess contractile vigor.<sup>15</sup> It reflects not only the amplitude of the contraction but also integrates the duration and the length of the contractile segment. Moreover, as pressure variations are displayed as esophageal pressure topography (EPT) or Clouse plots, contractions pattern might be described more accurately with HRM than with conventional manometry.

The aims of this overview on hypertensive peristaltic disorders were (i) to describe the original definition of hypertensive disorders with conventional manometry, (ii) to characterize these disorders with HRM metrics and Clouse plots patterns, and (iii) to propose a definition of hypertensive peristaltic disorders in high-resolution manometry.

#### ORIGINAL DEFINITION USING CONVENTIONAL MANOMETRY

Nutcracker esophagus was defined by Castell and colleagues as a condition in which patients with

unexplained chest pain and/or dysphagia exhibit peristaltic contractions in the distal esophagus with mean amplitudes exceeding normal values by more than two DS.<sup>12</sup> In the classification of esophageal motility abnormalities proposed by Spechler and Castell,<sup>16</sup> hypertensive peristalsis was defined as a mean distal esophageal peristaltic wave amplitude >180 mmHg. This mean amplitude was measured as the average amplitude of 10 swallows at two recording sites positioned 3 and 8 cm above the lower esophageal sphincter (LES). This disorder occurs in a context of normal EGJ relaxation and normal contraction propagation. Even if many patients with nutcracker esophagus exhibited peristaltic contractions with duration exceeding 6 s, this criterion was not required to diagnose hypertensive motility disorders with conventional manometry. Resting LES pressure was usually normal but might be elevated in patients having nutcracker esophagus with hypertensive LES.

Subsequently, the defining peristaltic amplitude has been debated and more recent work suggests that the amplitude threshold should be increased to 260 mmHg (mean amplitude exceeding normal values by four DS), a value which might have a greater clinical relevance.<sup>1</sup> This revision is based on findings according to which patients with distal esophageal amplitude >260 mmHg presented more frequently chest pain and dysphagia and less frequently abnormal esophageal acid exposure than patients with distal esophageal amplitude between 180 and 260 mmHg. As this criterion might be too stringent, Agrawal *et al.*<sup>1</sup> proposed to include possible patients with a mean distal esophageal amplitude of more than 220 mmHg to define nutcracker esophagus.

Hypertensive contractions might also occur in the context of incomplete LES relaxation or distal esophageal spasm. In case of incomplete LES relaxation, esophageal motility disorder was classified as achalasia. In case of simultaneous contraction and normal LES relaxation, the esophageal motility disorder was classified as distal esophageal spasm.

Finally isolated hypertensive LES was defined as a mean resting LES pressure of >45 mmHg measured in mid respiration using the station pull through technique.<sup>16</sup> This abnormality has normal LES relaxation (defined as LES residual pressure <8 mmHg) and was classified into the group of esophageal hypercontraction as hypertensive lower esophageal sphincter (LES). The physiologic and clinical implications of the hypertensive LES are also not free of debate. Hypertensive LES has been associated with gastroesophageal reflux even though at first this association appears

paradoxical because of the original association of GERD and decreased LES pressures.<sup>17</sup> Other investigators reported an increased intrabolus pressure and impaired bolus transit in patients with hypertensive LES suggesting that this motility abnormality might be a form of outflow obstruction.<sup>18</sup>

In clinical practice it is not uncommon to find a combination of the above-mentioned abnormalities. For example a patient may have high esophageal contractions amplitudes (i.e. nutcracker esophagus) in combination with a high lower esophageal sphincter pressure (i.e. hypertensive LES) and even a high LES residual pressure (poorly relaxing LES).

### CHARACTERIZATION OF HYPERTENSIVE PERISTALTIC CONTRACTIONS WITH HRM

The introduction of HRM and Clouse plots allow further stratification of hypertensive peristalsis to account for both excessive vigor and abnormal morphology of the peristaltic contraction. The summary metric for contractile vigor in the entire distal segment is the distal contractile integral (DCI). The hypertensive contraction pattern is also easily described with HRM: repetitive pattern and location of the hypertensive segment might be clinically relevant.

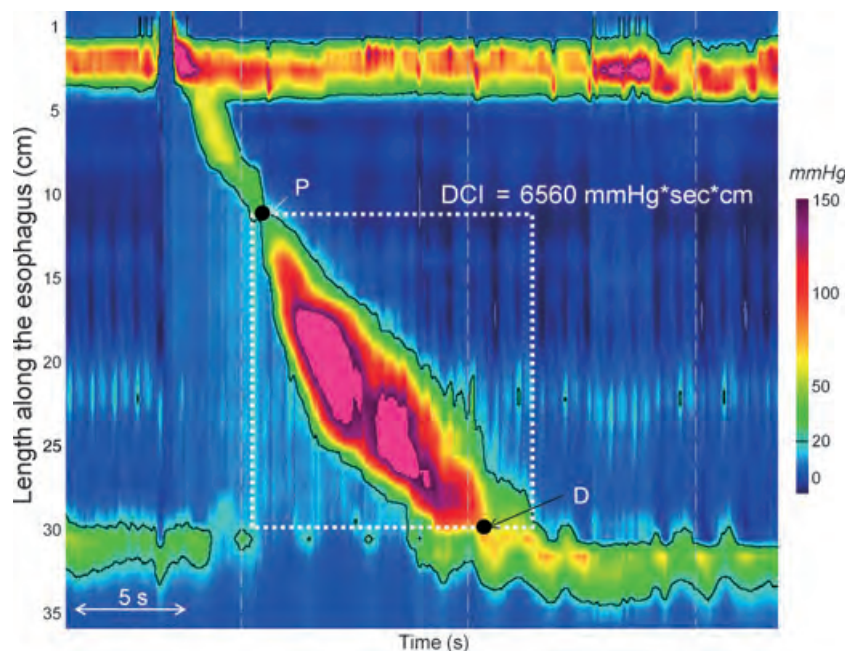
### Distal contractile integral

The distal contractile integral corresponds to the volume of the distal contraction in dimensions of amplitude, time, and length between the proximal and the distal troughs using the 20-mmHg isobaric contour at the base (Fig. 1). It is calculated by multiplying the integral of the contraction amplitude in the distal esophagus (mmHg) times the duration of contraction (s) times the length of the distal esophageal segment (cm).<sup>15</sup> It is expressed as mmHg\*sec\*cm. Pressures lower than 20 mmHg were excluded from the DCI calculation to eliminate intra-bolus pressure.<sup>15</sup>

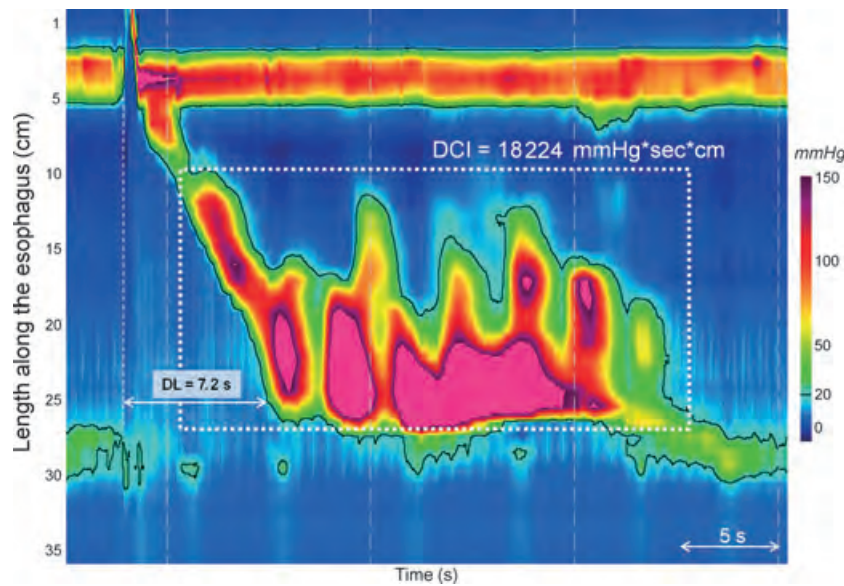
In 75 controls, the median (IQR) DCI was 2416 (1967–2963) mmHg\*sec\*cm.<sup>19</sup> A value of 5000 mmHg\*sec\*cm being the 95th percentile of normal was considered as abnormal. A value >8000 mmHg\*sec\*cm was never encountered in control subjects. These thresholds have been suggested to define hypertensive peristaltic disorders in HRM.<sup>19</sup>

### Contraction pattern

Clouse plots allow easy pattern recognition of motility disorders. It might facilitate studies review and improve diagnostic yield of this examination.<sup>20</sup> A more



**Figure 1** The distal contractile integral (DCI) corresponds to the entire volume (amplitude x time x length) of the distal contraction spanning from the proximal (P) to the distal (D) troughs (white box) above 20 mmHg. The DCI is calculated by multiplying the integral of amplitude x the duration x the length of the contractile segment contained in the white box.



**Figure 2** Extremely abnormal contraction ( $DCI > 8000 \text{ mmHg} \cdot \text{sec} \cdot \text{cm}$ ) in a patient with a hypercontractile esophagus. The esophago-gastric junction relaxation is normal (integrated relaxation pressure  $IRP = 5 \text{ mmHg}$ ) and the distal latency ( $DL > 4.5 \text{ s}$ ). This swallow is associated with repetitive prolonged contractions evoking the action of the jackhammer.

physiological characterization is also possible and may provide a better understanding of motility disorders.

Multipeaked pattern might be a characteristic of hypertensive contraction (Fig. 2). Clouse<sup>21</sup> was the first to hypothesize that double-peaked contractions occurred as a consequence of the overlap and imperfect coordination between the adjacent second and third contractile segments. Further he described multipeaked pattern in symptomatic patients.<sup>22</sup> The main symptom associated with this pattern was unexplained chest pain. The second peak was a typically short, simultaneous or retrograde pressure event in the distal esophagus. Multipeaked contractions tended to be associated with greater maximal amplitude in the third segment compared to single peak contractions. Recently Roman *et al.*<sup>23</sup> observed that multipeaked contractions were encountered in 82% of patients with at least one esophageal high amplitude contraction ( $DCI > 8000 \text{ mmHg} \cdot \text{sec} \cdot \text{cm}$ ) in a context of normal propagation and normal EGJ relaxation. To compare, the multipeaked pattern was observed in only 3% of control subjects. On the other hand, double-peaked contractions are observed in healthy volunteers<sup>24</sup> relativating their clinical importance in the patients with esophageal symptoms. However, Sampath *et al.*<sup>25</sup> proposed that multipeaked contractions might be an artifact. As the distal esophagus and diaphragm are attached at the EGJ, they move in unison during respiration. These respiratory oscillations could cause the appearance of a multipeaked pattern attributable to

movement of the contracting esophagus relative to the sensor recording that contraction. Suspended breathing and hyperventilation modified the esophageal contraction waveform morphology accordingly. It is important to note that only three patients of nine included in the study of Sampath presented a hypertensive motility disorder. Thus, even if the respiratory oscillation hypothesis may explain a multipeaked contraction at the spatial margins of the contractile segment in some instances, this explanation seems insufficient to explain the extreme oscillations spanning the entire contractile segment as illustrated in Fig. 2. Finally Roman *et al.*<sup>23</sup> systematically explored the synchrony between multipeaked contractions and respiration in patients with at least one contraction with a  $DCI > 8000 \text{ mmHg} \cdot \text{sec} \cdot \text{cm}$  in a context of normal propagation and normal EGJ relaxation. Multipeaked contractions were synchronized with respiration in about half of the patients whereas in the other half they were not. There was no apparent clinical difference between these subsets.

Hypertensive contractions might also be characterized with the location of maximal amplitude. Indeed Clouse<sup>21</sup> showed that nutcracker esophagus primarily affected the distal segment in the smooth muscle body. Gyawali<sup>26</sup> suggested that the location of maximal amplitude segment might be used to differentiate primary from secondary motility disorders. Indeed in patients with impaired EGJ relaxation and preserved esophageal peristalsis location of maximal amplitude

varied according to the etiology of EGJ outflow obstruction. Mechanical obstruction was associated with higher pressure volume in the second segment and lower pressure volume in the third segment compared to controls. On the other hand, functional obstruction was associated with the reverse change, higher pressure volume in the third segment and lower in the second. It remains to be determined if the location of maximal amplitude segment might be also predictive of the etiology of hypercontractility in absence of EGJ outflow obstruction. Finally in the same study Gyawali<sup>26</sup> noticed that some patients with EGJ functional obstruction also exhibited multi-peaked contractions and prolonged contraction duration. This supports the hypothesis that hypertensive peristalsis might be reactive to EGJ outflow obstruction in some instances.

#### DEFINITION OF HYPERTENSIVE PERISTALTIC DISORDERS WITH HRM

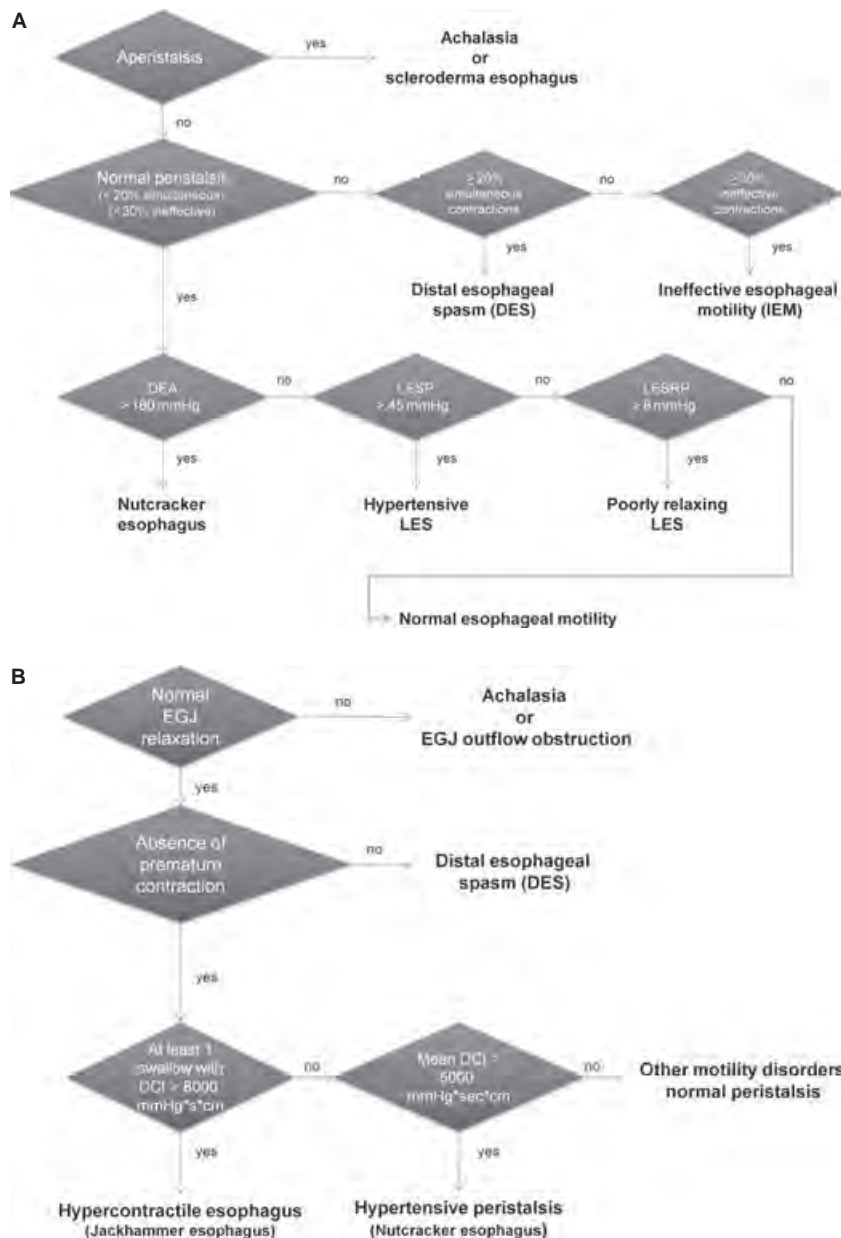
Conventional manometry and HRM have not been directly compared to diagnose hypertensive motility disorders. One of the major differences with the two techniques is that hypercontractility is defined only on the amplitude of the contraction in conventional manometry whereas it is defined by amplitude, duration, and length of contraction in HRM. In the first versions of the Chicago classification for esophageal motility disorders in EPT, hypertensive peristalsis definition was proposed by analogy with the classification of Spechler and Castell in conventional manometry. Thus, the diagnosis of hypertensive peristalsis was based on an elevated mean contractile vigor. As the metric used in HRM to measure the vigor of the contraction is the DCI rather than the amplitude, hypertensive peristalsis was defined using a mean DCI of 10 swallows.<sup>19,27</sup> In the context of normal EGJ relaxation and normal propagation, hypertensive peristalsis was defined as a mean DCI > 5000 mmHg\*sec\*cm. Based on this definition, hypertensive peristalsis was diagnosed in 9% of a 400 patient series.<sup>27</sup> As hypertensive peristalsis presented a substantial heterogeneity, it was subsequently divided into 'Nutcracker esophagus' if the mean DCI was within the 5000–8000 range and into 'Spastic nutcracker' if the mean DCI was >8000. As previously mentioned, the threshold value of 8000 mmHg\*sec\*cm was chosen because this value was never encountered in healthy volunteers. It was also uniformly associated with dysphagia or chest pain.<sup>27</sup> The presence of repetitive high-amplitude contractions was noticed in patients with spastic nutcracker but was not

required for the positive diagnosis. A sub classification according to the location of hypertensive segment was also proposed in the first version of the Chicago classification.<sup>27</sup> The segmental nutcracker corresponded to the presence of only one segmental focus of hypertensive contraction (>180 mmHg) and the nutcracker LES to the focus of hypertensive contraction (>180 mmHg) limited to the LES-after contraction. Finally hypertensive peristalsis was associated with hypertensive LES (>35 mmHg) in 19%.<sup>27</sup>

The Chicago Classification of esophageal motility disorders continually evolves through the workings of an international group. A general process is to re-define motility disorders based on individual swallows classification. Thus, new criteria have been proposed for achalasia,<sup>28</sup> distal esophageal spasm,<sup>29</sup> weak and frequent failed peristalsis.<sup>30</sup> This process of re-definition was also applied to hypertensive peristalsis.

Thus the classification is now based on the evaluation of the individual swallows. A contraction is characterized as hypercontractile if DCI > 8000 mmHg\*sec\*cm in the context of normal propagation.<sup>31</sup> Thus a swallow may be classified as hypercontractile only if the distal latency is normal. If the distal latency is reduced (<4.5 s), the swallow is classified as premature whatever the DCI.<sup>29</sup> Once again, this pattern represents an extreme phenotype never encountered in control subjects. Hypercontractile contractions are further sub typed as single peaked or multi-peaked contraction synchronized or not with respiration. They might occur in a context of normal or impaired EGJ relaxation.

The current iteration of the Chicago classification of esophageal motility disorders defines a hypercontractile esophagus ('Jackhammer esophagus') by the presence of at least one hypercontractile contraction (DCI > 8000 mmHg\*sec\*cm) in the context of normal EGJ relaxation. This motility disorder is rare (4.1% of a 2000 patient series).<sup>31</sup> It is constantly associated with esophageal symptoms (dysphagia, reflux, chest pain). However, the clinical presentation remains diverse and hypercontractile esophagus may be attributable not only to primary esophageal muscle hypercontractility but also secondary to reflux disease or mechanical EGJ obstruction.<sup>23</sup> As similar characteristics and similar outcomes have been observed in patients with single peak and multi-peaked contractions synchronized or with respiration, the distinction between different subtypes does not seem relevant. Finally it is proposed to nickname this extreme phenotype of hypercontractile esophagus 'Jackhammer esophagus' (rather than spastic nutcracker) to fit better with the contractile



**Figure 3** Algorithm for the diagnosis of hypertensive peristaltic disorders. Panel A: conventional manometry criteria, Panel B: high-resolution manometry (Chicago) criteria. Legend: DEA – distal esophageal amplitude, LESP – lower esophageal sphincter pressure (resting), LESRP – lower esophageal sphincter residual pressure.

morphology and to avoid confusion with spasm which occurs in a context of reduced distal latency.

Hypertensive peristalsis known as ‘nutcracker esophagus’ is reserved for patients with mean DCI  $> 5000$  mmHg\*sec\*cm and without any contraction with DCI  $> 8000$  mmHg\*sec\*cm (criteria for hypercontractile esophagus). The current separation between hypercontractile esophagus and hypertensive peristalsis is a good starting point for future studies

aimed at refining (high resolution) manometric criteria according to symptoms and treatment outcome. First results suggest that an average DCI  $> 8000$  mmHg\*sec\*cm is more likely associated with chest pain.<sup>32</sup> However, direct relationship between the occurrence of hypercontractile swallow and symptom has not yet been proved. It remains also to be determined if treatment of hypercontractility is associated with reduction of symptoms.

## CONCLUSION

Hypertensive motility disorders represent a heterogeneous condition which may be attributable to primary muscle hyperexcitability but also to a reactive process to reflux disease or EGJ outflow obstruction. Diagnosis of hypertensive peristaltic disorders is retained only if the disorder occurs in a context a normal EGJ relaxation (Fig. 3). Using high-resolution manometry and Clouse plots, hypertensive peristaltic disorders are subdivided into hypercontractile esophagus ('Jackhammer esophagus': at least one swallow with a DCI > 8000 mmHg\*sec\*cm) and hypertensive peristalsis ('Nutcracker esophagus': mean DCI > 5000 mmHg\*sec\*cm without any swallow with DCI > 8000 mmHg\*sec\*cm). Although hypercontractile swallows are often characterized by a multi-peaked pattern, no specific pattern has

been so far identified as being associated with a homogeneous population and clinical presentation potentially amenable to specific pharmacological treatment. Furthermore studies are required to precisely examine the clinical relevance of this new classification.

## CONFLICT OF INTEREST

SR has served as consultant for Given Imaging. RT is involved in educational programs for Sandhill Scientific and Medical Measurements Systems.

## AUTHOR CONTRIBUTIONS

SR analyzed the data and wrote the paper; RT analyzed the data and wrote the paper.

## REFERENCES

- Agrawal A, Hila A, Tutuian R, Mainie I, Castell DO. Clinical relevance of the nutcracker esophagus: suggested revision of criteria for diagnosis. *J Clin Gastroenterol* 2006; **40**: 504–9.
- Pehlivanov N, Liu J, Mittal RK. Sustained esophageal contraction: a motor correlate of heartburn symptom. *Am J Physiol Gastrointest Liver Physiol* 2001; **281**: G743–51.
- Behar J, Biancani P. Pathogenesis of simultaneous esophageal contractions in patients with motility disorders. *Gastroenterology* 1993; **105**: 111–8.
- Brito EM, Camacho-Lobato L, Paoletti V, Gideon M, Katz PO, Castell DO. Effect of different swallow time intervals on the nutcracker esophagus. *Am J Gastroenterol* 2003; **98**: 40–5.
- Dogan I, Puckett JL, Padda BS, Mittal RK. Prevalence of increased esophageal muscle thickness in patients with esophageal symptoms. *Am J Gastroenterol* 2007; **102**: 137–45.
- Jung HY, Puckett JL, Bhalla V *et al*. Asynchrony between the circular and the longitudinal muscle contraction in patients with nutcracker esophagus. *Gastroenterology* 2005; **128**: 1179–86.
- Korsapati H, Bhargava V, Mittal RK. Reversal of asynchrony between circular and longitudinal muscle contraction in nutcracker esophagus by atropine. *Gastroenterology* 2008; **135**: 796–802.
- Achem SR, Kolts BE, Wears R, Burton L, Richter JE. Chest pain associated with nutcracker esophagus: a preliminary study of the role of gastroesophageal reflux. *Am J Gastroenterol* 1993; **88**: 187–92.
- Mittal RK, Ren J, McCallum RW, Shaffer HA Jr, Sluss J. Modulation of feline esophageal contractions by bolus volume and outflow obstruction. *Am J Physiol* 1990; **258**: G208–15.
- Burton PR, Brown W, Laurie C *et al*. The effect of laparoscopic adjustable gastric bands on esophageal motility and the gastroesophageal junction: analysis using high-resolution video manometry. *Obes Surg* 2009; **19**: 905–14.
- Anderson KO, Dalton CB, Bradley LA, Richter JE. Stress induces alteration of esophageal pressures in healthy volunteers and non-cardiac chest pain patients. *Dig Dis Sci* 1989; **34**: 83–91.
- Benjamin SB, Gerhardt DC, Castell DO. High amplitude, peristaltic esophageal contractions associated with chest pain and/or dysphagia. *Gastroenterology* 1979; **77**: 478–83.
- Kahrilas PJ. Nutcracker esophagus: an idea whose time has gone? *Am J Gastroenterol* 1993; **88**: 167–9.
- Tutuian R, Castell DO. Combined multichannel intraluminal impedance and manometry clarifies esophageal function abnormalities: study in 350 patients. *Am J Gastroenterol* 2004; **99**: 1011–9.
- Ghosh SK, Pandolfino JE, Zhang Q, Jarosz A, Shah N, Kahrilas PJ. Quantifying esophageal peristalsis with high-resolution manometry: a study of 75 asymptomatic volunteers. *Am J Physiol Gastrointest Liver Physiol* 2006; **290**: G988–97.
- Spechler SJ, Castell DO. Classification of oesophageal motility abnormalities. *Gut* 2001; **49**: 145–51.
- Katzka DA, Sidhu M, Castell DO. Hypertensive lower esophageal sphincter pressures and gastroesophageal reflux: an apparent paradox that is not unusual. *Am J Gastroenterol* 1995; **90**: 280–4.
- Gockel I, Lord RV, Bremner CG, Crookes PF, Hamrah P, DeMeester TR. The hypertensive lower esophageal sphincter: a motility disorder with manometric features of outflow obstruction. *J Gastrointest Surg* 2003; **7**: 692–700.
- Pandolfino JE, Fox MR, Bredenoord AJ, Kahrilas PJ. High-resolution manometry in clinical practice: utilizing pressure topography to classify oesophageal motility abnormalities. *Neurogastroenterol Motil* 2009; **21**: 796–806.
- Fox MR, Bredenoord AJ. Oesophageal high-resolution manometry: moving from research into clinical practice. *Gut* 2008; **57**: 405–23.
- Clouse RE, Staiano A. Topography of normal and high-amplitude esophageal peristalsis. *Am J Physiol* 1993; **265**: G1098–107.
- Clouse RE, Staiano A, Alrakawi A. Topographic analysis of esophageal double-peaked waves. *Gastroenterology* 2000; **118**: 469–76.

- 23 Roman S, Pandolfino JE, Chen J, Boris L, Luger D, Kahrilas PJ. Phenotypes and clinical context of hypercontractility in high resolution pressure topography (EPT). *Am J Gastroenterol* 2011. doi: 10.1038/ajg.2011.313 [Epub ahead of print].
- 24 Richter JE, Wu WC, Johns DN *et al.* Esophageal manometry in 95 healthy adult volunteers. Variability of pressures with age and frequency of "abnormal" contractions. *Dig Dis Sci* 1987; **32**: 583–92.
- 25 Sampath NJ, Bhargava V, Mittal RK. Genesis of multip peaked waves of the esophagus: repetitive contractions or motion artifact? *Am J Physiol Gastrointest Liver Physiol* 2010; **298**: G927–33.
- 26 Gyawali CP, Kushnir VM. High-resolution manometric characteristics help differentiate types of distal esophageal obstruction in patients with peristalsis. *Neurogastroenterol Motil* 2011; **23**: 502–e197.
- 27 Pandolfino JE, Ghosh SK, Rice J, Clarke JO, Kwiatek MA, Kahrilas PJ. Classifying esophageal motility by pressure topography characteristics: a study of 400 patients and 75 controls. *Am J Gastroenterol* 2008; **103**: 27–37.
- 28 Pandolfino JE, Kwiatek MA, Nealis T, Bulsiewicz W, Post J, Kahrilas PJ. Achalasia: a New Clinically Relevant Classification by High-Resolution Manometry. *Gastroenterology* 2008; **135**: 1526–33.
- 29 Pandolfino JE, Roman S, Carlson D *et al.* Distal esophageal spasm in high-resolution esophageal pressure topography: defining clinical phenotypes. *Gastroenterology* 2011; **141**: 469–75.
- 30 Roman S, Lin Z, Kwiatek MA, Pandolfino JE, Kahrilas PJ. Weak peristalsis in esophageal pressure topography: classification and association with dysphagia. *Am J Gastroenterol* 2011; **106**: 349–56.
- 31 Roman S, Pandolfino JE, Chen J, Boris L, Luger D, Kahrilas PJ. Phenotypes and Clinical Context of Hypercontractility in High-Resolution Esophageal Pressure Topography (EPT). *Am J Gastroenterol*. 2011; Sep 20. doi: 10.1038/ajg.2011.313. [Epub ahead of print] PMID:21931377 <http://www.ncbi.nlm.nih.gov/pubmed/21931377>.
- 32 Hoshino M, Sundaram A, Juhasz A, *et al.* High-resolution impedance manometry findings in patients with nutcracker esophagus. *J Gastroenterol Hepatol* 2011. doi: 10.1111/j.1440-1746.2011.06911x [Epub ahead of print].



## REVIEW ARTICLE

# Weak and absent peristalsis

ANDRÉ SMOUT\* & MARK FOX†

\*Academic Medical Centre, Amsterdam, The Netherlands

†NIHR Biomedical Research Unit, Nottingham Digestive Diseases Centre, Queen's Medical Centre, Nottingham, UK

### Abstract

**Background** *Weak and absent esophageal peristalsis are frequently encountered esophageal motility disorders, which may be associated with dysphagia and which may contribute to gastroesophageal reflux disease. Recently, rapid developments in the diagnostic armamentarium have taken place, in particular, in high-resolution manometry with or without concurrent intraluminal impedance monitoring.*

**Purpose** *This article aims to review the current insights in the terminology, pathology, pathophysiology, clinical manifestations, diagnostic work-up, and management of weak and absent peristalsis.*

**Keywords** *absent peristalsis, high-resolution manometry, impedance monitoring, ineffective esophageal motility, weak peristalsis.*

Motor abnormalities of the esophagus that fit the category 'weak and absent peristalsis' are probably the least studied manifestations of esophageal dysfunction, likely because of the apparent lack of therapeutic options. It is important to recognize that the manometric diagnosis of esophageal hypomotility does not necessarily imply abnormal esophageal transit or presence of symptoms, including dysphagia.

### Address for Correspondence

André Smout MD, PhD, Department of Gastroenterology and Hepatology, Academic Medical Center, PO Box 22700, 1100 DE, Amsterdam, The Netherlands.

Tel: +31 20 56691111; fax: +31 20 6917033;

e-mail: a.j.smout@amc.uva.nl

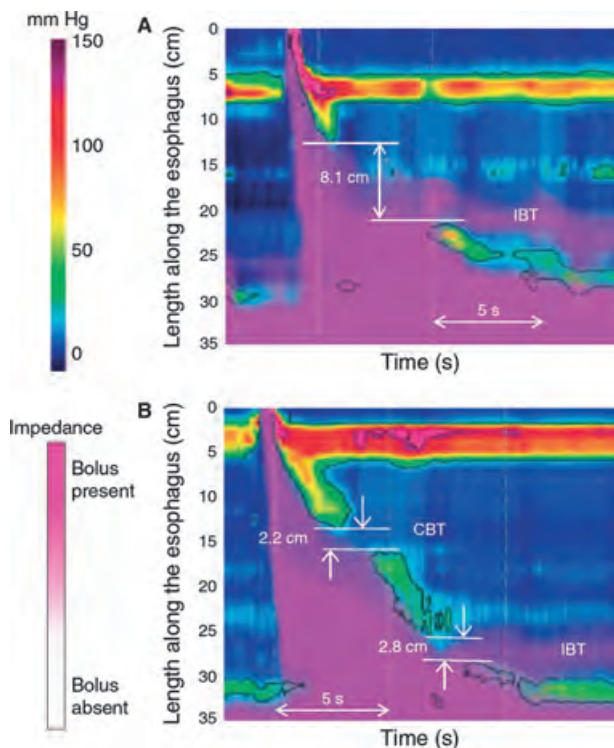
Received: 27 August 2011

Accepted for publication: 25 October 2011

### DEFINITIONS AND TERMS

Until 1997, the term 'nonspecific esophageal motor abnormalities' was generally used by physiologists to denote any dysmotility pattern that was not achalasia, spasm, nutcracker or LES dysfunction. Then, Leite and coworkers published their finding that 'ineffective esophageal motility' (IEM) was the primary finding in patients with nonspecific esophageal motility disorder.<sup>1</sup> In 2001, this was incorporated into Spechler and Castell's<sup>2</sup> classification of esophageal motor disorders, based on conventional manometry. In their classification, IEM was defined as distal-esophageal hypocontractility in at least 30% of wet swallows, characterized either as low-amplitude peristaltic waves (<30 mmHg), low-amplitude simultaneous waves (<30 mmHg) or peristaltic waves that are not propagated to the distal-esophagus, or absent peristalsis. The 30-mmHg criterion was derived from the observation that amplitudes <30 mmHg were frequently associated with bolus escape and incomplete bolus clearance.<sup>3</sup>

High-resolution manometry (HRM), with or without concurrent intraluminal impedance monitoring, allows a more complete definition of peristalsis. In the recently developed Chicago classification, frequent failed peristalsis (>30% of wet swallows) is separated from weak peristalsis (defined as breaks in the 20-mmHg isobaric contour). Weak peristalsis with large defects is judged to be present when breaks >5 cm are present in >20% of swallows (Fig. 1). Weak peristalsis with small defects is present when breaks of 2–5 cm in length are present in >30% of swallows.<sup>4</sup> This classification of manometric abnormalities as abnormal is also based on the likelihood that such defects are associated with esophageal dysfunction (i.e. bolus escape); however, the clinical relevance of such observations remains uncertain. Indeed, it is likely that



**Figure 1** Examples of high-resolution manometry showing weak peristalsis with small (2–5 cm) (A) and large (>5 cm) (B) breaks in the 20-mmHg isobaric contour. Reproduced with permission from Roman *et al.* *Am J Gastroenterol* 2011;106:349–356.

several abnormal swallows in series are required before symptoms are experienced.<sup>5</sup>

## EPIDEMIOLOGY

Formally, normal values for esophageal manometry should be population-specific and stratified by age and gender such that, by definition, 5% have hypotensive contractions in every group. This quality of data does not exist. Normal values for conventional manometry are based on observations in 95 healthy subjects with a mean age of 43 years (range 22–79 years),<sup>6</sup> whereas the two HRM studies upon which the cutoff values for peristaltic breaks were based included only volunteers under the age of 50.<sup>4,7</sup> Data gathered with conventional manometry suggest that the amplitude of esophageal contractions is higher in men than women, rises with increasing age and is higher in Afro-Caribbean than Hispanic and Caucasian populations.<sup>6,8</sup> This variation between demographic and racial groups may be due to specific effects of age, gender and race, or common factors such as increased outflow resistance caused by central obesity. What is beyond doubt is that esopha-

geal hypocontractility (weak, absent or failed peristalsis) is the most prevalent finding in clinical series. In our own experience, IEM with or without hypotensive LES was found in 58% of 2610 patients referred for (conventional) manometry. In a series of 350 consecutive patients who underwent manometry for various indications IEM was found in 20.2%.<sup>9</sup> IEM was observed in 27–32% of patients presenting with non-obstructive dysphagia without GERD.<sup>10,11</sup> Hypocontractility is also the most prevalent esophageal motor disorder in GERD, found in 21–38% of patients in large series, and its presence is associated with the severity of acid exposure and reflux symptoms.<sup>12,13</sup> Similarly, in a group of patients with respiratory symptoms associated with reflux, IEM was found in 53% of asthmatics, 41% of chronic coughers and 31% of those with laryngitis.<sup>14</sup>

## PATHOGENESIS AND PATHOPHYSIOLOGY

In most cases of weak or absent peristalsis identified in the motility lab the pathogenesis of the motility disorder will remain unclear. Autopsy studies of the pathology underlying this disordered function are lacking.

The exceptions to this rule are scleroderma and related connective tissue disorders, in which esophageal pathology has been studied extensively. There are three stages in the development of esophageal involvement in scleroderma: neuropathy, myopathy, and fibrosis.<sup>15</sup> The neuronal abnormalities in the first stage are thought to be the consequence of arteriolar changes in the vasa nervorum. In the second stage, ischemia leads to focal degeneration and atrophy of the muscle layers. Finally, the muscle tissue is replaced by fibrosis, and collagen is deposited. These changes lead to severely disturbed esophageal motility, in particular in the smooth-muscle segment. In advanced disease manometry shows absent peristalsis, with only simultaneous pressure waves in the mid- and distal-esophageal body, and low LES pressure. This combination of abnormalities leads to increased gastroesophageal reflux and impaired esophageal clearance, in particular during the night. Consequently, esophagitis and its complications (ulcer, stenosis and Barrett's esophagus) are frequently observed in scleroderma.

Knowledge about the mechanisms underlying esophageal hypomotility associated with GERD is accumulating. In cats with experimentally induced esophagitis, inflammatory mediators, such as interleukin-6 and platelet activating factor, were found to reduce acetylcholine release from excitatory myenteric neurons.<sup>16</sup>

Similarly, the mucosa of human patients with reflux esophagitis produces significantly greater amounts of cytokines than that of healthy controls.<sup>17</sup> However, it is uncertain whether IEM associated with GERD is always the consequence of inflammation. It is also possible that it is a primary motor disorder leading to GERD.<sup>18</sup> Whereas, animal studies suggest that acute esophagitis-associated esophageal hypomotility can disappear after healing, studies in humans with chronic erosive GERD have shown that healing of esophagitis, either medically or surgically, is not associated with complete recovery of esophageal dysmotility.<sup>19,20</sup>

Finally, IEM can also be observed in patients without any evidence of GERD in present or past. The pathogenesis of this idiopathic disorder is almost unknown, although Kim and coworkers<sup>21</sup> have provided initial evidence that an imbalance between the excitatory and inhibitory innervation of the esophagus, reflected in the ratio between choline acetyltransferase (ChAT) and nitric oxide synthase (nNOS) expressed in the esophageal muscle wall, may be present in IEM patients.

## CLINICAL PRESENTATION

Esophageal symptoms in impaired esophageal peristalsis include dysphagia, odynophagia, heartburn and regurgitation. However, the correlation between the severity of the manometric findings and the symptoms is extremely poor. Even in patients with complete absence of peristalsis, as is often the case in scleroderma, symptoms may be absent. On the other end of the spectrum, one can find patients who complain of severe dysphagia but who have completely normal esophageal peristalsis, LES function, and bolus transit on barium studies.

## INVESTIGATIONS

Endoscopic examination of the esophagus is not a valuable tool to diagnose esophageal motility; endoscopy should always be carried out to exclude ulceration, stenosis, and neoplastic lesions before the patient is referred for evaluation of esophageal function. The good old barium esophagogram, still is a useful technique in the work-up of patients with a suspected esophageal motility disorder. It will detect obstructive lesions, esophageal dilation, and hiatus hernia at least as well as endoscopy. In addition, and most importantly, the barium esophagogram provides information about esophageal transit. For this purpose, not only barium suspension should be used, but swallowing a solid bolus, such as a marshmallow or a piece of bread, should be part of the examination. Scintigraphy does

not provide structural information but is the only technique that quantifies esophageal transit.

Manometry is often considered to be the gold standard, being able to detect subtle impairment of esophageal peristalsis. The most characteristic findings in scleroderma, low-amplitude simultaneous waves, can also be observed in other connective tissue diseases and in diabetes, amyloidosis, myxedema, multiple sclerosis, chronic idiopathic intestinal pseudoobstruction, and in severe end-stage GERD without scleroderma.

Whether conventional or high-resolution manometry is used, care must be taken to avoid circumstances that can lead to a spurious diagnosis of IEM. Examples of these are the use of drugs that inhibit esophageal contractions (anticholinergic agents and calcium channel blockers), failure to have an appropriate time interval between swallows, and inclusion of dry swallows. Additionally, depending on the examination position, the appropriate normal values must be applied because contractile vigor decreases on moving from the supine to the upright position.<sup>22</sup>

The combination of esophageal manometry and intraluminal impedance measurement allows assessment of the functional impact of ineffective esophageal contractions. In a study of 350 patients, it was found that one-third of patients with a manometric diagnosis of IEM had 'effective' transit for both liquid and viscous swallows.<sup>9</sup> Similar findings were reported by others, suggesting that the definition of weak peristalsis should include functional correlates.<sup>4,23</sup> High-resolution manometry, ideally combined with fluoroscopy or impedance, clarifies the relationship between dysmotility and bolus retention.<sup>4,24-26</sup> The introduction of solid swallows or a test meal to manometric studies may further increase sensitivity to dysfunction associated with symptoms in 'functional' dysphagia<sup>25,26</sup> and mucosal disease in GERD.<sup>27</sup>

## TREATMENT

Specific treatment is clearly desirable for patients with evidence of symptoms related to hypotensive dysmotility or reflux; however, the options are limited because there is no pharmacologic intervention that reliably restores smooth-muscle contractility and esophageal function. Thus, dietary and lifestyle advice together with effective control of acid reflux, if present, are the mainstays of clinical management.

### Dietary and lifestyle management

A 'common sense' approach can reduce the risk of symptomatic bolus retention. Patients should favor

liquid and semi-solid nutrition over solids, consume meals in the upright position, chew well and take plenty of fluids as these measures all promote esophageal clearance.<sup>28</sup> Indeed, it appears that the 'pharyngeal pump' together with gravity and hydrostatic forces can move not only liquids but also most solid food through the esophagus without the need for active esophageal contraction.<sup>28,29</sup> Many experts also recommend liberal use of carbonated beverages, because this may prevent as well as resolve bolus retention.<sup>30,31</sup>

### **Treatment of gastroesophageal reflux disease associated with hypotensive dysmotility**

Patients with hypotensive motility with weak lower esophageal sphincter function often experience severe symptoms and complications of GERD because poor clearance leads to prolonged acid exposure, particularly at night.<sup>15</sup> These problems are marked in patients with systemic sclerosis in whom the combination of poor motility and poor salivation impacts on both volume and chemical (i.e. acid) clearance.<sup>32</sup> Dietary and lifestyle measures may be helpful, although these are rarely sufficient in severe GERD. A systematic review identified several such interventions that reduce esophageal acid exposure,<sup>33</sup> some of which may be of particular benefit in patients with hypotensive dysmotility. These included (i) weight loss, (ii) keeping the upper body in an elevated position after a meal, (iii) lying down in the right lateral position, (iv) not smoking, (v) not consuming alcohol, (vi) reduction of meal size, and (vii) reduction in calorie load. Reduction in fat intake may be of additional value as this has high caloric density and also appears to sensitize the esophagus to acid reflux events.<sup>34</sup> In addition, chewing gum for half an hour after meals may be helpful,<sup>35</sup> as this stimulates salivation and swallowing, improving both volume and chemical clearance.

High-dose acid suppression taken twice a day is often required to suppress gastric acid, heal esophagitis and provide effective symptom relief in patients with severe hypotensive disease.<sup>36</sup> Some patients benefit also from alginate preparations taken after the meal that suppress both acid and non-acid reflux events by forming a viscous layer over the gastric contents.<sup>37</sup> The addition of ranitidine to suppress basal, nocturnal acid secretion appears to be helpful in individual patients but was not effective in a randomized controlled trial in 14 patients with systemic sclerosis.<sup>38</sup>

### **Prokinetics**

*Procholinergic agents* Medications that increase the concentration of acetylcholine in the synaptic cleft or

directly stimulate muscarinic receptors promote smooth-muscle contractility. Bethanechol, a direct-acting muscarinic receptor agonist, has been shown in healthy volunteers and patients with hypotensive esophageal dysmotility to increase peristaltic amplitude in the distal-esophagus.<sup>39</sup> Using combined multichannel intraluminal impedance-manometry in seven patients with severe IEM, Agrawal and coworkers<sup>39</sup> demonstrated that a single oral dose of 50 mg bethanechol increased both contractile pressure and bolus clearance. Similar effects on contractile pressure were reported by Blonski and coworkers<sup>40</sup> for a range of oral procholinergic agents, including bethanechol (25 mg), pyridostigmine (60 mg), and buspirone (20 mg), with pyridostigmine also promoting bolus transport. No trials demonstrating clinical efficacy have been published. Nevertheless, some experts report benefit of these medications in individual patients, although side-effects such as excessive salivation and diarrhea may limit use.

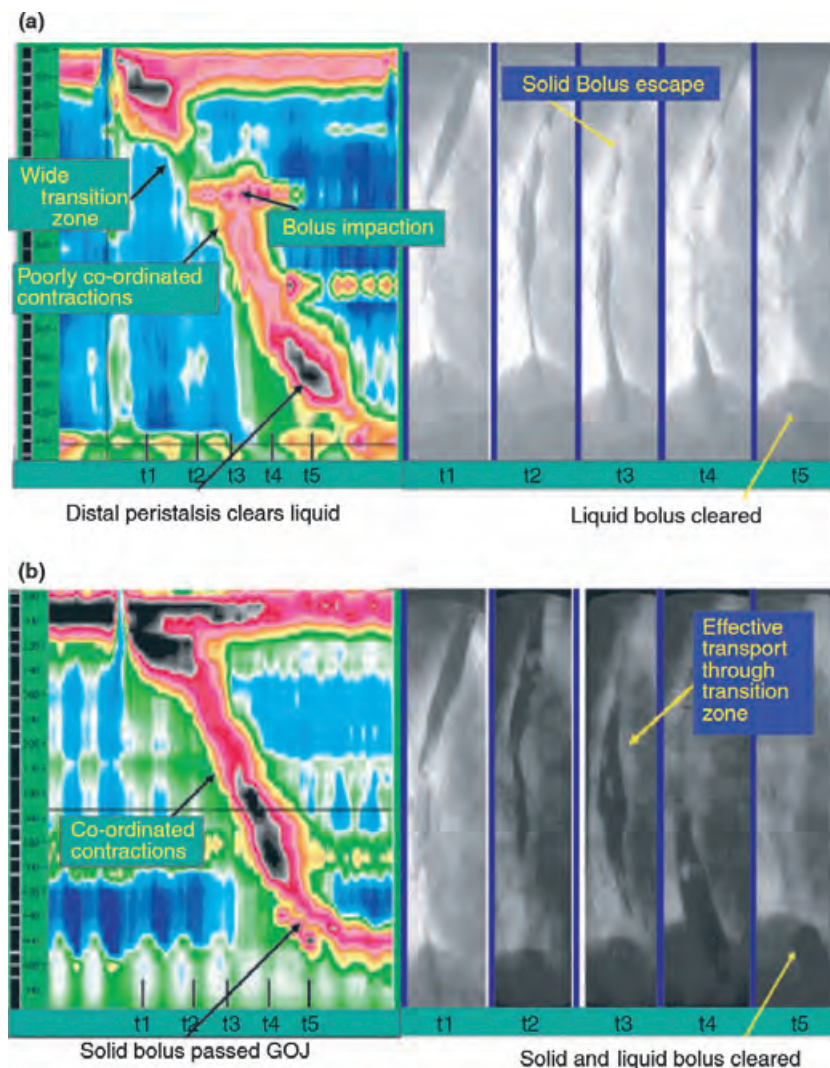
*Dopamine antagonists* Domperidone is a D<sub>2</sub> receptor antagonist that promotes gastrointestinal motility by antagonizing the inhibitory effects of dopamine on postsynaptic cholinergic neurons in the myenteric plexus.<sup>41</sup> Metoclopramide augments this peripheral effect with procholinergic properties and also has central anti-emetic actions at the chemoreceptor trigger zone.<sup>42</sup> These medications increase LES pressure, accelerate gastric emptying and improve symptoms in patients with GERD and also diabetic gastroparesis.<sup>43,44</sup> Effects on esophageal peristalsis and clearance are less well established. No effect of 20 mg domperidone on esophageal emptying was found on scintigraphy in 12 patients with diabetic autonomic neuropathy and esophageal dysfunction.<sup>45</sup> In contrast, a significant improvement in clearance was reported after administration of 10 mg intravenous metoclopramide in 14 patients with systemic sclerosis.<sup>46</sup>

*Motilin agonists* Erythromycin and other macrolide antibiotics have pronounced prokinetic side-effects that are utilized by physicians treating patients with severe gastrointestinal dysmotility such as gastroparesis and pseudo-obstruction.<sup>47</sup> This effect is mediated by motilin receptors that play a key role in the initiation of phase III migrating motor complex (MMC), interdigestive 'housekeeping' contractions that sweep the stomach, and bowel clear of undigested material and bacterial overgrowth.<sup>47</sup> Chrysos and coworkers<sup>48</sup> showed that intravenous erythromycin (200 mg i.v. bolus) increased contractile vigor and LES pressure in 15 GERD patients, and in a 2-week clinical study

Chang and coworkers<sup>49</sup> reported that erythromycin (250 mg tid) significantly shortened esophageal and gastric transit and improved glycemic control in diabetic patients. Although these findings are impressive, the clinical use of erythromycin is limited by tachyphylaxis and side-effects including dyspepsia and diarrhea. New motilin agonists that may be better tolerated are in development. However, one recent example, ABT-229, had no effect on LES function, esophageal motility, and reflux, in GERD patients.<sup>50</sup>

**Serotonin agonists** Cisapride and mosapride are prokinetic agents with mixed 5-HT<sub>4</sub> agonist/5-HT<sub>3</sub> antagonist action. Tegaserod, prucalopride, and other selective 5HT<sub>4</sub> agonists have similar actions.<sup>42</sup> Serotonin is released from enterochromaffin cells on mechanical stimulation and 5-HT<sub>4</sub> receptors facilitate

acetylcholine release in the myenteric plexus that triggers peristaltic contraction and clearance.<sup>51</sup> Thus, in contrast to muscarinic antagonists and motilin agonists, 5-HT<sub>4</sub> agonists promote normal gastrointestinal transit rather than inducing powerful but unphysiological contractions. These agents have prokinetic effects throughout the gastrointestinal tract and proven clinical efficacy in various conditions characterized by slow-transit, including GERD, diabetic gastroparesis and constipation.<sup>52</sup> Studies have demonstrated that cisapride and mosapride increase LES pressure, promote esophageal clearance, and reduce acid exposure in health and GERD patients.<sup>53,54</sup> However, the mechanism of this action was not evident on conventional motility studies.<sup>53-55</sup> Soon after the introduction of high-resolution manometry with esophageal pressure topography Staiano and



**Figure 2** Concurrent fluoroscopy and high-resolution manometry (HRM) reveals the functional importance of co-ordination between the proximal and mid-distal esophageal contractions for solid-bolus transport and the prokinetic effects of the 5-HT<sub>4</sub> agonist tegaserod. (A) Patient no. 6: placebo treatment. HRM shows a break in the contractile front (>3 cm) at the proximal transition zone, the peristaltic contraction is otherwise preserved. Concurrent fluoroscopy reveals solid-bolus escape at the level of the proximal transition zone (note the corresponding pressure rise at the level of bolus impaction). In contrast, the liquid barium ingested with the marshmallow was propelled into the distal-esophagus and most was transported into the stomach. (B) Patient no. 6: tegaserod treatment. The pressure trough at the proximal transition zone is less pronounced on the HRM plot, the peristaltic contraction in the proximal esophagus is well co-ordinated with the mid- and distal-esophagus. Concurrent fluoroscopy reveals effective solid and liquid bolus transport (note the pressure rise as the bolus passes through the gastro-esophageal junction into the stomach). Adapted with permission from Fox *et al.* *Aliment Pharmacol Ther* 2006; 24: 1017–1027.

Clouse<sup>56</sup> observed that cisapride enhanced contraction in the proximal smooth-muscle segment of the esophageal body. The functional significance of this effect was confirmed by combined HRM-videofluoroscopy that showed tegaserod improved co-ordination between contractile segments, leading to more effective solid-bolus transport (Fig. 2).<sup>57</sup> Cisapride and tegaserod have been withdrawn due to rare, but occasionally life-threatening, side-effects; however, new 5-HT<sub>4</sub> agonists are in the pipeline or are in the market approved for other indications.<sup>52</sup> Clinical trials in GERD are in progress and, hopefully, studies in symptomatic, hypotensive esophageal motility will follow.

### Surgery

In patients with severe GERD, impaired peristalsis, impaired esophageal clearance, and dysphagia are common. The dysphagia can be not only due to the hypotensive dysmotility<sup>3</sup>, but also to mechanical outflow obstruction at the esophagogastric junction in the presence of hiatus hernia.<sup>58</sup> In some cases anti-reflux surgery may not only improve reflux symptoms but also reduce dysphagia.<sup>20,59,60</sup> This

may be due to improvement of esophageal motility and visceral hypersensitivity with normalization of acid exposure or due to reduction of the hiatus hernia. However, the literature on the effect of fundoplication on esophageal motility and the relationship between preoperative motility and outcome of surgery should be interpreted with caution. Flaws in the design of these studies and manometric techniques employed should be taken into account. Some of these studies concluded that hypotensive dysmotility is not a contra-indication to surgical management of GERD, many experts in the field hold the opinion that fundoplication should not be carried out in patients with severe IEM.

### AUTHOR CONTRIBUTIONS

AS and MF performed the literature search underlying this article, analyzed the data and wrote the article.

### CONFLICT OF INTERESTS

The authors have no competing interests.

### REFERENCES

- Leite LP, Johnston BT, Barrett J, Castell JA, Castell DO. Ineffective esophageal motility (IEM): the primary finding in patients with nonspecific esophageal motility disorder. *Dig Dis Sci* 1997; **42**: 1859–65.
- Spechler SJ, Castell DO. Classification of oesophageal motility abnormalities. *Gut* 2001; **49**: 145–51.
- Kahrilas PJ, Dodds WJ, Hogan WJ. Effect of peristaltic dysfunction on esophageal volume clearance. *Gastroenterology* 1988; **94**: 73–80.
- Roman S, Lin Z, Kwiatek MA, Pandolfino JE, Kahrilas PJ. Weak peristalsis in esophageal pressure topography: classification and association with Dysphagia. *Am J Gastroenterol* 2011; **106**: 349–56.
- Fox M, Bredenoord AJ. High resolution manometry: moving from research into clinical practice. *Gut* 2008; **57**: 405–23.
- Richter JE, Wu WC, Johns DN *et al.* Esophageal manometry in 95 healthy adult volunteers. Variability of pressures with age and frequency of "abnormal" contractions. *Dig Dis Sci* 1987; **32**: 583–92.
- Ghosh SK, Pandolfino JE, Zhang Q, Jarosz A, Shah N, Kahrilas PJ. Quantifying esophageal peristalsis with high-resolution manometry: a study of 75 asymptomatic volunteers. *Am J Physiol Gastrointest Liver Physiol* 2006; **290**: G988–97.
- Vega KJ, Langford-Legg T, Jamal MM. Ethnic variation in lower oesophageal sphincter pressure and length. *Aliment Pharmacol Ther* 2008; **28**: 655–9.
- Tutuian R, Castell DO. Combined multichannel intraluminal impedance and manometry clarifies esophageal function abnormalities: study in 350 patients. *Am J Gastroenterol* 2004; **99**: 1011–9.
- Conchillo JM, Nguyen NQ, Samsom M, Holloway RH, Smout AJ. Multi-channel intraluminal impedance monitoring in the evaluation of patients with non-obstructive Dysphagia. *Am J Gastroenterol* 2005; **100**: 2624–32.
- Dekel R, Pearson T, Wendel C, De Garmo P, Fennerty MB, Fass R. Assessment of oesophageal motor function in patients with dysphagia or chest pain – the Clinical Outcomes Research Initiative experience. *Aliment Pharmacol Ther* 2003; **18**: 1083–9.
- Diener U, Patti MG, Molena D, Fisichella PM, Way LW. Esophageal dysmotility and gastroesophageal reflux disease. *J Gastrointest Surg* 2001; **5**: 260–5.
- Lee J, Anggiansah A, Anggiansah R, Young A, Wong T, Fox M. Effects of age on the gastroesophageal junction, esophageal motility, and reflux disease. *Clin Gastroenterol Hepatol* 2007; **5**: 1392–8.
- Fouad YM, Katz PO, Hatlebakk JG, Castell DO. Ineffective esophageal motility: the most common motility abnormality in patients with GERD-associated respiratory symptoms. *Am J Gastroenterol* 1999; **94**: 1464–7.
- Sallam H, McNearney TA, Chen JD. Systematic review: pathophysiology and management of gastrointestinal dysmotility in systemic sclerosis (scleroderma). *Aliment Pharmacol Ther* 2006; **23**: 691–712.
- Cheng L, Cao W, Fiocchi C, Behar J, Biancani P, Harnett KM. Platelet-activating factor and prostaglandin E2 impair esophageal ACh release in experimental esophagitis. *Am*

- J Physiol Gastrointest Liver Physiol* 2005; **289**: G418–28.
- 17 Rieder F, Cheng L, Harnett KM *et al.* Gastroesophageal reflux disease-associated esophagitis induces endogenous cytokine production leading to motor abnormalities. *Gastroenterology* 2007; **132**: 154–65.
  - 18 Fox M, Forgacs I. Gastro-oesophageal reflux disease. *BMJ* 2006; **332**: 88–93.
  - 19 Timmer R, Breumelhof R, Nadorp JH, Smout AJ. Oesophageal motility and gastro-oesophageal reflux before and after healing of reflux oesophagitis. A study using 24 hour ambulatory pH and pressure monitoring. *Gut* 1994; **35**: 1519–22.
  - 20 Fibbe C, Layer P, Keller J, Strate U, Emmermann A, Zornig C. Esophageal motility in reflux disease before and after fundoplication: a prospective, randomized, clinical, and manometric study. *Gastroenterology* 2001; **121**: 5–14.
  - 21 Kim HS, Park H, Lim JH *et al.* Morphometric evaluation of oesophageal wall in patients with nutcracker oesophagus and ineffective oesophageal motility. *Neurogastroenterol Motil* 2008; **20**: 869–76.
  - 22 Sweis R, Anggiansah A, Wong T, Kaufman E, Obrecht S, Fox M. Normative values and inter-observer agreement for liquid and solid bolus swallows in upright and supine positions as assessed by esophageal high-resolution manometry. *Neurogastroenterol Motil* 2011; **23**: 509–e198.
  - 23 Nguyen NQ, Tippet M, Smout AJ, Holloway RH. Relationship between pressure wave amplitude and esophageal bolus clearance assessed by combined manometry and multi-channel intraluminal impedance measurement. *Am J Gastroenterol* 2006; **101**: 2476–84.
  - 24 Bulsiewicz WJ, Kahrilas PJ, Kwiatek MA, Ghosh SK, Meek A, Pandolfino JE. Esophageal pressure topography criteria indicative of incomplete bolus clearance: a study using high-resolution impedance manometry. *Am J Gastroenterol* 2009; **104**: 2721–8.
  - 25 Fox M, Hebbard G, Janiak P *et al.* High-resolution manometry predicts the success of oesophageal bolus transport and identifies clinically important abnormalities not detected by conventional manometry. *Neurogastroenterol Motil* 2004; **16**: 533–42.
  - 26 Sweis R, Anggiansah A, Wong T, Fox M. Inclusion of solid swallows and a test meal increase the clinical utility of High Resolution Manometry in patients with dysphagia. *Gastroenterology* 2010; **138**: S 600 (T1889).
  - 27 Daum C, Sweis R, Kaufman E *et al.* Failure to respond to physiologic challenge characterizes esophageal motility in erosive gastro-oesophageal reflux disease. *Neurogastroenterol Motil* 2011; **23**: 517–e200.
  - 28 Poudereux P, Shi G, Tatum RP, Kahrilas PJ. Esophageal solid bolus transit: studies using concurrent videofluoroscopy and manometry. *Am J Gastroenterol* 1999; **94**: 1457–63.
  - 29 Simren M, Silny J, Holloway R, Tack J, Janssens J, Sifrim D. Relevance of ineffective oesophageal motility during oesophageal acid clearance. *Gut* 2003; **52**: 784–90.
  - 30 Holdaway A, Davis M. Palliation in cancer of the oesophagus – what passes down an oesophageal stent? *J Hum Nutr Dietet* 2003; **16**: 365–70.
  - 31 Mohammed SH, Hegedus V. Dislodgement of impacted oesophageal foreign bodies with carbonated beverages. *Clin Radiol* 1986; **37**: 589–92.
  - 32 Sjogren RW. Gastrointestinal motility disorders in scleroderma. *Arthritis Rheum* 1994; **37**: 1265–82.
  - 33 Kaltenbach T, Crockett S, Gerson LB. Are lifestyle measures effective in patients with gastroesophageal reflux disease? An evidence-based approach. *Arch Intern Med* 2006; **166**: 965–71.
  - 34 Fox M, Barr C, Nolan S, Lomer M, Anggiansah A, Wong T. The effects of dietary fat and calorie density on esophageal acid exposure and reflux symptoms. *Clin Gastroenterol Hepatol* 2007; **5**: 439–44.
  - 35 Moazzez R, Bartlett D, Anggiansah A. The effect of chewing sugar-free gum on gastro-oesophageal reflux. *J Dent Res* 2005; **84**: 1062–5.
  - 36 Hendel L, Hage E, Hendel J, Stentoft P. Omeprazole in the long-term treatment of severe gastro-oesophageal reflux disease in patients with systemic sclerosis. *Aliment Pharmacol Ther* 1992; **6**: 565–77.
  - 37 Buts JP, Barudi C, Otte JB. Double-blind controlled study on the efficacy of sodium alginate (Gaviscon) in reducing gastroesophageal reflux assessed by 24 h continuous pH monitoring in infants and children. *Eur J Pediatr* 1987; **146**: 156–8.
  - 38 Janiak P, Thumshirn M, Menne D *et al.* Clinical trial: the effects of adding ranitidine at night to twice daily omeprazole therapy on nocturnal acid breakthrough and acid reflux in patients with systemic sclerosis – a randomized controlled, cross-over trial. *Aliment Pharmacol Ther* 2007; **26**: 1259–65.
  - 39 Agrawal A, Hila A, Tutuian R, Mainie I, Castell DO. Bethanechol improves smooth muscle function in patients with severe ineffective esophageal motility. *J Clin Gastroenterol* 2007; **41**: 366–70.
  - 40 Blonski W, Vela MF, Freeman J, Sharma N, Castell DO. The effect of oral buspirone, pyridostigmine, and bethanechol on esophageal function evaluated with combined multichannel esophageal impedance-manometry in healthy volunteers. *J Clin Gastroenterol* 2009; **43**: 253–60.
  - 41 Takahashi T, Kurosawa S, Wiley JW, Owyang C. Mechanism for the gastrokinetic action of domperidone. In vitro studies in guinea pigs. *Gastroenterology* 1991; **101**: 703–10.
  - 42 Tonini M, Candura SM, Messori E, Rizzi CA. Therapeutic potential of drugs with mixed 5-HT4 agonist/5-HT3 antagonist action in the control of emesis. *Pharmacol Res* 1995; **31**: 257–60.
  - 43 Maddern GJ, Kiroff GK, Leppard PI, Jamieson GG. Domperidone, metoclopramide, and placebo. All give symptomatic improvement in gastroesophageal reflux. *J Clin Gastroenterol* 1986; **8**: 135–40.
  - 44 Sturm A, Holtmann G, Goebell H, Gerken G. Prokinetics in patients with gastroparesis: a systematic analysis. *Digestion* 1999; **60**: 422–7.
  - 45 Maddern GJ, Horowitz M, Jamieson GG. The effect of domperidone on oesophageal emptying in diabetic autonomic neuropathy. *Br J Clin Pharmacol* 1985; **19**: 441–4.
  - 46 Drane WE, Karvelis K, Johnson DA, Curran JJ, Silverman ED. Scintigraphic detection of metoclopramide esophageal stimulation in progressive systemic sclerosis. *J Nucl Med* 1987; **28**: 810–5.
  - 47 Quigley EM. Gastric and small intestinal motility in health and disease. *Gastroenterol Clin North Am* 1996; **25**: 113–45.
  - 48 Chrysos E, Tzavaras G, Epanomeritakis E *et al.* Erythromycin enhances oesophageal motility in patients with

- gastro-oesophageal reflux. *ANZ J Surg* 2001; **71**: 98–102.
- 49 Chang CT, Shiau YC, Lin CC, Li TC, Lee CC, Kao CH. Improvement of esophageal and gastric motility after 2-week treatment of oral erythromycin in patients with non-insulin-dependent diabetes mellitus. *J Diabetes Complications* 2003; **17**: 141–4.
- 50 Van Herwaarden MA, Samsom M, Van Nispen CH, Verlinden M, Smout AJ. The effect of motilin agonist ABT-229 on gastro-oesophageal reflux, oesophageal motility and lower oesophageal sphincter characteristics in GERD patients. *Aliment Pharmacol Ther* 2000; **14**: 453–62.
- 51 Gershon MD. Review article: serotonin receptors and transporters – roles in normal and abnormal gastrointestinal motility. *Aliment Pharmacol Ther* 2004; **20**(Suppl. 7): 3–14.
- 52 Sanger GJ. Translating 5-HT receptor pharmacology. *Neurogastroenterol Motil* 2009; **21**: 1235–8.
- 53 Smout AJ, Bogaard JW, Grade AC, ten Thijs OJ, Akkermans LM, Wittebol P. Effects of cisapride, a new gastrointestinal prokinetic substance, on interdigestive and postprandial motor activity of the distal oesophagus in man. *Gut* 1985; **26**: 246–51.
- 54 Ruth M, Finizia C, Cange L, Lundell L. The effect of mosapride on oesophageal motor function and acid reflux in patients with gastro-oesophageal reflux disease. *Eur J Gastroenterol Hepatol* 2003; **15**: 1115–21.
- 55 Koshino K, Adachi K, Furuta K *et al.* Effects of mosapride on esophageal functions and gastroesophageal reflux. *J Gastroenterol Hepatol* 2010; **25**: 1066–71.
- 56 Staiano A, Clouse RE. The effects of cisapride on the topography of oesophageal peristalsis. *Aliment Pharmacol Ther* 1996; **10**: 875–82.
- 57 Fox M, Menne D, Stutz B, Fried M, Schwizer W. The effects of tegaserod on oesophageal function and bolus transport in healthy volunteers: studies using concurrent high-resolution manometry and videofluoroscopy. *Aliment Pharmacol Ther* 2006; **24**: 1017–27.
- 58 Pandolfino JE, Kwiatek MA, Ho K, Scherer JR, Kahrilas PJ. Unique features of esophagogastric junction pressure topography in hiatus hernia patients with dysphagia. *Surgery* 2010; **147**: 57–64.
- 59 Herbella FA, Tedesco P, Nipomnick I, Fisichella PM, Patti MG. Effect of partial and total laparoscopic fundoplication on esophageal body motility. *Surg Endosc* 2007; **21**: 285–8.
- 60 Munitiz V, Ortiz A, Martinez de Haro LF, Molina J, Parrilla P. Ineffective oesophageal motility does not affect the clinical outcome of open Nissen fundoplication. *Br J Surg* 2004; **91**: 1010–4.